doi: 10.17116/neiro201579360-65

Growing Teratoma Syndrome in a Patient with Intracranial Germ Cell Tumor

O.G. ZHELUDKOVA*[1], L.V. SHISHKINA[2], A.N. KONOVALOV[2], M.V. RYZHOVA[2], A.N. KISLYAKOV[3], S.S. OZEROV[4], YU.YU. TRUNIN[2], N.A. MAZERKINA[2], O.V. KLIMCHUK[5], E.M. TARASOVA[6]

[1]Research Center of Radiology and Nuclear Medicine, Ministry of Health of the Russian Federation, Moscow, Russia; [2]Burdenko Neurosurgical Institute, Moscow, Russia; [3]Morozov children hospital, Moscow, Russia; [4]Federal Scientific and Clinical Center for Pediatric Hematology, Oncology and Immunology, Ministry of Health of the Russian Federation, Moscow, Russia; [5]Scientific and Practical Center for Medical Aid to Children with Craniofacial Malformations and Nervous System Disorders, Moscow, Russia; [6]Russian Children's Clinical Hospital, Moscow, Russia

A six-year-old patient with non-germinomatous germ cell tumor of the chiasmatic-sellar area developed polyuria and polydipsia as the first symptoms of the disease. Then there were signs of precocious puberty and vision impairment. MRI examination revealed a chiasmatic sellar tumor and occlusive hydrocephalus. Tumor marker levels in blood serum were elevated. The alpha-fetoprotein level was increased 5-fold; human chorionic gonadotropin 20-fold. These levels increased over time. The patient received 2 cycles of PEI multiagent chemotherapy (Ifosfamide 1.5 g/m^2, Cisplatin 20 mg/m^2, and Etoposide 100 mg/m^2) during 5 days and 1 cycle of second-line multiagent chemotherapy (Cisplatin 100 mg/m^2 for 1 day and Endoxan 1500 mg/m^2 for 2 days). Despite the decrease in tumor marker levels to normal values, the patient's vision still deteriorated. MRI examination revealed that tumor size increased and its structure changed. Total tumor resection led to vision improvement and regression of intracranial hypertension. Histological analysis of tumor tissue only revealed a mature teratoma. This phenomenon, known as growing teratoma syndrome, is very rare among patients with intracranial non-germinomatous germ cell tumors.

Keywords: *intracranial germ cell tumor, multiagent chemotherapy, growing teratoma syndrome.*

Primary intracranial germ cell tumors (GCTs) are rare types of tumors and are usually found in children and adolescents than in adult patients, accounting for 0.5—1% in the East and 2—5% in Japan [1—3]. The incidence rate of teratomas, including malignant forms, is 0.4% of all brain tumors [4]. Intracranial GCTs most frequently localize in the pineal and chiasmatic-sellar areas (neurohypophysis) [2, 3]. GCTs are divided into germinomas and non-germinomatous germ cell tumors (NGGCTs). The non-germinomatous germ cell tumors include mature and immature teratoma, teratoma with malignant transformation, embryonal carcinoma, yolk sac tumor, and choriocarcinoma.

Diagnosis of GCTs includes contrasted and uncontrasted magnetic resonance imaging (MRI) and measurement of tumor markers: alpha-fetoprotein (alpha-FP) and human chorionic gonadotropin (hCG) levels in blood and cerebrospinal fluid. Multiagent chemotherapy incorporating Cisplatin is most efficient in treatment of malignant intracranial GCTs. Combination therapies with Cisplatin and Etoposide have yielded favorable immediate results (80%) [5, 6].

The growing teratoma syndrome was first described by C. Logothetis et al. [7] in 1982 for extracranial GCTs. The literature mostly describes retroperitoneal GCTs and intracranial NGGCTs only in a few cases [7—10]. Intracranial growing teratoma syndrome (iGTS) is known to be a rare condition; its frequency is about 6.5% of all intracranial GCTs [9, 10]. The diagnosis of the growing teratoma syndrome is based on three criteria: the normalization of initially high alpha-FP and/or hCG levels, increasing the size of the tumor during or after chemotherapy, and histologically confirmed mature teratoma in patients with NGGCTs [5—7].

The growing teratoma syndrome is reported to develop mostly in patients with mixed GCTs and immature teratoma [8—10]. Based on increasing the tumor's size at multiagent chemotherapy physicians primarily suspect continued tumor growth.

We present a case of treatment of 6-year-old boy with intracranial growing teratoma syndrome in the chiasmatic-sellar area (CSA).

Clinical case

A 6-year-old boy presented with polydipsia and polyuria. Diabetes insipidus was diagnosed. MRI revealed thickened pituitary stalk. A year later there were signs of precocious puberty (penis growth, the emergence of the sexual body hair, changes in voice, and gynecomastia), vision impairment, and vomiting.

In the ophthalmic examination on both eyes (OU), visual acidity was significantly deteriorated (Vis OD=0.3, OS — 0.1) and temporal hemianopia was detected. Neurological examination revealed symptoms of intracranial hypertension (vomiting, optic disk edema on fundus). Partial hypopituitarism (growth hormone deficiency, hypothyroidism, hypocorticism) was found at endocrinological examination in addition to precocious puberty and diabetes insipidus. Alpha-FP level in blood serum was elevated to 26.67 ng/ml (normal limits are up to 4.6 ng/ml), hCG level was elevated to 200.1 IU/ml (normal values are up to 9 IU/ml). Results of other

© Group of authors, 2015

*e-mail: clelud@mail.ru

biochemical parameters were within normal limits. From this period, the patient has received hydrocortisone (5—10 mg/day), desmopressin (0.05—0.1 mg per day depending on diuresis), and L-thyroxine (50 μg/day) continuously as replacement therapy.

MRI revealed a tumor in the CSA, which spread to the third ventricle and left foramen of Monro. Signs of occlusive hydrocephalus were found **(Fig. 1)**. Clinical and radiological presentation was indicative of GCTs. Spinal cord examination excluded tumor metastasis. Tumor cells in CSF from the lumbar region were not examined. The Mx staging was defined. Repeated examination of tumor markers in the blood before multiagent chemotherapy showed elevated alpha-FP levels 2-fold of the initial level (up to 55.86 ng/ml) and hCG level up to 405.34 IU/ml.

The patient received 2 cycles of PEI multiagent chemotherapy with an interval of 3 weeks as in SIOP GCT-96 protocol: Cisplatin 20 mg/m^2 (5 days), Etoposide 100 mg/m^2 (3 days), and Ifosfamide 1500 mg/m^2 (5 days). Tumor markers in serum were normalized after the second cycle of multiagent chemotherapy and were as follows: alpha-FP — 6.13 ng/ml and hCG — 0 IU/ml. Meanwhile, MRI after 2 cycles of multiagent chemotherapy showed an increase in the chiasmatic sellar tumor's size, cystic component dominated in the structure of the tumor. Brain metastases were absent **(Fig. 2)**.

In addition, the patient received 1 cycle of second-line multiagent chemotherapy: Cisplatin 100 mg/m^2 (1st day) + Endoxan 1500 mg/m^2 (1st and 2nd days). Repeated MRI after 2 weeks after multiagent chemotherapy revealed that the tumor continued growth in the CSA and the number of cysts in the tumor increased **(Fig. 3)**. Alpha-FP and hCG levels remained stable within the normal limits: 3.4 ng/ml and 0 IU/ml, respectively.

Visual acidity still deteriorated as shown by OU ophthalmic examination: Vis OD=0.1—0.15, OS — light perception.

Because of the increased sizes of the tumor despite chemotherapy causing progressive vision impairment, the patient was subjected to total resection of the chiasmatic sellar tumor at the Burdenko Neurosurgical Institute. During surgery, a tumor of a very thick consistency, which composed of light gray colored connective tissue and contained a large number of cysts of different sizes, was resected.

The results of histological and immunohistochemical studies revealed mature teratoma; immature and malignant elements were absent. Immunohistochemical study revealed that the tumor tissue was negative for alpha-FP and hCG **(Fig. 4)**.

In the first days after surgery all types of voluntary activity sharply decreased, paroxysmal extrapyramidal symptoms developed in the form of stereotyped movements in hands and hand tremor and disturbance of thermoregulation with febrile hyperthermia. Based on electroencephalography, epileptiform activity was not detected. Spontaneous activity began to grow starting from the 3—5th day: the patient began to sit in bed, walk with support, and communicate with others. Moderate motor deficit in the right extremities gradually grew over time. The symptoms of intracranial hypertension regressed completely after surgery.

Left outer subdural drain was placed because of hyperthermia, growth of right-sided hemiparesis and subdural fluid accumulation (more on the left). The therapy improved the patient's condition, level of activity increased, range of motion in the right extremities and the volume of speech began to rise. After 5 days, the outer subdural drain was removed.

Contrasted and uncontrasted brain MRI after the operation showed the absence of the tumor remnants in the CSA and the third ventricle, metastases in brain structures were not detected **(Fig. 5)**. Tumor cells in the cerebrospinal fluid on the 14th day after the surgery were not identified. Alpha-FP and hCG levels in serum were negative. Neuroophtalmologist reported visual improvement to 0.5 on the right and to 0.2 on the left eye.

The patient received radiation therapy on the brain as a prophylactic measure after 4 weeks after surgery in the total focal dose of 30 Gy.

The patient was on the follow-up for 37 months over-time. Currently, the boy is doing well, attends secondary school, attends extra classes of English, and goes swimming. Visual impairment still remains at 0.7 on the right and 0.04 on left. Right-sided homonymous hemianopsia and other neurological disorders are absent. Deficiency of pituitary hormones is compensated for by intake of L-thyroxine (75 μg/day), hydrocortisone (2.5—10 mg/day), and desmopressin (0.05—0.1 mg/day).

MRI over time shows a lack of the tumor and metastasis, alpha-FP and hCG levels remain negative so the patient has a risk of the tumor relapses **(Fig. 6)**.

Discussion

Teratomas constitute about 0.5% of all intracranial tumors. Ten-year survival of patients with mature and immature teratomas is 90 and 70%, respectively. Patients with malignant transformation of teratoma show worse survival of less than 50% [4, 6].

Reduction of alpha-FP and hCG tumor marker levels in the blood, a paradoxical increase in the size of the tumor at multiagent chemotherapy, and verified histological diagnosis of mature teratoma after resection of the tumor indicate the growing teratoma syndrome. Intracranial growing teratoma syndrome is very rare, the literature describes single cases.

The growing teratoma syndrome in our patient manifested after the second cycle of chemotherapy. The period from the detection of the tumor before the

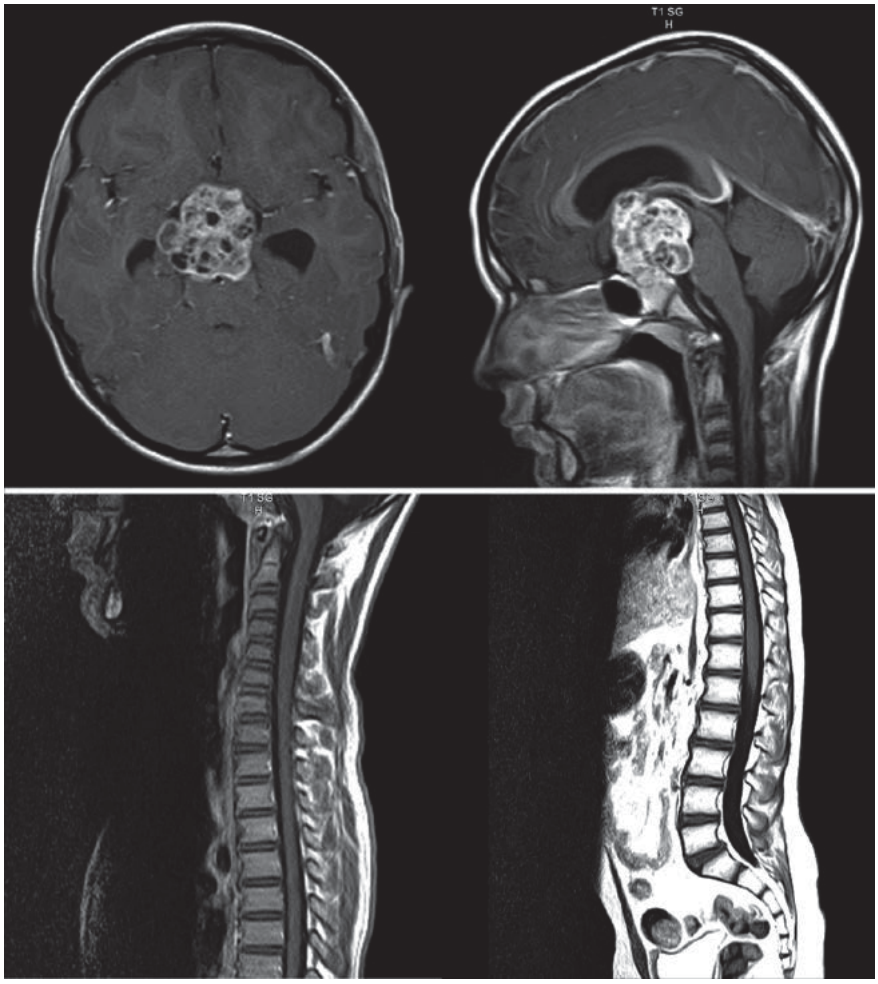

Fig. 1. **Contrasted MRI scans of brain and spinal cord before chemotherapy.**
Tumor in the chiasmatic-sellar area (CSA) extends to the third ventricle and left foramen of Monro; sings of occlusive hydrocephaly; absence of metastases into spinal cord.

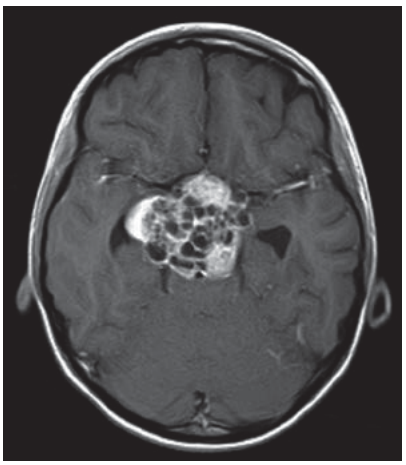

Fig. 2. **Contrasted MRI scans of brain after 2 cycles of chemotherapy.**
Increased sizes of the tumor in the CSA, cystic component dominates, metastases into spinal cord are absent.

diagnosis of growing teratoma syndrome took 3.6 months.

The etiology of the growing teratoma syndrome remains unknown. Chemotherapy plays a potentially important role in the etiology of this syndrome. The most quoted causes of this syndrome include three aspects:

1. Chemotherapy destroys only the cancer cells leaving mature benign elements.

2. Chemotherapy causes a change in the kinetics of cells and transformation of a malignant tumor into a benign mature teratoma.

3. The third hypothesis (W. Hong et al. [11]) suggests that malignant cells differentiate into benign under the influence of chemotherapy [9, 11].

Growing teratoma represents a mixed secreting GCT, which is sensitive to chemotherapy, and a nonsecreting mature teratoma, which continues to grow during chemotherapy.

Several factors may be predictive of the growing teratoma syndrome; these include increasing the size of

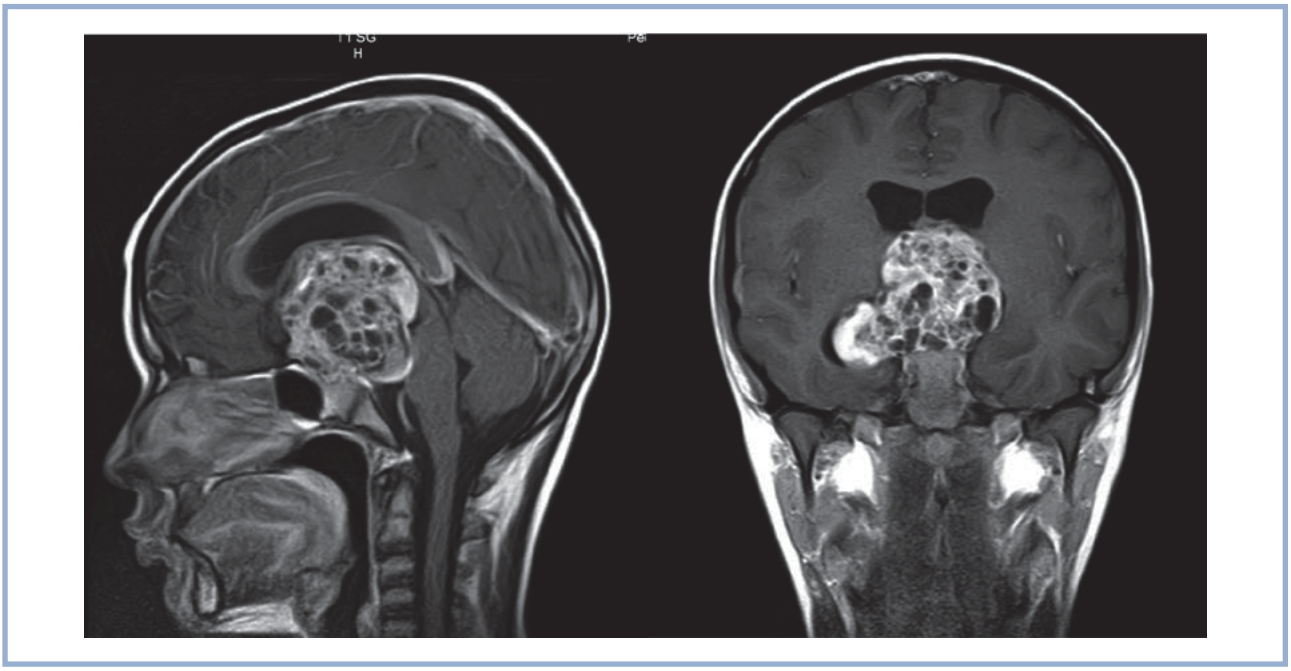

Fig. 3. **Contrasted MRI of brain after 3 cycles of chemotherapy.**
Continued growth of the chiasmatic-sellar tumor, the number of cysts in the tumor increased.

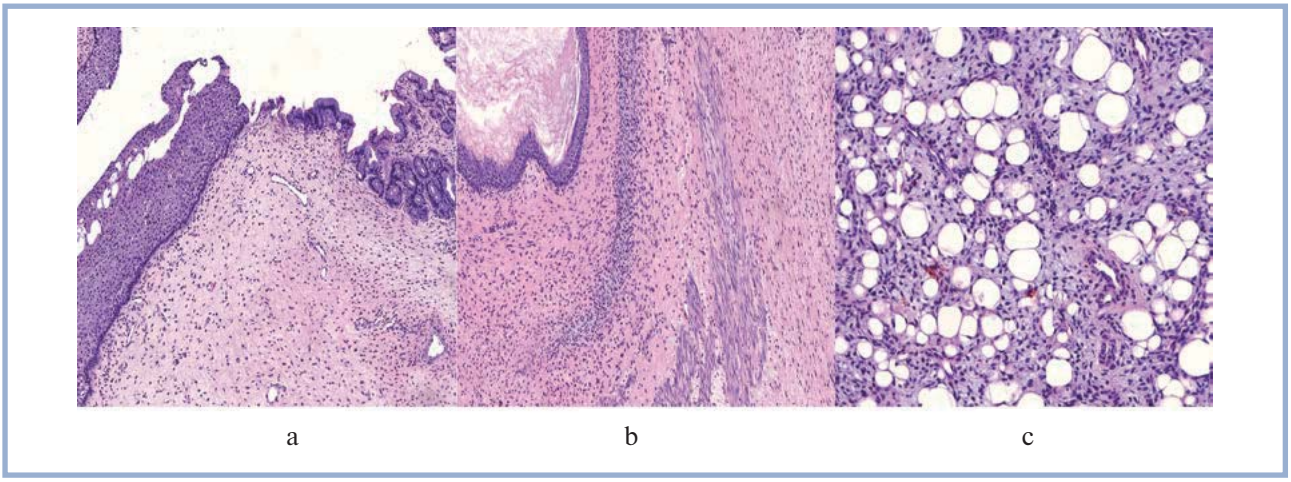

Fig. 4. **Mature teratoma.**
a — gland, connective tissue, multilayered epithelium; b — area resembling epidermoid cyst (epithelium and structureless material), Schwann cells, glial tissue; c — fat tissue. Hematoxylin and eosin stain. Magnification of 100.

the tumor at chemotherapy and normalization of tumor markers during therapy.

The therapy for intracranial growing teratoma should include surgery. Radiotherapy is not required after total resection of the tumor and when metastases are absent [8—10]. The presence of tumor remnants and/or metastases after partial resection has a poor prognosis, since a growing tumor, which is represented by a mature teratoma on histologic presentation, is insensitive to either radiation therapy or chemotherapy [9]. Early detection of the phenomenon of the growing teratoma syndrome and early resection of the tumor are crucial to cure the patient.

The good results of the therapy of growing teratoma syndrome rely on four factors: 1) knowledge of this phenomenon; 2) thorough diagnostic examination of patients with GCTs when the patient is subjected to chemotherapy; 3) early detection of the paradoxical response of the tumor to chemotherapy (increasing the size of the tumor and the normalization of tumor markers in the blood); 4) total resection of the tumor.

C. Kim et al. in his publication [9] showed that among nine patients with total resection of the growing teratoma only one patient relapsed with GCTs, the remaining eight patients are alive without recurrence (continued tumor growth).

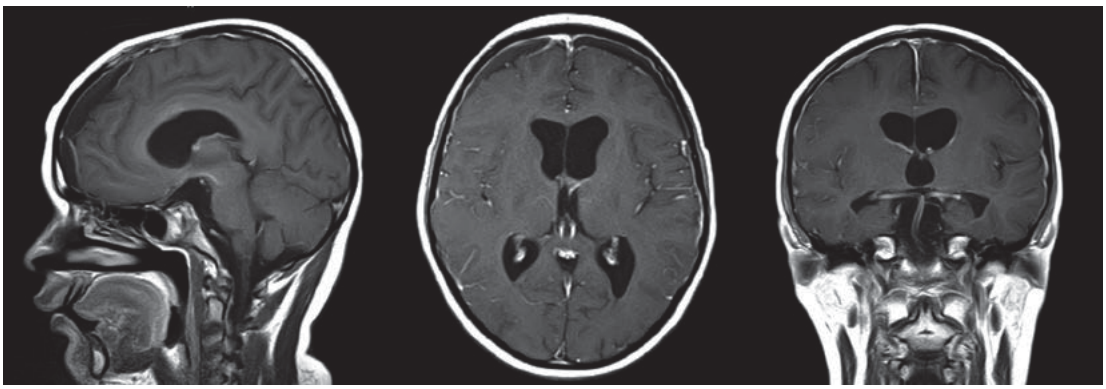

Fig. 5. **Contrasted MRI scans of brain after surgery: absence of the tumor remnants in CSA and the third ventricle.**

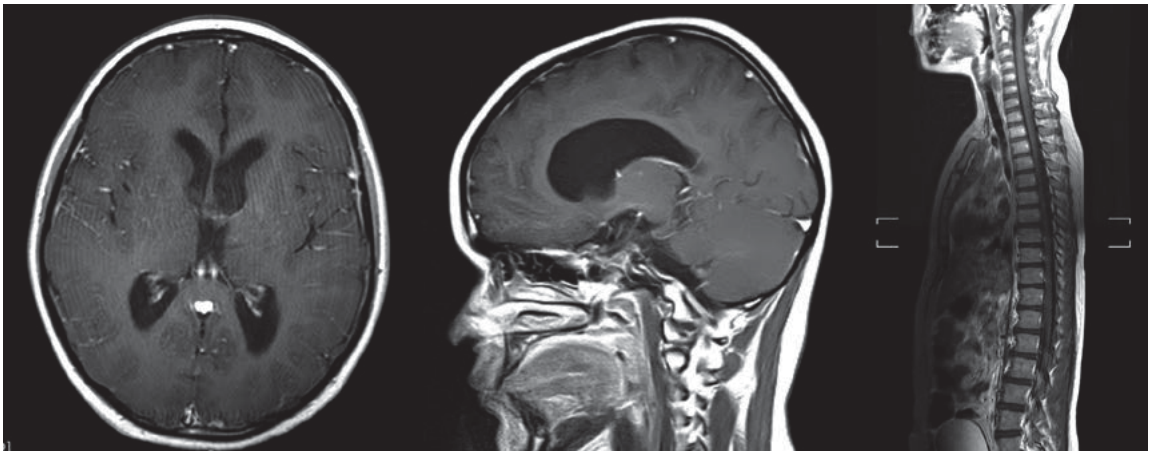

Fig. 6. **Contrasted MRI of brain and spinal cord (18 months after cancelling the therapy); absence of relapses (metastases).**

Thus, the prognosis of intracranial growing teratoma depends on the scope of surgical intervention.

Conclusions

Early identification of the growing intracranial teratoma during or after chemotherapy of non-germinomatous GCTs is based on the analysis of tomograms over time. Typical signs of intracranial growing teratoma are multicystic transformation and increasing the size of the tumor based on MRI data, and the normalization of tumor markers during chemotherapy. The curative method for the patient is total surgical resection of the tumor.

REFERENCES

1. Dearneley DP, A'Hearn RP, Whittaker S, Bloom HJG. Pineal and CNS germ cell tumors: Royal Marsden Hospital experience 1962—1987. *Int J Radiat Oncol Biol Phys.* 1990;18:773-781.
2. Friedman JA, Lynch JJ, Buckner JC, Scheithauer BW, Raffel C. Management of malignant pineal germ cell tumors with residual mature teratoma. *Neurosurgery.* 2001;48:518-523.
3. Hoffman HJ, Otsubo H, Hendrik EB, Humphreus RP, Drake JM, Becker LE, Greenberg M, Jenkin D. Intracranial germ cell tumors in children. *J Neurosurg.* 1991;74:545-551.
4. Sawamura Y, Kato T, Ikeda J, Murata J, Tada M, Shirato H. Teratomas of the central nervous system: treatment consideration based on 34 cases. *J Neurosurg.* 1998;89:728-737.
5. Kellie SJ, Boyce H, Dunkel IJ. Primary chemotherapy for intracranial nongerminomatous germ cell tumors: results of the second international CNS germ cell study group protocol. *J Clin Oncol.* 2004;22:846-853.
6. Matsutani M, Sano K, Takakura K, Fujimaki T, Nakamura O, Funata T, Seto T. Primary intracranial germ cell tumors: a clinical analysis of 153 histologically verified cases. *J Neurosurg.* 1997;86:446-455.
7. Logothetis CJ, Samuels ML, Trindade A, Jonson DE. The growing teratoma syndrome. *Cancer.* 1982;50:1629-1635.
8. Andre F, Fizazi K, Culine S. The growing teratoma syndrome: results of therapy and long-term follow-up of 33 patients. *Eur J Cancer.* 2000;36:1389-1394.
9. Kim CY, Choi JW, Lee JY, Kim SK, Wang KC, Park SH, Choe G, Ahn HS, Kim IH, Cho BK. Intracranial growing teratoma syndrome: clinical characteristics and treatment strategy. *J Neurooncol.* 2011;101:109-115.
10. Yagi K, Kageji T, Nagahiro S, Horiguchi H. Growing teratoma syndrome in a patient with a nongerminomatous germ cell tumors in the neurohypophysis. *Neurol Med Chir.* (Tokyo) 2004;44:33-37.
11. Hong WK, Wittes RE, Hajdu ST, Cvitcovic E, Whitmore WF, Golbey RB. The evolution of mature teratoma from malignant testicular tumors. *Cancer.* 1977;40:2987-2992.

Commentary

Research studies in neurooncology are relevant since they allow validation of efficient programs to cure CNS tumors.

Analysis of the case, which is rare in the practice, is of interest to the practitioner, as it shows the most effective treatment of the disease.

It is known that the prognosis of patients with germ cell tumors varies and depends primarily on the histological presentation of tumors, as well as on the response to chemoradiotherapy. Increased tumor size at multiagent chemotherapy primarily assumes continued tumor growth. Early detection of growing teratoma syndrome and early resection of the tumor are crucial to cure the patient.

The paper presents a rare case of intracranial growing teratoma in the chiasmatic-sellar area in a 6-year old child.

A thorough diagnostic examination of the patient with GCTs during chemotherapy showed continued tumor growth and multicystic transformation while the alpha-FP level normalized.

Total surgical resection of the tumor was found to be the curative method for the sick child.

The article presents the literature data showing that good results of growing teratoma syndrome treatment depend on the following factors: 1. Knowledge of this phenomenon. 2. Thorough examination during chemotherapy. 3. Early detection of the paradoxical response to chemotherapy (increasing the size of the tumor and the normalization of tumor markers in the blood). 4. The total resection of the tumor.

The article is of great interest to readers of this journal.

V.E. Popov (Moscow, Russia)