doi: 10.17116/neiro201579352-59

Correlating a fMRI-Identified Activation Pattern of Language Areas with the Tumor Localization and Functional Asymmetry Profile in Patients with Intracerebral Tumors

S.B. BUKLINA*, A.I. BATALOV, L.M. FADEEVA, A.S. SMIRNOV, S.A. GORYAYNOV, V.YU. ZHUKOV, A.A. PODDUBSKAYA, A.A. OGURTSOVA, A.S. KULIKOV, A.P. CHUMAKOVA, I.N. PRONIN, V.N. KORNIENKO, A.A. POTAPOV

Burdenko Neurosurgical Institute, Moscow, Russia

The aim of the study was to determine the dependence of activation patterns of language areas identified by functional magnetic resonance imaging (fMRI) on the functional asymmetry profile and tumor localization. **Material and methods.** Fifty patients were examined before surgical resection of intracerebral tumors of the temporal and frontal lobes. 33 patients had left-sided tumors, and 17 patients had right-sided tumors. The functional asymmetry profile was determined by self-assessment, the Annet questionnaire, and the dichotic listening task: 12 people were left-handers or retrained left-handers, and the remaining 38 patients were right-handers. fMRI was performed on a SignaHDxt magnetic resonance imaging machine (GE, USA) with a magnetic field strength of 3.0 T. The standard language block design paradigm was used in the study. The following tests were used: 1) reciting the months in reverse order; 2) naming nouns according to initial letters shown on the screen (K, L, M, N, R, S); 3) naming action pictures; 4) producing sentences using nouns shown on the screen; 5) listeninh to a text with headphones. The data were processed using standard BrainWavePA software (GE, USA). The Z-test in the range of 6 to 9 was used ($p<0.001$ was in all tests). Statistical data analysis included the nonparametric Spearman's test for determining a correlation between lateralization of an identified activation area under speech load and the tumor localization (tumor is adjacent to the language area, invades it, or is distal of it) as well as between the functional brain asymmetry (left-handedness or right-handedness). **Results.** Activation of language areas on the left side only was identified in 16 patients (14 right-handers and 2 left-handers); in one left-handed patient, Broca's area was detected only on the right side. In the other patients (like in right-handers with right-sided tumors), lateralization of language areas was different, in particular bilateral. Statistical analysis of the data demonstrated that bilateral activation of both Broca's and Wernicke's areas was more often observed in left-handers. Broca's area was more frequently identified on the left, in the presence of a tumor distant from the area. This pattern did not apply to Wernicke's area. **Conclusions.** The localization of Broca's area activation is more dependent on the tumor location, while that of Wernicke area activation depends on the patient's individual characteristics.

Keywords: *preoperative fMRI, functional brain asymmetry, intracerebral tumors.*

Currently, the indications for surgical removal of brain tumors, even from the region of language and motor areas, are expanded. The main objective of these surgeries is complete tumor resection, with the functionality of structures in the immediate vicinity of the tumor or involved in it being preserved as much as possible. For this purpose, intraoperative awakening of the patient for electrostimulated identification of motor and language areas is increasingly used in neurosurgery. During intraoperative electrostimulation, the language area localization was shown to have wide individual differences. For example, the speech system can be represented, partly or completely, in the contralateral hemisphere and have many additional language areas [1—4]. Therefore, preoperative preparation of the patient with an intracerebral tumor should include non-invasive examination of not only the lateralization but also the localization of language areas with respect to the tumor.

Today, functional magnetic resonance imaging (fMRI) is a leading non-invasive method to determine the localization of language areas that enables their identification and dynamic monitoring of the functional speech system state both after neurosurgical operations and after conservative treatment. However, according to some authors [5—7], the result of fMRI-based identification of the dominant hemisphere for speech may depend on the proximity of the pathological focus to putative language areas, used tests, and also features of statistical data processing.

Currently, fMRI is actively developed. It is noteworthy that studies have used a very diverse set of tests for selective activation of language areas, which is determined by aims and objectives of researchers. The most often used test to localize language areas is generation of verbs or naming nouns associated with pictures and initial letters [6, 8—14] as well as different variants of listening to syllables, texts, and sentences [15—17]. Less often, tests for speech activation include semantic and syntactic tasks (e.g., allocation of visually or verbally presented animals to different groups, identification of misspelled words and sentences, completion of sentences) whose solution actively involves Broca's area [6, 7, 18, 19].

Most authors recommend using of several tests simultaneously to identify activation of language areas. In this case, it is noted that different tests may identify different language lateralization in the same patient [5,

© Group of authors, 2015

*e-mail: SBuklina@nsi.ru

7]. Our previous fMRI study of 21 patients [20] also demonstrated the incidence rate of bilateral activity foci in speech tests. It was noted that the maximum difficulties arose in examination of patients with large malignant tumors with pronounced peritumoral edema when language areas were activated only on the right side in the presence of a left-hemispheric tumor and speech disorders.

The fMRI-based activation pattern of language areas (their lateral or bilateral representation) is crucial for neurosurgical practice. In this connection, a question arose of what may primarily determine the activation pattern: the functional asymmetry profile (right-handedness/left-handedness according to various parameters) or the tumor proximity to putative language areas. Whether the fMRI-based pattern of the individual functional speech system of a particular patient reflects bilateral activation areas under speech load, or it is a result of reorganization of this system due to tumor growth (brain plasticity)?

The study aim was to determine the dependence of activation patterns of language areas identified by fMRI on the functional asymmetry profile and tumor localization. The study objectives were as follows:

1) development and evaluation of a necessary and sufficient test battery to localize language areas in patients with focal brain lesions;

2) determination of the dependence of the activation pattern of language areas in patients with tumors of the temporal and frontal lobes:

— on the functional asymmetry profile (right-handedness/left-handedness according to various parameters);

— on the proximity of the areas to the tumor (comparison of patients with a tumor adjacent or spreading to the language area and those with a tumor not adjacent to the language area).

Material and Methods

Fifty patients were examined prior to intracranial tumor resection: 27 (54%) males and 23 (46%) females aged 14 to 70 years; the mean age was 34.5 years; the median and the interquartile range were 28 and 48.75, respectively. 48 patients were detected with gliomas of different grades (only 1 patient had metastasis of ovarian cancer and Ewing sarcoma). The tumor localization in all patients was identified by MRI. The patients' distribution according to the tumor localization is shown in **Table 1**. In addition to the temporal and frontal lobes, in some cases, tumors spread, albeit to a lesser extent, to adjacent parts of the brain (parietal or insular lobes).

Most of the examined patients had no focal neurological losses. 7 patients had speech disorders in accordance with the tumor localization, with predominantly mild severity (in the case of temporal lobe tumor — acoustic-mnestic aphasia; in the case of frontal lobe tumor — efferent motor aphasia); 3 of them were detected with mild hemiparesis or hemihypesthesia.

The functional asymmetry profile was evaluated by self-assessment, the Annet questionnaire, and the dichotic listening task. According to the self-assessment and questionnaire, 12 people among the tested patients were left-handers or retrained left-handers performing most everyday actions (except eating and writing) with the left hand; the other 38 patients were right-handers (some had single signs of the left-handedness, according to the questionnaire). Dichotic listening was conducted in 33 patients (it failed in some patients due to speech disorders or gross auditory-verbal memory disorders). 23 patients had positive values of the right ear coefficient (REC), typical of left hemisphere speech dominance in right-handers. Negative and zero REC values indicating right hemisphere speech dominance or incomplete left hemisphere speech dominance were detected in 10 patients, with 3 of them being left-handers or retrained left-handers. It is worth noting a group of 7 patients with negative REC who considered themselves right-handers. Of them, 5 had large glioma with peritumoral edema in the left hemisphere; 2 had left-handers among relatives. A change in REC toward negative values (typical of left-handers) was detected in right-handers in the case of a large tumor in the left hemisphere, which may indicate speech system reorganization detectable during the dichotic listening test. However, this issue requires further investigation.

To qualify disorders of higher mental functions, all patients prior to fMRI underwent a full neuropsychological examination according to the Luria's method [21] to exclude those who had contraindications for fMRI because fMRI requires the patient to be active, adequate, and capable of well understanding and keeping a task program and timely switching in accordance with the instructions.

We used a SignaHDxt magnetic resonance imaging machine (GE, USA) with a magnetic field strength of 3.0 T and a NordicNeuroLabActiva special station (GE, USA). In addition to standard pulse sequences in the T1 and T2 mode, the study included mandatory imaging in the 3DT1 FSPGR mode (for 4 min) with the 1 mm resolution in all coordinates and over the whole head. Automatic synchronization of sequence start was performed. fMRI examination with the use of a single test lasted 5 min 12 s.

The patients were asked to perform special task paradigms to activate different areas of the cerebral cortex during fMRI. A standard speech block design paradigm included:

— 12-second preparation period required to determine the mean brain excitation level;

— 5 rest periods (R) alternating with 5 activation periods (A), with the 30 s duration of each.

In the rest period, the patient did not perform any movements and lay motionless with eyes open; during

the activation period, the patient had to perform a task, which depended on the used paradigm. According to the literature data, the patient had to perform all tasks silently, without moving the tongue and the lips. These movements lead to activation of bilateral regions of the motor cortex in the precentral gyrus that are located near Broca's area, which may complicate data processing. The patient just had to listen to the text, trying to understand its content. The patient was informed about the beginning of the activation period either by an audio signal through headphones or by commands displayed on the screen of special glasses.

To localize Broca's and Wernicke's speech areas, the following paradigms were selected (taken from literature, original and modified):

— reciting the months in reverse order;

— generation of nouns according to initial letters displayed on the screen (K, L, M, N, R, S);

— generation of verbs according to simple (not genre) pictures shown on the screen (e.g., house, horse, car, etc.; a total of 30);

— producing sentences according to nouns displayed on the screen;

— listening through headphones to a cognitive, emotionally indifferent text.

The first test was the original one and was suggested based on the ideas of classical aphasiology [21, 22] on the complexity of switching upon utterance of a de-automated series (counting and reciting the months in reverse order) in the case of affected Broca's area. The remaining tests were prepared in principal accordance with the literature [6, 8—14], but were adapted to the study objectives and Russian language (e.g., nouns began with a consonant letter). The displayed pictures were simple and figural and did not cause difficulties in recognition.

The data were analyzed using BrainWavePA standard software (GE, USA) for processing of clinical data. Mapping of activation was accompanied by automatic segmentation of the anatomical data, motion correction of the functional data, smoothing with a 8-mm Gaussian spatial filter in all directions, and application of the basic linear multiple regression model using standard software. Assessment of the efficiency of freedom degrees of used programs was performed by the method of Worsley and Friston, which enables transformation of t-test maps into z-activation maps and matching of anatomical and functional AIR images by the method of Woods et al. We used the Z-test in the range of 6 to 9. There was $p<0.001$ in all tests.

Table 1. **Tumor localization in brain lobes in examined patients (*n*=50)**

Hemisphere	Lobe	
	temporal	frontal
Left (*n*=33)	16	17
Right (*n*=17)	7	10

Statistical data analysis included the nonparametric Spearman's test for determining a correlation between lateralization of an identified activation area under speech load and the tumor localization (close to/distant from the language area) as well as between the right-handedness and the left-handedness.

Results

Broca's area was identified as an activation area in *pars triangularis* and/or *pars opercularis* in the posterior parts of the inferior frontal gyrus, sometimes on the border with the middle frontal gyrus. Wernicke's area was identified as an area activated in response to speech loads strictly in the posterior part of the superior temporal gyrus or at the junction of the temporal and parietal lobes. Presentation of a text to headphones (main test for identification of Wernicke's area, according to the literature) led to that an extensive activation area of the primary auditory cortex was contiguous to Wernicke's area (and merged with it), which made it difficult to identify the language area. For this reason, a special procedure was developed: statistical analysis of fMRI images was performed under the maximum Z-test value in the range of 8—9, which enabled a good differentiation between the primary auditory cortex and Wernicke's area.

In addition to the standard language areas, speech loads also activated in all patients some other areas of the brain: the extra motor cortex was activated in almost all patients; various parts of the cerebellum were activated in most of the patients (in this case, activation areas in the hemispheres were contralateral to activation foci of Broca's area); precentral areas of the brain in the projection of the oral musculature and some subcortical structures (thalamus, subcortical nuclei) were activated in several patients (in different tests). Analysis of the causes of activation of these brain parts requires further research. In addition, all patients were detected with activation of the visual cortex during visual presentation of letters or images and with activation of the auditory cortex upon listening to a text.

Assessment of the efficiency of various speech tests yielded the following data.

1. Broca's area was activated in 31 (62%) of 50 patients upon reciting the months in reverse order: right-sided activation was observed in 5 (10%) patient; left-sided activation was in 18 (36%) patients; bilateral activation was in 8 (16%) patients. Activation of Wernicke's area in this test was observed in 16 (32%) of 50 patients: activation was both in the left hemisphere and in the right hemisphere in 7 (14%) patients, and bilateral activation was in 2 (4%) patients.

2. Generation of nouns according to presented letters caused activation of Broca's area in 39 (80%) of 49 patients: right-sided activation was in 6 (12%) patients;

left-sided activation was in 26 (53%) patients; bilateral activation was in 7 (14%) patients. Wernicke's area was activated in 24 (49%) patients: left-sided activation was observed in 17 (35%) patients; right-sided activation was in 2 (4%) patients; bilateral activation was in 5 (10%) patients.

3. Generation of verbs according to presented pictures caused activation of Broca's area in 35 (74%) of 47 patients: right-sided activation was in 4 (9%) patients; left-sided activation was in 23 (49%) patients; bilateral activation was in 8 (17%) patients. Wernicke's area was activated in 15 (32%) patients: right-sided activation was in 2 (4%) patients; left-sided activation was in 10 cases (21%); bilateral activation was in 3 (6%) patients.

4. Producing sentences with suggested nouns activated Broca's area in 40 (87%) of 46 patients: right-sided activation was observed in 6 (13%) patients; left-sided activation was in 27 (59%) patients; bilateral activation was in 7 (15%) patients. Wernicke's area was activated in 30 (65%) patients: right-sided activation was in 2 (4%) patients; left-sided activation was in 23 (50%) patients; bilateral activation was in 5 (11%) patients.

5. Listening to a text is a specific test for mapping of Wernicke's area. This area was activated in 35 (73%) of 48 patients: right-sided activation was observed in 4 (8%) patients; left-sided activation was in 16 (33%); bilateral activation was in 15 (31%) patients. Broca's area is not activated by this test.

To determine the dependence of the localization of activation foci in response to speech tests on the functional asymmetry profile, the number of activation foci was counted in right-handed patients (38 patients) and left-handed patients (12). The data are presented in **Table 2**. The total number of activation foci in right-handed patients was 88: Broca's area was activated 48 times, and Wernicke's area was activated 40 times (bilateral activation was considered as 2 foci). The total number of activation foci in left-handed patients was 35: Broca's area was activated 18 times, and Wernicke's area was activated 16 times (bilateral activation was considered as 2 foci). According to fMRI, speech load caused activation of 2.32 foci in a right-handed patient and 2.92 foci in a left-handed patient, on average. The left-handers had a larger number of activation foci in the contralateral hemispheres, and this result was statistically significant (Spearman's rank correlation coefficient: $r=-0.322$). Thus, lateralization of activation foci depends on the functional asymmetry profile (right-handedness/left-handedness).

To evaluate the dependence of fMRI identification of activation foci of language areas on the tumor localization, a group of 20 patients with tumors of the frontal and temporal lobes of the left hemisphere was specifically selected. In these patients, the tumor was immediately adjacent to putative language areas or spread to them. The results of statistical data processing demonstrated that Broca's area was statistically significantly more often activated in the left hemisphere in the presence of tumors distant from it ($r=-0.302$). Different types of Broca's area activation (left-sided and bilateral; in single cases with glioblastomas and pronounced edema — right-sided only) were identified in the presence of tumors adjacent to language areas or invading them. It is important that this pattern did not apply to Wernicke's area. Its localization was correlated with the ear to which the patient brought the phone. Interestingly, the right-handers more often brought the phone to the right ear only, less often — to both ears, and even more rarely — to the left ear only. However, the left-handers never brought the phone to the right ear only; they brought the phone to the left ear only or to both ears ($r=0.504$). If the phone was brought to the right ear only, then Wernicke's area was more frequently detected on the left side ($r=0.427$). This is due to the fact that speech perception is primarily involved in both a phone conversation and listening to a text.

Discussion

When five speech tests were used, activation areas were identified in all patients, but had a different localization. However, the situation was more complex in 2 patients with very large glioblastomas of the fronto-temporal and temporo-frontal localization; in one case, Broca's area was not identified at all (but 2 Wernicke's areas were activated in the contralateral hemispheres); in the other case, no language areas were activated in the left hemisphere (only an activation area homologous to Broca's area in the right hemisphere was observed). Both of these patients at admission had acoustic-mnestic aphasia, with the second patient presenting with a more severe form of it and with elements of efferent motor aphasia. Glioblastomas in these patients were surrounded by large peritumoral edema and spread directly to language areas. The causes for the complexity of fMRI-based identification of language areas in patients with large malignant tumors were discussed previously [20].

Most of the examined patients (33 (66%) out of 50) were detected with a rather mixed activation pattern in response to speech stimulation. In most of the right-handed patients with a right-sided tumor, bilateral activation of language areas could be observed (Wernicke's area was especially often involved); activation of one and another language area on both sides and bilateral activation of Broca's or Wernicke's area could be observed in various tests **(Figs. 1—4).**

Analysis of the data on activation of language areas revealed a large percentage of bilateral activations: only 16 (32%) of 50 patients had one left-sided activation of Broca's area and Wernicke's area; in the remaining patients, there was bilateral representation of at least one language area. Of these 16 patients, 9 were diagnosed with a tumor on the left side, and 7 were diagnosed with a tumor on the right side. Interestingly, 2 of 9 patients

Table 2. **The distribution of activation foci in Broca's and Wernicke's areas in patients with the functional brain asymmetry**

Functional brain asymmetry	Broca's activation			Wernicke's activation			A total number of activation foci
	left	bilateral	right	left	bilateral	right	
Right-handers (n=38)	24	11*	2	20	9*	2	88
Left-handers (n=12)	6	6*	0	8	4*	0	34

Footnote. * — during counting, bilateral activation was considered as 2 activation foci.

(with left-sided tumor) were retrained left-handers; the others of 16 patients were right-handers. These patients were congenital left-handers with left-sided tumors who had only one Broca's and Wernicke's activation area in the left hemisphere. Another left-handed patient (without family left-handedness) was detected with Broca's area located predominantly on the right side (left-sided area was minimally activated); however, Wernicke's area was activated distinctly on one side, but on the left. The patient was diagnosed with a tumor of the right frontal lobe that was adjacent to the language activation area detected by fMRI **(Fig. 4)**. In the Wada test, speech disorders were detected in the case of right-sided drug administration. Electrostimulation of the language area of the right frontal lobe during surgery with awakening caused arrest of speech; after the operation, slight efferent motor aphasia was observed; i.e. in this patient, the right-sided localization of Broca's area was fully verified, but Wernicke's area was identified on the left (according to fMRI).

Of the used tests, the most effective test was producing sentences according to visually presented nouns: it allowed identification of Broca's area in 87% of cases. Importantly, it also allowed identification of Wernicke's area in 65% of patients (totally, in patients with different tumor lateralization). In this case, the percentage of Wernicke area activation in this test was only slightly lower than in listening to a text (73%). And this is not surprisingly: producing sentences is the most difficult speech task that requires joint work of various parts of the speech system: understanding the presented word and finding words semantically appropriate to it are functions of the temporal lobe; proper arrangement of words in a sentence and grammar are functions of Broca's area. Two other tests were also effective: generation of nouns according to presented letters (activation of Broca's area was in 80% of cases; activation of Wernicke's area was in 49% of cases) and generation of verbs according to presented pictures (activation of Broca's area was in 74% of cases, and activation of Wernicke's area was in 32% of cases). It is necessary to pay attention to the frequency of Wernicke's area activation upon carrying out these three tests by patients, although the literature discusses their use only for activation of Broca's area [23, 24]. The test for generation of verbs, particularly recommended in the literature for activation of Broca's area [9], turned out to have no advantages over other tests because actualization of verbs is disturbed in Broca's aphasia; also, "telegraphic speech" may occur in Broca's aphasia [21, 22].

This different activation of language areas in patients in response to the used tests primarily reflected individual features of the functional speech system of a particular patient and his previous experience. For example, the first test of reciting the months in reverse order, which caused Broca's area activation only in 62% of patients, was probably not sufficient for speech load in most of the patients. Naming nouns according to pictures and producing sentences according to the presented word (the most difficult speech tasks) activated not only Broca's areas in the maximum number of patients (up to 87%) but also Wernicke's areas (up to 49%), i.e. performing these tasks involved various parts of the functional speech system, but very individually.

Often, bilateral identification of Wernicke's area activation may also be associated with that perception of well known short words during listening to a text can occur in the right temporal lobe as well. This was previously shown in patients with a "split-brain" [25]. Apparently, the right temporal lobe of investigated patients was involved in perception of a speech material to a different degree. All this may indicate that lateralization of Wernicke's area is associated with the

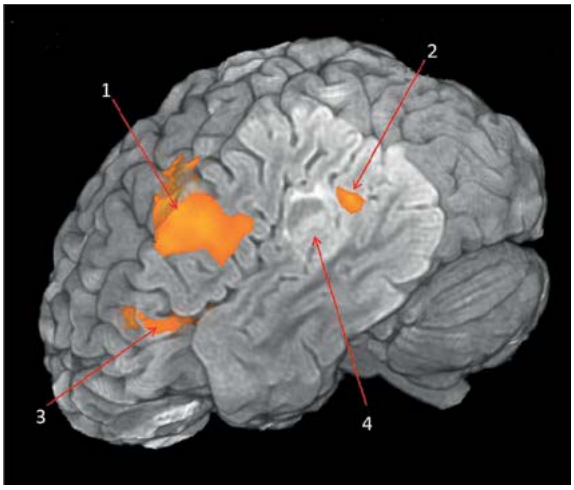

Fig. 1. **fMRI of a male patient with glioma of the left temporal region: left-sided activation of language areas during generation of nouns according to presented letters.**

1 — activation area in the left precentral gyrus; 2 — Wernicke's area in the left hemisphere; 3 — Broca's area in the left hemisphere; 4 — glioma.

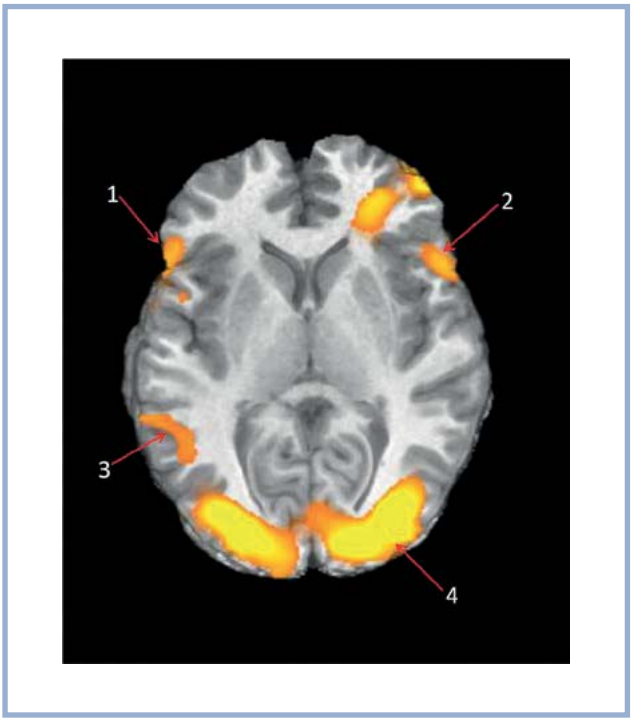

Fig. 2. **fMRI of a male patient with glioma of the right frontal lobe: bilateral activation of Broca's areas and left-sided activation of Wernicke's area during generation of verbs according to presented pictures.**

1 and 2 — Broca's area in the left and right hemispheres; 3 — Wernicke's area in the left hemisphere; 4 — activation of the visual cortex.

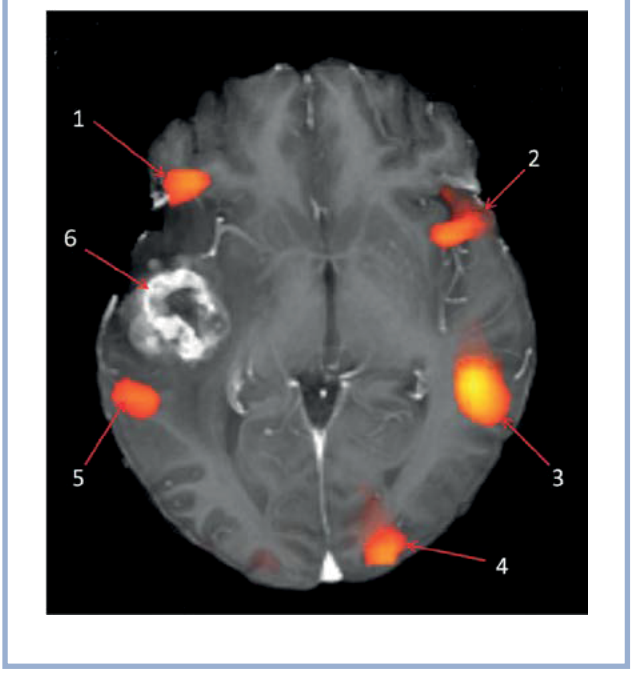

Fig. 3. **fMRI of a female patient with ovarian cancer metastasis in the left temporal lobe: bilateral activation of language areas during producing sentences with presented words.**

1 and 2 — Broca's area in the left and right hemispheres; 3 and 5 — Wernicke's area in the right and left hemispheres; 4 — activation of the visual cortex; 6 — ovarian cancer metastasis.

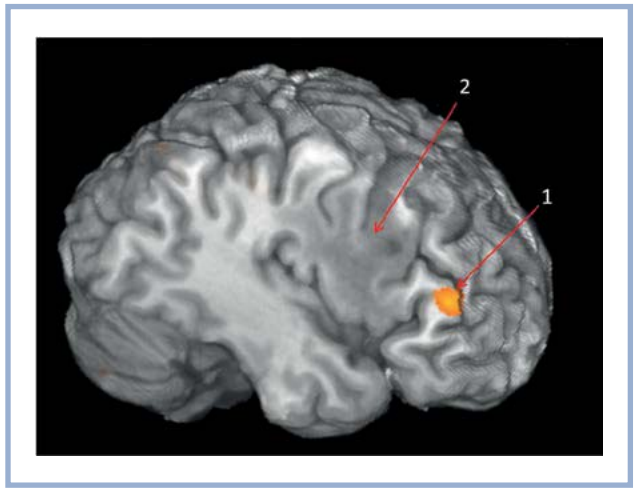

Fig. 4. **fMRI of a male patient with glioma of the right frontal lobe: right-sided activation of Broca's area during reciting the months in reverse order.**

1 — Broca's area in the right hemisphere; 2 — glioma.

individual organization of the speech system to a greater degree than lateralization of Broca's area.

Currently, there are many studies related to investigation of reorganization of the functional speech system in stroke patients [8, 26—28], in surgical treatment of patients with pharmacoresistant epilepsy [23, 29] as well as in patients with brain tumors [30, 31]. For example, A. Thiel et al. [31] in 2001 reported plasticity of the speech system in patients with tumors (based on the PET data). S. Partovi et al. [24] in 2012 identified a change in the localization of activation areas in patients after tumor resection. Investigation of recovery of not only speech but also movements demonstrated that in the presence of paresis after tumor resection, bilateral activation areas arise in the brain in response to movement of the paretic arm [32, 33]. However, analysis of studies investigating the functional speech system in the presence of focal lesions revealed that patients with a left-sided lesion, right-handers or left-handers, were mainly examined, while patients with the right-sided localization of a lesion were examined only if they were left-handers, and the right-sided localization of language areas was assumed. Activation of language areas in right-handed patients with right-sided lesions was virtually unexplored. However, its study would complete the picture of individual differences in the structure of the functional speech system in the presence of a lesion, and the study should be continued.

Therefore, this study demonstrated that the pattern of identified activation foci of language areas (on the basis of fMRI) depends on both the individual organization of the functional speech system (primarily, Wernicke's area) and the presence of a tumor near language areas (in particular, Broca's area).

Conclusions

1. The proposed tests to activate language areas during fMRI proved to be adequate for examination of patients with gliomas.

2. The most effective tests to activate language areas during fMRI were as follows: naming nouns according to presented letters, naming action pictures, and producing sentences according to presented nouns as well as listening to a text. However, these tests should be used in combination since activation of language areas in response to the suggested tests might be identified differently, which does not exclude misinterpreting lateralization of language areas.

3. Lateralization of language area activation depended on both the individual organization of the functional speech system and the tumor localization (whether the tumor is immediately adjacent to the language area or invades it, or not).

4. Lateralization of Broca's area was largely dependent on the tumor localization, while that of Wernicke's area depended on the individual organization of the functional speech system, including the functional asymmetry profile.

5. Identification of language area lateralization requires the use of not only fMRI but also other methods, including clinical and neuropsychological ones (identification of speech disorders, including transient ones; determination of the functional asymmetry profile).

6. fMRI together with speech loads can be used to detect the localization of language areas with respect to the tumor and to follow-up the condition of patients with focal brain lesions.

This work was supported by a grant of the Russian Scientific Foundation № 14-15-01092.

REFERENCES

1. Benson RR, FitzGerald DB, leSueur LL, Kennedy DN, Kwong KK, Buchbinder BR, Davis TL, Weisskoff RM, Talavage TM, Logan WJ, Cosgrove GR, Belliveau JW, Rosen BR. Language dominance determined by whole brain functional MRI in patients with brain lesions. *Neurology.* 1999;52(4):798—809. PMID: 10078731.
2. Binder JR, Swanson SJ, Sabsevitz DS, Hammeke ThA, Raghavan M, Mueller WM. A comparison of two fMRI methods for predicting verbal memory decline after left temporal lobectomy: language lateralization versus hippocampal activation asymmetry. *Epilepsia*. 2010;51(4):618—626. DOI: 10.1111/j.1528-1167.2009.02340.x.
3. Bookheimer S. Pre-surgical language mapping with functional magnetic resonance imaging. *Neuropsychol Rev.* 2007;17:145-155. PMID: 17484055.
4. Steinmerier R, Sobottka SB, Reiss G, Bredow J, Gerber J, Schackert G. Surgery of low-grade gliomas near speech-eloquent regions: brainmapping versus preoperative functional imaging. *Onkologie.* 2002;25(6):552-557. PMID: 12566901.
5. Petrovich N, Holodny AI, Tabar V, Correa DD, Hirsch J, Gutin PH, Brennan CW. Discordance between functional magnetic resonance imaging during silent speech tasks and intraoperative speech arrest. *J Neurosurg.* 2005;103(2):267—274. PMID: 16175856.
6. Ruff IM, Petrovich Brennan NM, Peck KK, Hou BL, Tabar V, Brennan CW, Holodny AI. Assessment of the language laterality index in patients with brain tumor using functional MR imaging: effects of thresholding, task selection, and prior surgery. *Am J Neuroradiol.* 2008;29:528-535. DOI: 10.3174/ajnr.A0841. Epub 2008 Jan 9.
7. Springer JA, Binder JR, Hammeke ThA, Swanson SJ, Frost JA, Bellgowan PSF, Brewer CC, Perry HM, Morris JL, Mueller WM. Language dominance in neurologically normal and epilepsy subjects. *Brain*. 1999;122:2033-2045. PMID: 10545389.
8. Belopasova A.V. *Functional reorganization of the speech system in patients with post-stroke aphasia.* Candidate of Medicine Thesis. Moscow 2012. Available at: http://neurology.ru/professional/avtoreferat_Belopasova_AV.pdf. Link was active on March 23, 2015. In Russian.
9. Vlasova R.M. *Brain mechanisms of the nominative function of speech: a neuropsychological and neuroimaging approach*. Candidate of Psychology Thesis. Moscow 2013. Available at: http://psy-science-council.ru/dissertaions/?Dissertaion=2360. Link was active on March 23, 2015. In Russian.
10. Escorsi-Rosset S, Wichert-Ana L, Bianchin MM, Velasco TR, Sakamoto AC, Leite JP, Santos AC, de Araujo DB. Variable fMRI activation during two different language tasks in a patient with cognitive delay. *Arq Neuropsiquiatr.* 2007;65(4):985-987. PMID: 18094859.
11. Kapsalakis IZ, Kapsalaki EZ, Gotsis ED, Verganelakis D, Toulas P, Chung I, Fezoulidis I, Papadimitriou A, Robinson JS, Lee GS, Fourtas KN. Preoperative Evaluation with fMRI of Patients with Intracranial Gliomas. *Radiology Research and Practice.* 2012;2012:727810. DOI: 10. 1155/2012/727810. Epub 2012 Jul 12.
12. Pang EW, Wang F, Malone M, Kadis DS, Donner EJ. Localization of Broca's area using verb generation tasks in the MEG: Validation against fMRI. *Neurosci Lett.* 2011;490(3):215-219. DOI: 10.1016/j.neurolet.2010.12.055. Epub 2010 Dec 30.
13. Roux FE, Boulanouar K, Lotterie JA, Mejdoubi M, LeSage JP, Berry I. Language functional magnetic resonance imaging in preoperative assessement of language areas: correlation with direct cortical stimulation. *Neurosurg.* 2003;52(6):1335-1345. DOI: 10.1227/01.NEU.0000064803.05077.40.
14. Voets NL, Adcock JE, Flitney DE, Behrens TE, Hart Y, Stacey R, Carpender K, Matthews PM. Distinct right frontal lobe activation in language processing following left hemisphere injury. *Brain*. 2006;129:754-766. PMID: 16280351.
15. Mayorova L.A., Martynova O.M., Fedina O.N., Petrushevskiy A.G. fMRI study of speech perception disorders in patients with post-stroke sensory aphasia. *Zhurnal Vysshey Nervnoy Deyatel'nosti.* 2013;3:328-337. In Russian.
16. Abo M, Kasahara K, Kakuda W, Senoo A. Functional MRI activation in repetition task using block and event-related design. *The J of Applied Research*. 2009;9(3):119-122.
17. Andoh J, Artiges E, Pallier C, Riviere C, Mangin JF, Cachia A, Plaze M, Paillere-Martinot M.L., Martinot J.L. Modulation of language areas with functional MR image-guided magnetic stimulation. *NeuroImage.* 2006;29:619-627. PMID: 1616867.
18. Embick D, Marantz A, Mivachita Y, O'Neil W, Sakai KL. A syntactic specialization for Broca's area. *PNAS.* 2000;97(11):6150-6154. PMID: 10811887.
19. Gartus A, Foki T, Geissler A, Beisteiner R. Improvement of Clinical Language Localization with an Overt Semantic and Syntactic Language Functional MR Imaging Paradigm. *AJNR Am J Neuroradiol.* 2009;30:1977-1985. DOI: 10.3174/ajnr.A1725. Epub 2009 Jul 30.
20. Buklina S.B., Podoprigora A.E., Pronin I.N., Shishkina L.V., Boldyreva G.N., Bondarenko A.A., Fadeeva L.M., Kornienko V.N., Zhukov V.Yu. Functional MRI studies of the hemisphere dominant for speech in patients with brain tumors. *Voprosy Neirokhirurgii.* 2013;5:30-37.
21. Luria A.R. *Disorders of higher cortical functions in focal brain lesions.* Moscow: MGU 1962;432. In Russian.
22. Tsvetkova L.S. *Neuropsychological rehabilitation of patients.* Moscow: MGU 1985;327. In Russian.
23. Bonelli SB, Thompson PJ, Yogarajah M, Vollmar C, Powell RH, Symms MR, McEvory AW, Micalef C, Koepp MJ, Duncan JS. Imaging language networks before and after anterior temporal lobe resection: results of a longitudinal fMRI study. *Epilepsia*. 2012;53(4):639-650.
doi: 10.1111/j.1528-1167.2012.03433.x.

24. Partovi S, Jacobi B, Rapps N, Zipp L, Karimi S, Rengier F, Lyo JK, Stippich C. Clinical Standardized fMRI reveals altered language lateralization in patients with brain tumor. *AJNR Am J Neuroradiol.* 2012;33:2151-2157. DOI: 10.3174/ajnr.A3137. Epub 2012 May 17.

25. Gazzaniga M.S. The split brain in man. In: Perception. *Mechanisms and models.* Moscow: Nauka 1974;47-57. In Russian.

26. Hosoda C, Tanaka K, Nariai T, Honda M, Hanakawa T. Dynamic neuronal network reorganization associated with second language vocabulary acquisition: a multimodal imaging study. *J neurosci.* 2013;21:33(34):13663-13672. doi: 10.1523/neurosci.0410-13.2013.

27. Jarso S, Li M, Faria A, Davis C, Leigh R, Sebastian R, Tsapkini K, Mori S, Hillis AE. Distinct mechanisms and timing of language recovery after stroke. *Cognitive Neuropsychology.* 2013;30:454-475. doi: 10. 1080/02643294.2013.875467. Epub 2014 Jan 28.

28. Papagno C, Gallucci M, Casarotti A, Castellano A, Falini A, Fava E, Giussani C, Carrabba G, Bello L, Caramazza A. Connectivity constraints on cortical reorganization of neural circuits involved in object naming. *Neuroimage.* 2011;55:1306-1313. doi: 10.1016/j.neuroimagr.2011.01.005.

29. Stewart CC, Swanson SJ, Sabsevitz DS, Rosman ME, Janecek JK, Binder JR. Predictors of language lateralization in temporal lobe epilepsy. *Neuropsychologia.* 2014;60:93—102. doi: 10.1016/j.neuropsychologia.2014.05.021. Epub 2014 Jun 4.

30. Hayashi Y, Nakada M, Kinoshita M, Hamada J-I. Surgical strategies for nonenhoncing slow-growing gliomas with special reference to functional reorganization review with own experience. *Neurol Med Chir.* (Tokyo) 2013;53:438-446. PMID: 23883554.

31. Thiel A, Herholz K, Koyuncua, Kracht LW, Habedank B, Heiss WD. Plasticity of language networks in patients with brain tumors: positron emission tonography activation study. *Ann Neurol.* 2001;50(5):620-629. PMID: 11706968.

32. Busheneva S.V. Functional reorganization of the motor systems after stroke. Candidate of Medicine Thesis. Moscow 2007. Available at: http://www.dslib.net/bolezni-nervov/funkcionalnaja-reorganizacija-dvigatelnyh-sistem-posle-insulta.html. Link was active on March 23, 2015. In Russian.

33. Tozakidou M, Wenz H, Reinhardt J, Nennig E, Riffel K, Blatow M, Stippich C. Primary motor cortex activation and lateralization in patients with tumors of central region. *Neuroimage Clin.* 2013;14:2:221-228. doi: 10.1016/j. nicl.2013.01.002.eColletion 2013.

Commentary

Over the past decades, non-invasive mapping of the eloquent brain areas, such as motor and language areas, has become increasingly popular in preoperative brain mapping due to introduction of neuroimaging techniques into clinical practice. The complexity of studying the language cortex is associated with its predominant lateralization and its certain variability in different people. In addition, tumor growth results in a displacement of functionally important regions from their usual topography.

This article highlights the problem of choosing the optimal algorithms of fMRI for mapping of language areas in patients with intracerebral tumors of mainly frontal and temporal localization and with different functional asymmetry profiles. The authors suggested the use of several paradigms for accurate verification of secondary motor and sensory language areas, demonstrated an individual variability of the functional asymmetry of language areas in right-handers and left-handers as well as the effect of tumor localization on activation of the language cortex, analyzed in detail the results of examination of a sufficiently large number of patients, and suggested algorithms of preoperative clinical fMRI examination of the patient for precise mapping of language areas. The use of fMRI with speech loads is very important for identification of the language area localization with respect to the tumor and also for examination of these patients over time.

It should be noted that activation (increased cerebral blood flow) of areas in both hemispheres during fMRI is not always related to functional manifestations. For example, fMRI examination of healthy volunteers (right-handers) often reveals activation of language areas in both hemispheres; however, patients (right-handers) who underwent right-sided ischemic stroke rarely develop aphasia in contrast to patients with left hemispheric strokes. Investigation of the role of right hemispheric homologues of language areas as well as tertiary language areas requires further research.

M.V. Krotenkova (Moscow, Russia)

Dear readers!

In the article by E.G. Pedachenko, V.V. Beloshitskiy, S.A. Mikhal'skiy, N.Ya. Gridina, T.Yu. Kvitnitskaya-Ryzhova "The Effect of APOE3 Gene Therapy on Structural and Functional Manifestations of Secondary Hippocampal Damages in Experimental Traumatic Brain Injury" published in issue 2, 2015, the abbreviation GT stands for "gene therapy". The term "glutathione S-transferase" was used erroneously.
The Editorial Board apologizes for this.