doi: 10.17116/neiro201579380-85

New Surgical Treatment for Vertebral Artery Pseudoaneurysms at the Boundary between the V_2 and V_3 Segments

G.I. ANTONOV[1], E.R. MIKLASHEVICH[1], S.YU. GLADYSHEV[1], I.O. BOGDANOVICH[2]

[1]3rd Central Military Clinical Hospital n.a. A.A. Vishnevsky, RF Ministry of Defense, Krasnoyarsk, Russia; [2]Russian Medical Academy of Postgraduate Education, Department of Neurosurgery, Moscow, Russia

The clinical case of a patient with a pseudoaneurysm of the left vertebral artery at the boundary between V_2 and V_3 segments after a stab wound to the neck is reported. The patient underwent a rare variant of surgical reconstruction of the vertebral artery, including resection of the vertebral artery pseudoaneurysm at the boundary between the V_2 and V_3 segments, the vertebrovertebral autovenous shunting (from the C_{IV} vertebra to the C_I—C_{II} vertebrae with resection of the anterior wall of the vertebral artery canal). Postoperatively, SCT angiography revealed satisfactory blood flow in the shunt and improvement of the neurological status. The article provides a literature review on surgical procedures at the distal portion of the vertebral artery. The surgical technique was illustrated (intraoperative photos), demonstrating that the vertebral artery can be easily mobilized at any part of the V_2 segment with minimum damage to the adjacent tissues.

Keywords: *vertebral artery, false aneurysm, autovenous bypass.*

Vertebral artery (VA) is a paired vessel of the vertebrobasilar system and supplies functionally different parts of the central nervous system with blood, from the spinal cord to the cerebral cortex. All kinds of its impairment cause polymorphic clinical presentation of the disease. Symptoms of circulatory disorders and localization of the foci depend on the location and extent of VA lesion. The circulation disorders may be asymptomatic when there is sufficient blood flow compensation even following occlusion of one vertebral artery.

Lesions of VA are most often characterized by slow manifestation of symptoms and progressive course with prolonged recurrence. When extracranial parts of VA are impaired (V_1—V_3 segments) the following symptoms are observed: vertigo; tinnitus with hearing deterioration; violation of statics and imbalance (on the side of lesion), phonation and swallowing; dysarthria, diplopia, nystagmus, visual disturbances, and gaze paresis. Spastic paresis or paralyses develop on the side opposite to the occlusion (rough stenosis). Various types of Wallenberg-Zakharchenko's syndrome and symptoms of the arteries impairment in the basin of the medulla oblongata are manifested when there is thrombosis or stenosis of V_4 (intracranial) segment of VA.

Arterial aneurysms (AAs) are a type of disorders in VA, which is fortunately quite rare. While 5—15% [1, 2] of all cerebral aneurysms are located in the vertebrobasilar pool (VBP), the share of only 1% of intracranial aneurysms affect the VA itself. Only 0.4% of these can be cured surgically [1]. Aneurysms of VA at the pre-hemorrhage stage are often asymptomatic or occur as a tumor of the posterior fossa. The clinical presentations of VA aneurysms are manifested in symptoms of VII—XII cranial nerves disorders and cerebral symptoms. As a rule, etiology of vertebral artery aneurysms is either traumatic or dysplastic and is rarely post-infectious.

The world literature describes only a few publications devoted to the description of vertebral artery aneurysms in the extracranial segments. To date, the greatest number of cases (12 cases) of aneurysms of the extracranial portion of VA was presented by R. Berger, who described patients with Ehlers-Danlos and Marfana diseases, and AAs of both vertebral arteries was observed in 7 cases [3].

The most diverse surgical tactics have been proposed over the past 30 years, but the V_3 segment of the VA was necessary to be involved. The possibility of bypass from the distal vertebral artery for VA occlusion was reported for the first time in 1977 by A. Carney et al. [4]: they performed the first autogenous vein bypass (AVB) from the common carotid artery (CCA) to the distal vertebral artery. In the same year, G. Corkill et al. [5] used the external carotid artery (ECA) for shunting from V_3 segment of VA. In 1978 A. Carney et al. [6] reported the opportunity of carotid distal vertebral artery bypass for carotid artery occlusion at C_I—C_{II} level. B. George and C. Laurian [7] in 1979 improved the approach to V_3 segment of VA and used it for clipping the aneurysm of VA at C_{III} vertebra with the creation of anastomosis between subclavian artery and distal vertebral artery at C_I—C_{II} level. In 1981, G. Besson et al. [8] presented two observations with different types of external carotid-distal-vertebral autovenous shunting and A. Carney et al. [9] described the use of well palpable V_3 segment loop of VA at C_I—C_{II} with anastomosis to ECA and that a hypertrophic occipital artery may be directly anastomosed to the vertebral artery.

© Group of authors, 2015

*e-mail: i.o.bogdanovic@gmail.com

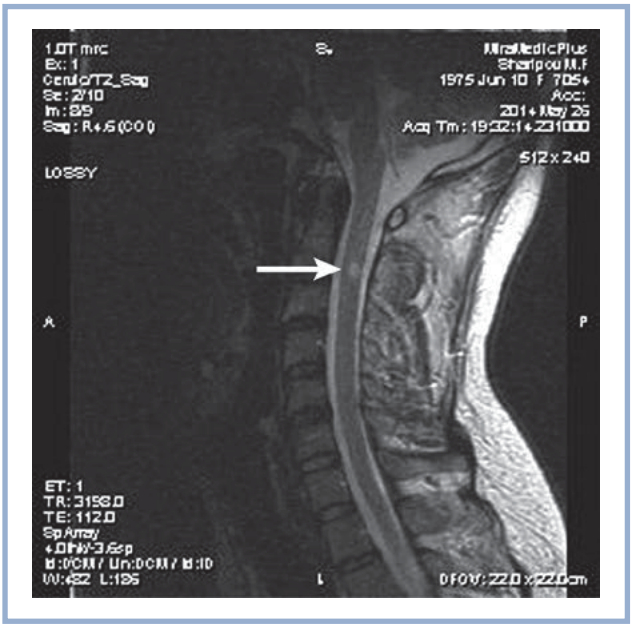

Fig. 1. **Focus of post-traumatic myelopathy at C_{II} vertebrae (indicated by the arrow).**

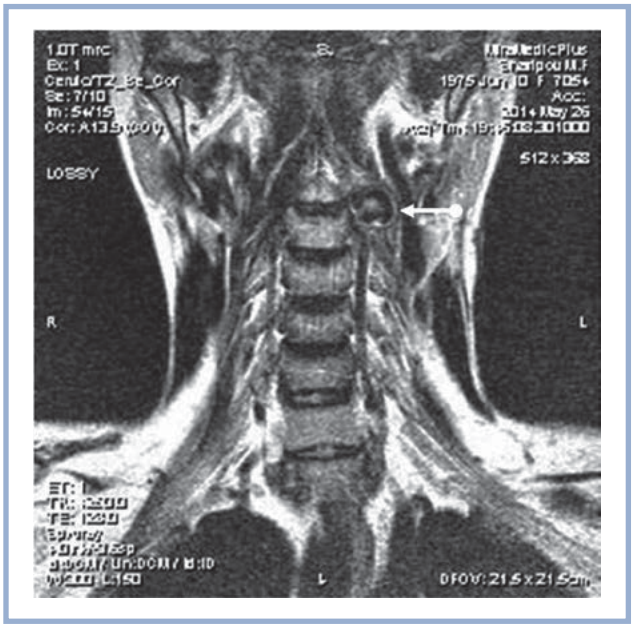

Fig. 2. **Pseudoaneurysm of left VA at C_{II}—C_{III} vertebrae (indicated by the arrow).**

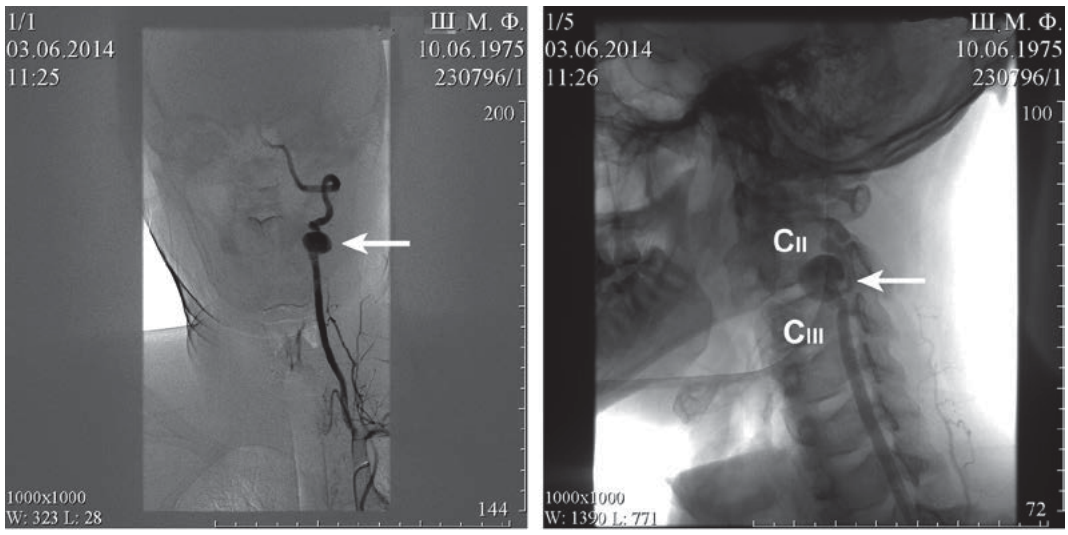

a b

Fig. 3. **Angiography of a pseudoaneurysm of left VA at C_{II}—C_{III} vertebrae (indicated by the arrow) in frontal (a) and lateral (b) projections.**

R. Spetzler et al. [10] in 1987 reported on the possibility of an occipital-vertebral anastomosis to V_3 segment atlantic part of the VA at extravasal osteophytic compression of the vertebral artery at C_I—C_{II} level. S. Mabuchi et al. [11] in 1993 used radial artery graft from external carotid artery to atlantic part of vertebral artery for the first time for a case of dissection of the extracranial vertebral artery at C_I—C_{II} level. Finally, in 2013 K. Hisashi et al. [12] described three clinical cases of aneurysms of V_4 segment intracranial part in patients, who were subjected to the vertebrovertebral autovenous shunting from V_3 to V_4 segment of VA after resection of aneurysms in 2 cases and to the internal carotid vertebral shunting in 1 case using radial or occipital artery grafts.

We offer a rare option of surgical reconstruction of VA, including resection of the vertebral artery pseudoaneurysm at the boundary between the V_2 and V_3 segments, the vertebrovertebral autovenous shunting. The operation has been performed for the first time in the world in a patient after a stab wound on the left side of the neck and left vertebral artery pseudoaneurysm emergence at C_{II}—C_{III} level. We present our own clinical observation.



Fig. 4. **Projection of approach at the lateral surface of the neck left in the patient *Sh.***

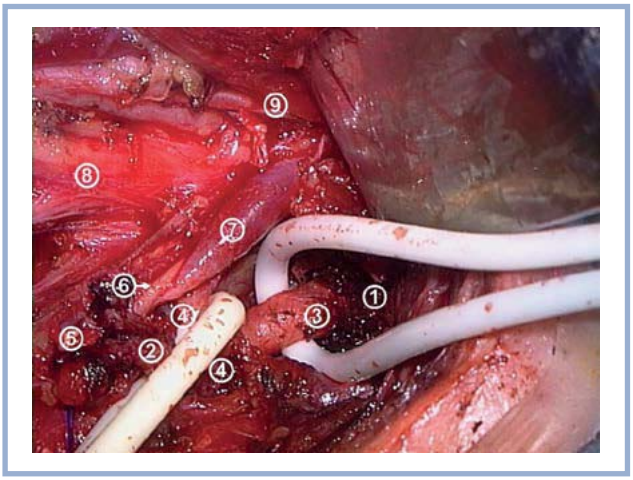

Fig. 5. **Mobilization of V_3 segment of the left VA.**

1 — projection of the transverse process of the C_I vertebra; 2 — projection of the C_{II} vertebral transverse process; 3 — VA; 4 —C_{II} branch of spinal nerve (kept with handles); 5 — the projection of a pseudoaneurysm; 6 — accessory nerve; 7 — IJV; 8 — internal carotid artery (ICA); 9 — the posterior belly of the digastric muscle.

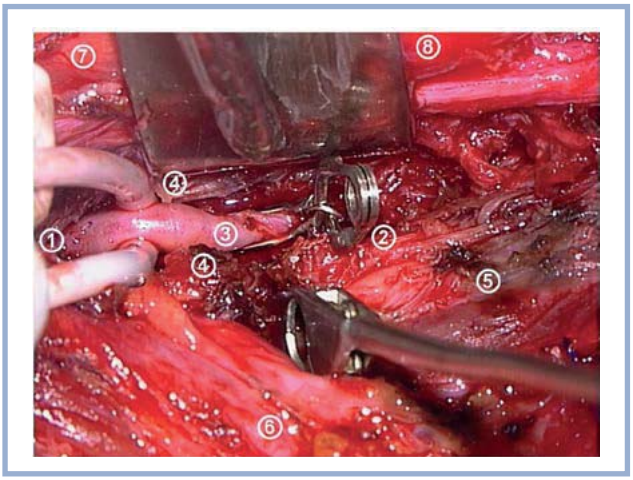

Fig. 6. **Mobilization of V_2 segment of left VA at C_{IV} vertebra.**

1 — projection of the transverse process of the C_V vertebra; 2 — projection of the C_{III} vertebral transverse process; 3 — VA (kept with handles); 4 — projection of excised anterior wall of the vertebral artery canal at C_{IV} vertebral transverse process; 5 — the projection of a pseudoaneurysm; 6 — IJV; 7 — CCA; 8 — ICA.

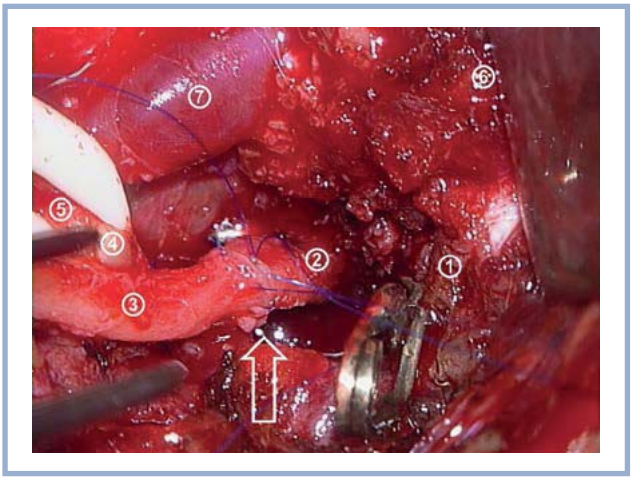

Fig. 7. **Distal V_3 vertebral artery autovenous bypass anastomosis at C_{II}—C_I vertebra level.**

1 — projection of C_I vertebral transverse process; 2 — VA; 3 — autogenous vein; 4 — C_{II} spinal nerve (kept with handles); 5 — projection of C_{II} vertebral transverse process; 6 — the posterior belly of the digastric muscle; 7 — IJV.

Case description

Patient *Sh.*, aged 39, received inpatient treatment at the Department of Neurosurgery, Central Military Clinical Hospital n.a. A.A. Vishnevsky, from June 2, 2014 to June 10, 2014 (medical record No. 15278). Medical record: trauma of February 21, 2014, unknown stabbed in the neck in the region of the upper third of the neck on the left. The patient received primary surgical wound cleaning at the place of residence and then inpatient treatment (February 25, 2014 to March 21, 2014) at the Department of Neurosurgery of Ambulance Hospital on the diagnosis of concomitant injury, stab wound to the neck on the left with injury to the external jugular vein, the sternocleidomastoid muscle, spinal cord with development of Brown-Sequard's syndrome on the left, disorders of pelvic organs of the central type, vertebral spinal cord injury, and right-sided anterior atlas subluxation. The subluxation was repositioned by hand according to the Ryushe-Guetter's method. Conservative therapy showed a positive effect: pain attenuated, hypoesthesia area regressed significantly, and the function of the pelvic organs restored. Continued conservative outpatient treatment had a positive effect: impaired sensitivity in the left extremities regressed fully, and grade of hypoesthesia in the right extremities decreased considerably. Magnetic resonance imaging of May 26, 2014 **(Fig. 1)** revealed focus of post traumatic myelopathy at C_{II}—C_{III} level (6×7×3 mm) and a 22×19×18 mm large lesion with clearly defined and irregular contours (pseudoaneurysm) was found in the

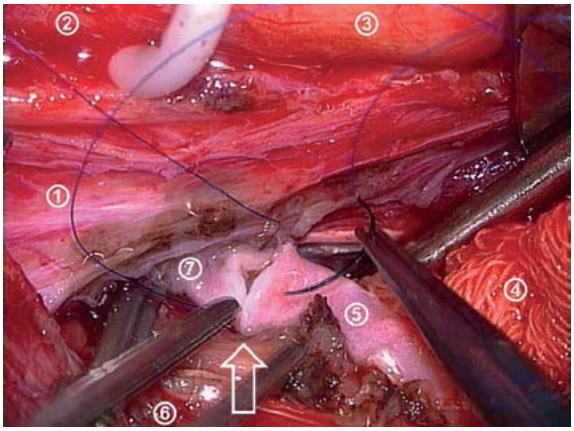

Fig. 8. **Proximal V_2 vertebral artery autovenous bypass anastomosis at C_{IV} vertebra level (indicated by the arrow).**

1 — projection of C_V vertebral transverse process; 2 — CCA; 3 — ICA; 4 — projection of C_{III} transverse process; 5 — autovenous bypass; 6 — IJV; 7 — VA.

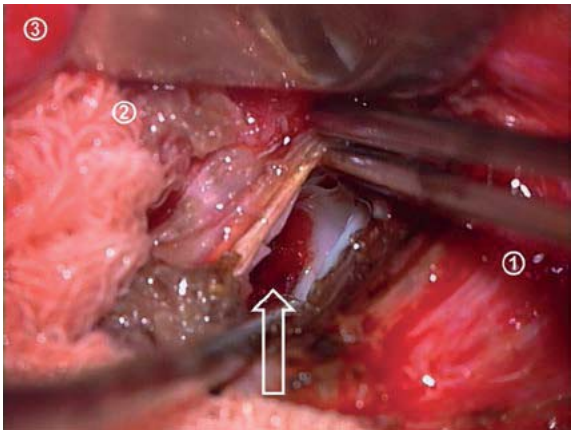

Fig. 10. **Dissection of pseudoaneurysm cavity of left VA (indicated by the arrow).**

1 — projection of C_I vertebral transverse process; 2 — projection of C_{IV} vertebral transverse process; 3 —CCA.

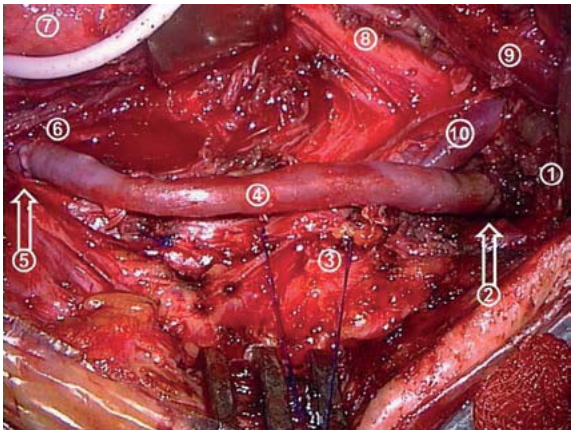

Fig. 9. **General illustration of proximal(V_2)-distal(V_3)vertebral autovenous bypass (indicated by the arrow.**

1 — projection of C_I vertebral transverse process; 2 — distal anastomosis (from V_3 of VA) of autovenous bypass; 3 — the projection of a pseudoaneurysm; 4 — autogenous vein; 5 — proximal anastomosis (from V_2 of VA) of autovenous bypass; 6 — projection of excised anterior wall of the vertebral artery canal at C_{IV} vertebral transverse process; 7 — CCA; 8 — ICA; 9 — the posterior belly of the digastric muscle; 10 — IJV.

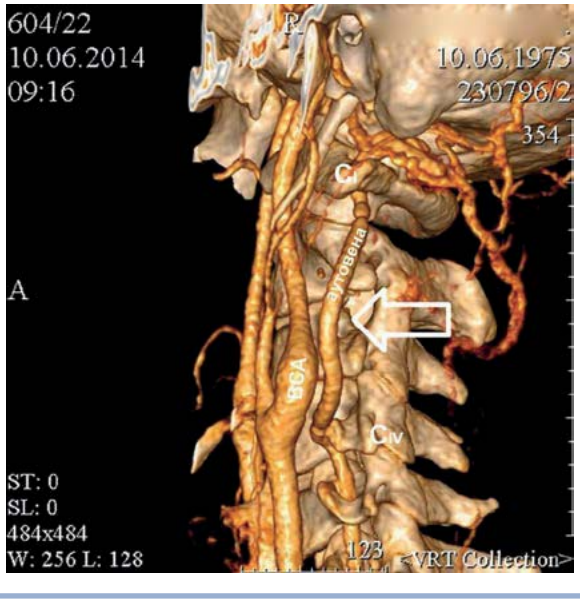

Fig. 11. **SCT angiography (the anastomosis site is indicated by the arrow).**

projection of the left vertebral artery at C_{II}—C_{III} level **(Fig. 2)**. The patient was hospitalized in a planned manner to perform angiographic examination and surgical treatment. The diagnosis of a pseudoaneurysm was confirmed by angiography of June 3, 2014 **(Fig. 3)**.

The surgical procedure. The anterolateral approach at the anterior surface of the sternocleidomastoid muscle to the vessel-nerve bundle of the neck was employed **(Fig. 4)**. After mobilization of the wounded internal jugular vein (IJV), the accessory nerve was divided distally, which crosses the internal jugular vein obliquely. In projection, the area of their crossing corresponds to the C_I vertebral transverse process, which was easily identified by palpation and was the upper point of approach. Afterwards, anterior bundles of the levator scapulae were divided and retracted between C_I—C_{II} vertebral transverse processes exposing the anterior C_{II} branch of the spinal nerve, which branches into two. Vertebral artery was identified under the spinal nerve and mobilized; anterior branch of C_{II} of the spinal nerve and VA were kept with handles **(Fig. 5)**.

At the second stage, VA below the C_{III} level was mobilized and the anterior wall at the transverse process of the C_{IV} vertebra was resected using pistol forceps and VA prior to exit from canal at C_V level was divided **(Fig. 6)**. Meanwhile, on the left leg great saphenous vein

with a length of 15 cm was detached and prepared for shunting.

At the third stage, distal vertebral artery was stitched, secured and cut after its exit from the C_{II} vertebral process and attached to preliminary prepared autovein by an end-to-end distal anastomosis **(Fig. 7)**. Blood flow re-establishing showed that the anastomosis was successful.

At the fourth stage vertebral artery proximal of its entry to the transverse process of the vertebra C_{III} was stitched, secured and cut and end-to-end anastomosis to the autovein was created **(Fig. 8)**. Blood flow was re-established and the anastomosis was successful **(Fig. 9)**. Bleeding was absent when the aneurysm cavity was opened **(Fig. 10)**.

The postoperative period was without complications. The wound healed by primary intention. Mild cerebral symptoms regressed and showed improvement of the neurological status, asthenia decreased.

In the early postoperative period spiral computed tomography (SCT) angiography (of June 6, 2014) demonstrated the region of a functioning autovenous shunt **(Fig. 11)**.

Conclusions

The methods of surgical management of arterial aneurisms of VA in V_2, which were previously proposed in the world literature, did not afford complete exclusion of the aneurysm from blood flow, since collateral arterial arcs connecting VA with the anterior spinal artery maintained that subsequently did not guarantee absence of various complications, including fatal.

We believe that the choice of the described surgical treatment tactics is the most successful due to that natural patency of VA restores and simultaneously functioning pseudoaneurysm is resected. Moreover, the surgical method demonstrates that the VA can be easily mobilized at any region of the V_2 segment with minimal traumatization of the long muscles of the neck. In the future, at spondylogenic lesion of VA technique can be easily applied to restore sufficient blood flow through the VA without the use of complex vascular reconstructions in the V_1 or V_3 vertebral artery segments.

REFERENCES

1. *Surgery of brain aneurysms*. Ed. by V.V. Krylov. Moscow: 2011,2;339-340.
2. Clinical neurology. Nikiforov A.S., Konovalov A.N., Gusev E.I. Volume III, Part 2. Moscow: Meditsina;125-160.
3. Berguer R. Function and Surgery of the Carotid and Vertebral Arteries. Philadelphia, PA USA: Lippincott Williams & Wilkins 2014;51-56.
4. Carney AL, Emanuele R, Anderson EM. Carotid Distal Vertebral Artery Bypass. Chicago: Medicom A-V Productions 1977.
5. Corkil G, French BN, Michas C, Cobb CA, Mims TJ. External carotid-vertebral artery anastomosis for vertebrobasilar insufficiency. *Surg Neurol.* 1977;7:109-115.
6. Carney AL, Anderson EM. Carotid distal vertebral artery bypass for carotid artery occlusion. *Clin EEG.* 1978;9:105-109.
7. George B, Laurian C. Surgical possibilities in the third portion of the vertebral artery (above C2). Anatomical study and report of a case of anastomosis between subclavian artery and vertebral artery at C1-C2 level. *Acta Neurochir Suppl.* (Wien). 1979;28(1):263-269. doi:10.1007/978-3-7091-4088-8_65.
8. Besson G, Vallee C, Mimossi N, Person H, Garre H. Les occlusions vertebrates segmentaires mal tolerees. Traitement par pontage veineux entre la carotide externe et le segment C1-C2 de l'artere vertebrate (2 observations). *Neurochirurgie.* 1981;27;59-64.
9. Carney AL, Anderson EM. Vertebral Artery Surgery: Historical Development, Basic Concepts of Brain Hemodynamics, and Clinical Experience of 102 Cases. *Advances in Neurology*. 1981;30:249-282.
10. Spetzler RF, Hadley MN, Martin NA, Hopkins LN, Carter LP, Budny J. Vertebrobasilar insufficiency. Part 1: Microsurgical treatment of extracranial vertebrobasilar disease. *J Neurosurg*. 1987;4:66(5):648-661. doi:10.3171/jns.1987.66.5.0648.
11. Mabuchi S, Kamiyama H, Abe H. Distal ligation and revascularization from external carotid to vertebral artery with radial artery graft for treatment of extracranial vertebral artery dissection. Report of a case. *Acta Neurochir.* (Wien). 1993;125(1-4):192-195. doi:10.1007/bf01401852.
12. Hisashi K, Rokuya T, Makoto K, Naoto I, Kosumo N, Nakao O, Yohei I, Takanori M, Shinichi O, Sumio E, Mika N, Masaaki H. Vertebral artery-to-vertebral artery bypass with interposed radial artery or occipital artery grafts: surgical technique and report of three cases. *World Neurosurgery*. 2014;81(1):202.e1-8. doi: 10.1016/j.wneu.2013.01.025.

Commentary

The presented clinical case of a pseudoaneurysm of the vertebral artery in a patient after a stab wound in the neck is a rare case, and the problem of surgical intervention on the vertebral artery is evident. In patients with aneurysms of VA, vertebrobasilar insufficiency takes the first position among the clinical manifestations characterized by vertigo, cerebellar ataxia, rarely lesion of VII—XII cranial nerves in pseudotumor course of the disease and vertebral basilar ischemia, usually arising as a result of microembolism of cerebral arteries.

The incidence of arterial aneurysms of VA, including the intracranial segments, is less than 1% of all aneurysms of brachiocephalic arteries. There are only a few publications in the literature on the surgical treatment of aneurysms of the extracranial vertebral artery segments and the surgical interventions described in the literature for pseudoaneurysms of the extracranial vertebral artery segments were applied with obligate use of traumatic approach to V3 segment of VA and did not afford exclusion of the aneurysm from the main blood circulation, which in turn contributed to risks of thromboembolic lesions of cerebral arteries.

The authors analyzed in detail the literature on this subject, the main surgical methods of reconstruction of vertebral artery have been described, and the advantages and disadvantages of different surgical techniques have been considered.

In this clinical case, for the first time a rare type of reconstruction of the vertebral artery with a pseudoaneurysm exclusion from the blood flow was proposed — the vertebrovertebral autovenous shunting distally and proximally to the lesion area using an autovenous graft with proximal and distal end-to-end anastomosis. There has been a convincing result in the early postoperative period confirmed by SCT angiography of brachiocephalic arteries and improvement of neurological symptoms in the patient.

The authors described in detail the operation procedure; the article is well illustrated with intraoperative photographs to facilitate the perception of the submitted material. The possibility of mobilizing the vertebral artery at V_2 segment using the anterolateral approach with minimum damage to the adjacent tissues has been shown. The undeniable advantage of the chosen technique of reconstruction is resection of the aneurysm from the main blood flow with elimination of the risk of thromboembolic complications in the brain in the postoperative period.

Lack of follow-up and individual observations do not allow to fully talk about the safety and efficacy of this procedure, as the long term evaluation of the results was not carried out.

Unfortunately, the authors did not focus on the anatomy of other brachiocephalic arteries; in particular, the efficiency of the circle of Willis in posterior and anterior circulation was not assessed. It is also not clear whether the examination of the brain was carried out to exclude post-ischemic changes in the vertebrobasilar basin, which could well be a partially cause of the indicated symptoms in patient. The description of the operation procedure does not contain the information on the anticoagulation protocol and antiplatelet therapy used in the perioperative period, the procedure of removing the forceps and measures for the prevention of distal embolism at re-establishing blood flow in the vertebral artery. Meanwhile, this information is very useful for practicing surgeons. All this does not diminish the practical relevance of the information provided.

The surgical procedure can also be useful in other types of lesions of vertebral arteries (spondylogenic compression, pathological deformation) and thereby indications to the autovenous grafts of extracranial vertebral artery may be extended. Without a doubt, this work is extremely useful and interesting for those engaged in reconstructive operations on the brachiocephalic arteries.

D.Yu. Usachev (Moscow, Russia)