doi: 10.17116/neiro201579375-79

Transarterial and transvenous embolization of deep binodal arteriovenous malformation of the brain

K.YU. ORLOV[1], V.V. BERESTOV[1]*, A.L. KRIVOSHAPKIN[1,2], V.A. PANARIN[1], D.S. KISLITSIN[1], A.V. GORBATYKH[1], T.S. SHAYAKHMETOV[1], P.O. SELEZNEV[1]

[1]Meshalkin Research Institute of Circulation Pathology, Ministry of Health of the Russian Federation, Novosibirsk, Russia; [2]Novosibirsk State Medical University, Ministry of Health of the Russian Federation, Novosibirsk, Russia

The multimodal approach to the treatment of arteriovenous malformations yields good results. However, small and deep malformations still pose a big problem for surgeons. Transvenous embolization was designed as an alternative to conventional transarterial embolization in cases when the latter is not available, while macrosurgery and radiosurgery are associated with high risk. In this study, we describe a case of surgical intervention through the transarterial and transvenous (for the first time in our clinic) approaches in a 41-year-old patient with a binodal malformation in the subcortical nuclei of the left hemisphere of the brain, which had previously become the source of massive parenchymal ventricular hemorrhage. Transarterial embolization of the thalamic node of the malformation was performed as the first step. After 6 months, transvenous embolization of the hypothalamic node of the malformations was performed as the second step. Successful operation was ensured by using a stable coaxial guiding catheter system with the maximum distal approach and intranidal positioning of a microcatheter with detachable distal portion upon temporary occlusion of afferent vessels of the malformations using a balloon catheter. The operation resulted in total thrombosis of the malformation. No perioperative complications were observed. Control examination in 6 months revealed no evidence of recanalization of the malformation. **Conclusions.** The transvenous approach can be successfully used in endovascular treatment of small and deep arteriovenous malformations with a single drainage vein, which are inaccessible to direct surgery. It can also be used when radiosurgery is associated with high risk in cases where transarterial embolization is infeasible.

Keywords: *arteriovenous malformation, transvenous embolization.*

Cerebral arteriovenous malformations (AVMs) are the most common congenital cerebrovascular diseases with high risk of intracranial hemorrhage (2% annually) and mortality (1—1.5%) [1]. Currently, there are three directions in the treatment of this disease: endovascular embolization, microsurgical removal, and radiosurgical therapy [2, 3]. The best results of its treatment with high level of radicality and low rate of disability are reported by neurosurgical centers that use a multimodal approach, combining all three treatments in different ratios to achieve total exclusion of malformations, even those difficult to treat, while minimizing risks and avoiding the limitations of each method.

Despite the significant advances in the treatment of this pathology, small and deep malformations pose a big problem for surgeons, since they are associated with the high risk of intraoperative and postoperative hemorrhage followed by the development of neurological deficit due to damage to functionally important areas.

Transvenous embolization was designed as an alternative to conventional transarterial embolization in cases when the latter is not available, while macrosurgery and radiosurgery are associated with high risk. The following is our first experience with this technique in the treatment of a complex deep binodal arteriovenous malformation.

Case Report

A 41-year-old male patient with long (about 20 years) history of headaches suffered a massive parenchymal and ventricular hemorrhage 2 months before hospitalization. At the time of admission to the Neurosurgical Center of the Novosibirsk Research Institute of Circulation Pathology, there were mild general cerebral (periodic moderate diffuse headache) and focal (4/5 right hemiparesis) symptoms.

According to MRI, the malformation in this patient was represented by a binodal vascular mass at the subcortical nuclei of the left hemisphere of the brain. One node was located in the left thalamus near to the lateral wall of the occipital horn of the left lateral ventricle and spread into the ventricular cavity. The second node was located in the left hypothalamus and spread into the cavity of the third ventricle. There were signs of past parenchymal and ventricular hemorrhage (hemosiderin deposition), which originated from the thalamic AVM node.

According to cerebral angiography (**Fig. 1a**, **b**), the malformation nodes were separated from each other and had separate blood supply with the same venous drainage. Thalamic AVM node (16×14×9 mm) was supplied from the anterior, posteromedial, and posterolateral choroidal arteries on the left, while hypothalamic node (12×8×7 mm) was supplied from thin perforating arteries of the terminal part of the communicating segment of the left internal carotid artery and the A1 segment of the left anterior cerebral artery.

The hypothalamic node was drained through the thalamostriate vein into the internal cerebral vein, which two thalamic veins draining the thalamic node of the malformation then flow into.

© Group of authors, 2015

*e-mail: vvberestov@gmail.com

Endovascular treatment was carried out in two stages. First, transarterial embolization of the thalamic node of the malformations was performed, since, according to MRI (Flair mode), it is this node that was the source of bleeding. Six months later, transvenous embolization of the hypothalamic node of the malformation was performed. Both operations were conducted under combined general anesthesia with tracheal intubation. Taking into account the use of balloon occlusion in the second surgery (to prevent thromboembolic complications), systemic anticoagulation was carried out using intravenous bolus heparin (5000 units) to achieve target activated clotting time (about 200 s).

Stage 1 **(Fig. 1)**. Two Envoy 6F guiding catheters (Codman, USA) were installed in the petrous segment of the left internal carotid artery and V3 segment of the left vertebral artery. Three afferent vessels of the malformation (anterior and posterior choroidal arteries) were catheterized alternately with Apollo microcatheters (ev3, USA). Thalamic node was intranidally injected with 3.1 ml of Onyx18 (ev3, USA) to achieve total exclusion of the thalamic AVM node, while maintaining the venous drainage of the hypothalamic node.

Due to the high risk of hyperinfusion intracranial hemorrhage, it was decided to embolize the hypothalamic node at the second stage. The postoperative period was uneventful, the functional outcome scored 1 point on the modified Rankin scale, which corresponds to the pre-operative level.

Stage 2 **(Fig. 2)**. Envoy 6F guiding catheter (Codman, USA) was installed in the petrous segment of the left internal carotid artery, and Chaperon 6F/5F MP /VTR coaxial catheter system (MicroVention, USA) was injected through the left jugular vein to the middle of the left transverse sinus (6F catheter) and then to the distal portion of the direct sinus (5F catheter). Then, Apollo microcatheter (ev3, USA) was placed intranidally to the hypothalamic node of the malformation through the Mirage guidewire (ev3, USA) via the inner cerebral vein and thalamostriate vein. In order to reduce blood flow in the AVM during the injection of the composition, temporary occlusion of A1 segment of the left anterior cerebral artery was performed using HyperGlide 4x15 balloon (ev3, USA) followed by occlusion of the communicating segment of the left internal carotid artery during 2 to 5 minutes. The total duration of occlusion was 15 min. The malformation was embolized totally by injecting a total of 2.5 ml of Onyx18.

Perioperative period was uneventful. Functional outcome corresponded to 1 point on the modified Rankin scale, just as before the operation.

Long-term result of treatment was evaluated 6 months after total AVM embolization. During this period, the patient reported significant decrease in the frequency and intensity of headaches. The functional outcome remained at the level of 1 point on the modified Rankin scale. MRI of the brain (**Fig. 3a, b)** and direct cerebral angiography (**Fig. 3c**) detected no signs of AVM functioning.

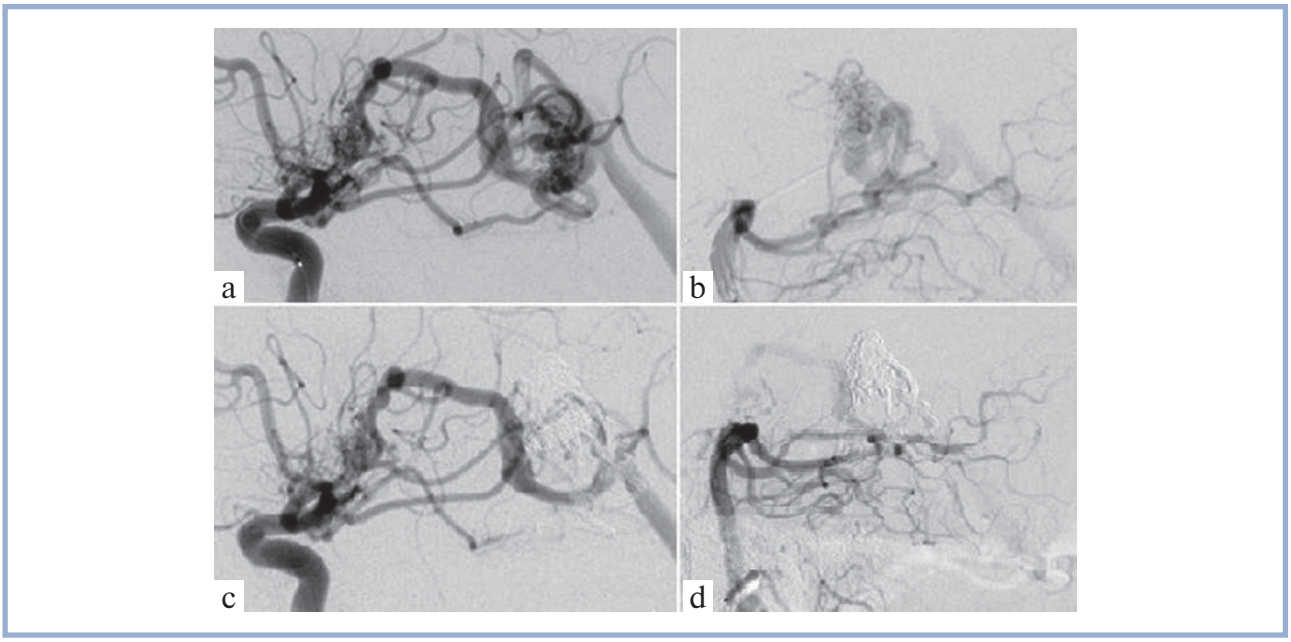

Fig. 1. **The carotid (a, b) and vertebral (c, d) angiograms in the arterial phase, lateral projection.**

a, b – angioarchitectonics of the thalamic node of the malformation with afferents from the left anterior and two posterior choroidal arteries and venous drainage through two hypertrophic thalamic veins into the vein of Galen; c, d – the stages of transarterial embolization of the thalamic node with its gradual total exclusion from the circulation.

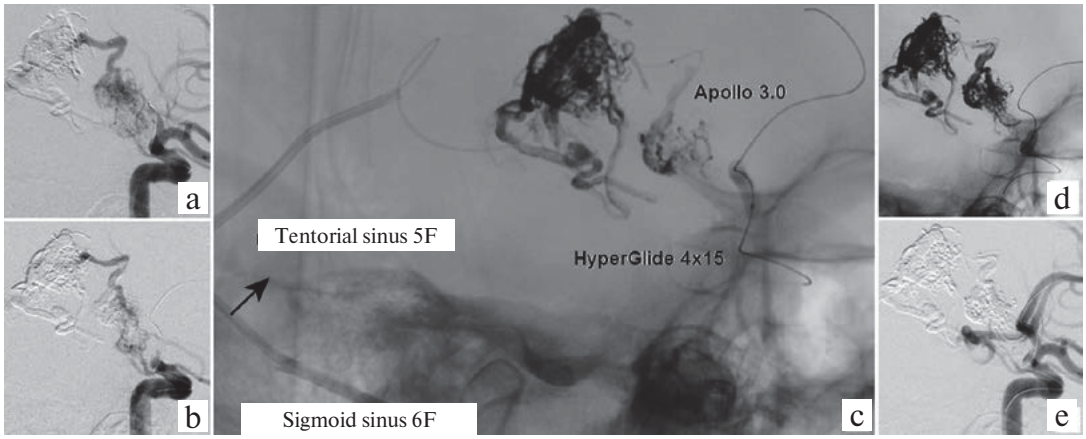

Fig. 2. **The carotid angiograms in the arterial phase, lateral and oblique projections.**

Stages of the transvenous embolization of hypothalamic node of the malformation; a – angioarchitectonics of the hypothalamic node at the time of installation of a microcatheter and balloon catheter; b – injection of 0.8 ml of embolic agents; c – positioning of the endovascular tools; d – injection of 1.2 ml of embolic agent, the balloon catheter is shifted to the communicating segment of the ICA; d – total closure of the AVM.

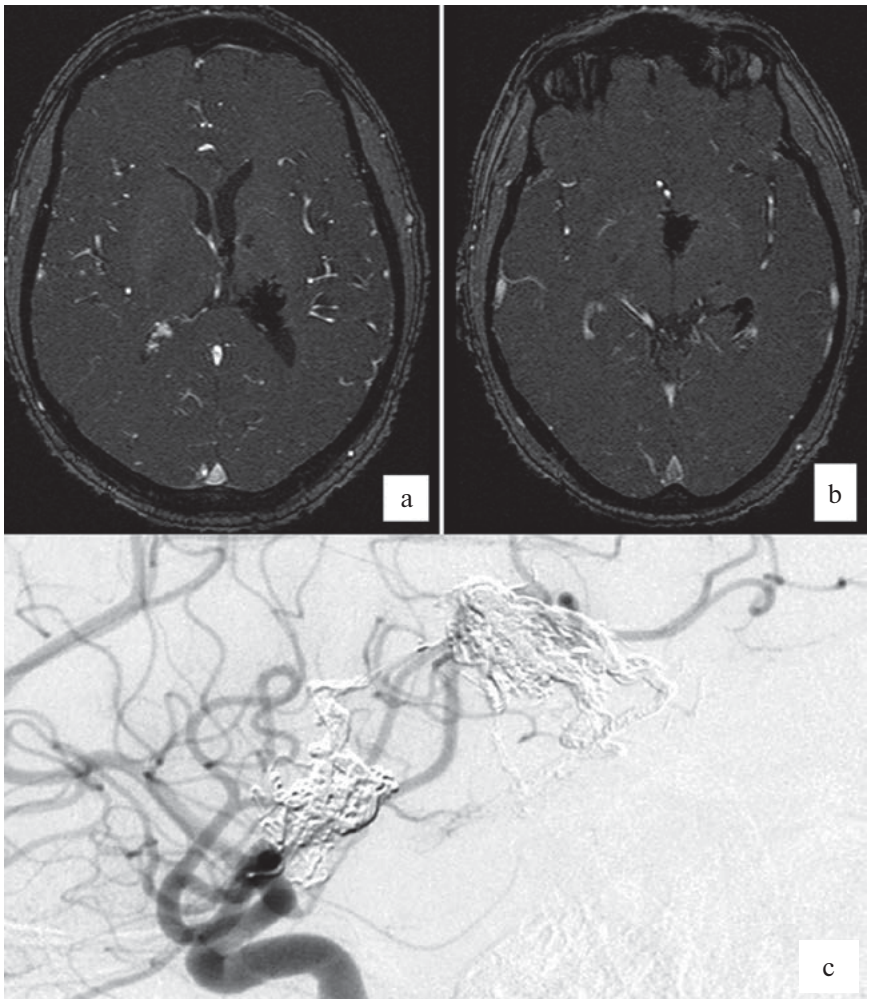

Fig. 3. **3DTOF MRI (1.5T) with intravenous injection of gadolinium in the capillary phase (a, b) and carotid angiogram in lateral projection (c) 6 months after the final embolization. There is no evidence of recanalization of the malformation.**

Discussion

The first mention of the use of venous approach for AVM embolization refers to 1999 and belongs to T. Massoud and G. Hademenos [4, 5]. They used transvenous approach for embolization of malformation models in pigs under controlled hypotension. In 2010, T. Nguyen et al. [6] published the results of their first successful transvenous embolization of ruptured malformations in a human. A year later, I. Kessler et al. [7] presented a series of five cases.

In 2013, Pereira et al. [8] used a balloon catheter in the transvenous embolization for temporary occlusion of malformation afferents. This allowed both preventing non-target embolization of the main vessels and reducing the blood flow through the AVM, facilitating penetration of adhesive composition into the node.

During the period from 01.01.2011 to 01.09.2013, a total of 321 embolization sessions in 173 patients with arteriovenous malformations of the brain were performed at the neurosurgical center of E.N. Meshalkin Novosibirsk Research Institute of Circulation Pathology with a total radicality of 67.1% [9]. The case reported in this paper is our first experience of the use of transvenous access to malformation node. Given a history of hemorrhage from the AVM in this patient, there was a significant risk of re-rupture, which is an absolute indication for surgical treatment. During the initial planning of its tactics, direct surgical intervention was obviously impossible due to AVM location. Radiosurgery was also considered to be unsuitable due to the large total size of malformation nodes (which exceeded the limit of this method of 3 cm) and high risk of damage to functionally important brain structures. Thus, endovascular technique was the method of choice in this case.

When closing the thalamic node of the AVM, transarterial embolization technique with Onyx was applied with intranidal catheterization of the AVM node, which enabled total exclusion of this node in one step.

In view of the fact that the hypothalamic portion of the malformation filled through thin perforants of the terminal part of the communicating segment and A1 segment of the left anterior cerebral artery, transarterial catheterization proved to be technically impossible, since the diameter of these afferents was below the minimum diameter of the catheter. However, the features of AVM angioarchitectonics (small-sized malformation node and draining through a single vein) enabled transvenous embolization with minimal risk to the patient. The use of coaxial system helped to achieve stable position of the working guiding catheter and improve the manageability of the microcatheter for safer and more efficient catheterization of the malformation draining vein. Additional conditions for total exclusion of AVM were provided using the technique of temporary balloon occlusion of the vessels carrying afferent branches during the injection of the adhesive composition.

Summary

Transvenous approach is rarely used in treatment of arteriovenous malformations and can not be recommended for routine use due to the high risk of hemorrhagic complications. However, there are situations where transvenous embolization has some chance of success. Indications for its use include small size of malformation node, single draining vein, infeasibility of catheterization of afferents of the malformation (small diameter and significant tortuosity), and high risks of microsurgery and radiosurgery.

REFERENCES

1. Al-Shahi R, Warlow C. A systematic review of the frequency and prognosis of arteriovenous malformations of the brain in adults. *Brain*. 2001;124(10):1900-1926.
2. Eliava Sh.Sh., Filatov Yu.M., Pilipenko Yu.V., Shekhtman O.D., Belousova O.B., Okishev D.N., Kheyreddin AS., Yakovlev S.B., Tseytlin A.M., Kaftanov A.N., Maryashev S.A., Nepomnyashchiy V.P. Mikrokhirurgicheskoe lechenie arteriovenoznykh mal'formatsiy golovnogo mozga v NII neirokhirurgii im. N.N. Burdenko (opyt poslednikh let). [Microsurgical treatment of arteriovenous malformations of the brain at the Burdenko Neurosurgical Institute (experience of recent years)] *Voprosy neirokhirurgii*. 2012;3:34-44.
3. Maryashev S.A., Golanov A.V., Konovalov A.N., Yakovlev S.B., Il'yalov S.R., Eliava Sh.Sh., Pronin I.N., Kostyuchenko V.V., Yakhina M.V., Gorlachev G.E. Radiokhirurgicheskoe obluchenie patsientov s arteriovenoznymi mal'formatsiyami golovnogo mozga na apparate «Gammanozh». [Radiosurgical treatment of patients with arteriovenous malformations of the brain using Gammanozh (Gamma Knife) instrument] *Voprosy neirokhirurgii*. 2013;5:16-29.
4. Massoud TF, Hademenos GJ. Transvenous retrograde nidus sclerotherapy under controlled hypotension (TRENSH): a newly proposed treatment for brain arteriovenous malformations-concepts and rationale. *Neurosurgery*. 1999;45(2):351-365.
5. Massoud TF. Transvenous Retrograde Nidus Sclerotherapy Under Controlled Hypotension (TRENSH): Hemodynamic Analysis and Concept Validation in a Pig Arteriovenous Malformation Model. *Neurosurgery*. 2013;73(2):332-343.
6. Nguyen TN, Chin LS, Souza R, Norbash AM. Transvenous embolization of a ruptured cerebral arteriovenous malformation with en-passage arterial supply: initial case report. *J Neurointerv Surg*. 2010;2(2):150-152. doi: 10.1136/jnis.2009.001289. Epub 2010 Mar 5.
7. Kessler I, Riva R, Ruggiero M, Manisor M, Al-Khawaldeh M, Mounayer C. Successful transvenous embolization of brain arteriovenous malformations using Onyx in five consecutive patients. *Neurosurgery*. 2011;69(1):184-193.
8. Pereira VM, Marcos-Gonzalez A, Radovanovic I, Bijlenga P, Narata AP, Moret J, Schaller K, Lovblad KO. Transvenous embolization of a ruptured deep cerebral arteriovenous malformation. A technical note. *Interventional Neuroradiology*. 2013;19(1):27-34.
9. Panarin V.A., Orlov K.Yu., Krivoshapkin A.L., Chupakhin A.P., Cherevko A.A., Khe A.K., Telegina N.Yu., Baranov V.I. Ispol'zovanie gidrodinamicheskikh raschetov v vybore stsenariya embolizatsii tserebral'noy arteriovenoznoy mal'formatsii c fistul'nym komponentom. [The use of hydrodynamic calculations in choosing the scenario of embolization of a cerebral arteriovenous malformation with a fistula component] *Patologiya krovoobrashcheniya i kardiokhirurgiya*. 2012;4:39-44.

Commentary

The authors presented a very interesting observation based on the use of combined approaches in the endovascular treatment of a deep binodal AVM. Application of the transarterial approach in the endovascular surgery of AVM is nowadays a standard approach in occlusion of malformation stroma. However, arteriovenous malformations often have multichannel blood supply with numerous small afferents, which are inaccessible to catheterization. Moreover, partial or subtotal embolization of AVM can lead to increased risk of rupture (re-rupture) of AVM.

The authors describe the technique of simultaneous multi-catheter method in AVM embolization (consisting of three vascular beds) with non-adhesive liquid composition. As a result, total embolization of the first AVM node (the source of hemorrhage) was achieved. Then, as a second stage, the authors used transvenous approach to the stroma of the second (silent) AVM node and conducted its total embolization, while afferents were temporarily occluded with a balloon catheter. As a result, the authors succeeded in two-staged radical treatment of the complex AVM using endovascular technique.

It should be noted that the second stage of surgical treatment was associated with high risk of intraoperative and postoperative complications, especially if total occlusion of AVM node had not been achieved in the case of unintended occlusion of a single draining vein. In this situation, radiosurgical treatment might be the method of choice as the second phase, since it is associated with lower risk of complications. At the same time, this work demonstrates the capabilities of modern endovascular neurosurgery in the treatment of AVM, while the absence of complications is indicative of high professional level of the surgeon and the entire medical team.

However, this technique can not be recommended as the routine method of AVM embolization. Implementation of this manipulation is justified only in rare cases, in accordance with the features of AVM angioarchitectonics described by the authors, at a specialized clinic.

S.R. Arustamyan (Moscow, Russia)