doi: 10.17116/neiro20157933-11

High-Resolution 3D Time-of-Flight MR Angiography in Imaging of Lentriculostriate Arteries in Patients with Insular Gliomas

A.E. BYKANOV*, D.I. PITSKHELAURI, I.N. PRONIN, A.S. TONOYAN, V.N. KORNIENKO, N.E. ZAKHAROVA, A.M. TURKIN, A.Z. SANIKIDZE, M.A. SHKARUBO, A.M. SHKATOVA, E.I. SHULTS

Burdenko Neurosurgical Institute, Moscow, Russia

Objective. To evaluate the effectiveness of high-resolution time-of-flight (3D-TOF) magnetic resonance angiography (MRA) in imaging the medial and lateral lenticulostriate arteries and to determine their relationship to the tumor edge in patients with insular gliomas. **Materials and Methods.** 3D-TOF MR angiography data were analyzed in 20 patients with primarily diagnosed cerebral gliomas involving the insula. All the patients underwent non-contrast enhanced 3D-TOF MR angiography. In six cases, 3D-TOF MRA was performed before and after contrast enhancement. **Results.** 3D-TOF angiography performed before intravenous contrast injection made it possible to visualize the medial lenticulostriate arteries in 19 patients (95% of all cases) and lateral lenticulostriate arteries in 18 patients (90% of all cases). Contrast-enhanced 3D-TOF angiography allows better imaging of both the proximal and distal segments of lenticulostriate arteries. Three variants of the relationship between the tumor and lenticulostriate arteries were identified, namely, variant I: the tumor grew over the arteries without displacing them in 2 (10%) cases; variant II: the tumor caused medial displacement of arteries without growing over them in 11 (55%) cases; variant III: the tumor partially grew over and displaced arteries in 2 (10%) cases. In 25% of cases (5 patients), the tumor was poorly visualized on 3D-TOF MR angiograms because their signal characteristics did not differ from those of the medulla (the tumor tissue was T1 isointense). As a result, it was impossible to determine the relationship between the tumor and lenticulostriate arteries. **Conclusions.** High-resolution time-of-flight MR angiography can be recommended for preoperative imaging of lenticulostriate arteries to plan the extent of neurosurgical resection in patients with glial tumors of the insular lobe.

Keywords: *insular lobe gliomas, lenticulostriate arteries, 3D-TOF MR angiography.*

Glial tumors account for up to 40—50% of all the primary cerebral tumors, with the significant number of them (25% of all the low-grade and 10% of high-grade malignant tumors) involving the insular lobe or originating from it [1].

The increase in the extent of the glioma resection has been reliably shown to directly correlate with the extension of patient's life [2—4]. Yet, surgical treatment of gliomas of this localization remains one of the most challenging tasks of neurosurgery, which is related to the anatomic features of this brain region. The tumor often grows beyond the insular lobe, extending to the frontal and temporal lobes and affecting the anterior perforated substance along with perforating arteries in it. A surgeon has to work in the area surrounded by important opercular regions of the brain (especially in the dominant hemisphere) and penetrate into the insula between the branches of the M2 segment of the middle cerebral artery, whereas the lenticulostriate arteries (LSA), the basal ganglia they carry blood to, and the internal capsule are the medial resection border. All the above anatomic features make radical resection of a glioma without subsequent neurological deficit rather difficult.

As virtually all the severe postoperative complications in patients with insular gliomas are related to the damage to the LSA (permanent hemiparesis caused by ischemic lesion of the internal capsule) [5—9], preoperative detection of their intraparenchymatous growth and their location in relation to the tumor becomes especially important.

The goal of the study was to evaluate the effect of high-resolution time-of-flight (3D-TOF) magnetic resonance angiography (MRA) in imaging of the medial and lateral LSA and their relationship with the tumor edge in patients with insular gliomas.

Material and methods

The study involved 20 patients with primary insular lobe gliomas who had not been subjected to prior surgical treatment, chemotherapy, and radiation therapy. In all the cases, the T1-weighted scans showed no accumulation of Gd-containing contrast by the tumor. Magnetic resonance imaging (MRI) was performed according to the following protocol: T2 and T2-FLAIR-weighted images, diffusion-weighted T1 images before intravenous (i/v) contrast enhancement and T1 images after it. All the patients underwent non-contrast enhanced 3D-TOF MRA; in 6 cases the patients underwent it before and after contrast enhancement. 3D-TOF MRA was performed in the transverse plane using the gradient echo pulse sequence, with the following parameters: TR/19 ms, TE/1 ms, TE (out of phase)/3.4 ms, flip angle — 18°, FOV — 22 mm, the matrix — 640×352 mm, scan thickness — 1.2 mm; ZIP-1024, resolution 0.5×0.5×1.2 mm with subsequent reconstruction of

© Group of authors, 2015

e-mail: ABykanov@nsi.ru

medial and lateral LSA in the maximal intensity projection (MIP) at a customized workstation. Non-contrast enhanced 3D-TOF MRA was performed for 14 (70%) patients; for 6 (30%) patients MRA was performed before and after contrast enhancement. The total duration of MRI was 25—30 min. The data of high-resolution 3D-TOF MRA before and after i/v contrasting were analyzed in order to estimate the degree of visualization of the medial and lateral LSA and to determine their relationship with the tumor tissue edge.

Results

According to the results obtained, high-resolution 3D-TOF MRA allowed detection of both medial and lateral LSA in the impaired brain hemisphere in most cases. The use of 3D-TOF MRA before i/v contrasting made it possible to visualize the medial LSA in 19 (95%) patients and lateral LSA in 18 (90%) patients. Small LSA branches were better visualized in the patients for whom 3D-TOF MRA was performed both before and after i/v contrasting compared to those for whom angiography was performed only before i/v contrasting. Contrast enhancement improved visualization of the most distal sections of those arteries. The entire course of the arteries was visualized more clearly, as well as the details of their location in relation to the tumor.

The major effect of this program is T1-wieghtedness; since only gliomas that did not accumulate Gd-containing contrast were included in the study (most gliomas affecting the insular lobe have a low degree of malignancy and do not accumulate contrast [1]), i/v contrasting did not improve tumor visualization in 3D-TOF MRA. This was the reason why we were able to determine the relationship of LSA and the tumor only for 15 (75%) patients, as the tumor tissue was hypointensive in the T1-weighted MRI. Tumor growth over the LSA without artery dislocation was revealed in 2 (10%) patients (**Fig. 1b**). In 11 (55%) cases, the LSA were displaced in the medial direction and were located along the medial edge of the tumor (**Fig. 2b**), while in 2 (10%) cases the tumor partly grew over and displaced the arteries (**Fig. 3b**).

Intraoperative confirmation of the 3D-TOF MRA data was clearly demonstrated in 15 cases. In 5 (25%) patients the tumor was poorly visualized in 3D-TOF MRA, as their signal characteristics did not differ from those of the medulla (the tumor tissue was T1 isointense). As a result, we were unable to determine the relationship between the tumor and the LSA, so the angiogram data were not clinically significant, as only artery dislocation was identified in the tumor growth zone, compared to the opposite side.

Postoperative 3D-TOF MRA performed for 6 patients confirmed the LSA intactness. Clinically the patients did not demonstrate any increase in the neurological deficit in the postoperative period.

Thus, three variants of the relationship between the tumor and the LSA were identified in the material under study: I — the tumor grew over the arteries without displacing them (**Fig. 1b**); II — the tumor caused medial displacement of arteries without growing over them (**Fig. 2b**); III— the tumor partially grew over and displaced the arteries (**Fig. 3b**).

Description of clinical cases

Clinical case 1. **Growth of the tumor over the LSA (variant I)**

A 22 year-old male: among the clinical manifestations, paroxysmal symptoms prevail presenting as generalized and partial seizures with oral automatism ("smacking"), loss of consciousness, and its gradual recovery. According to the brain MRI, a large cerebral tumor of the right insular, frontal, and temporal lobes was revealed (Yaşargil type 5B), not accumulating contrast and also proliferating to the anterior perforated substance (**Fig. 1a, b**). According to 3D-TOF MRA, the tumor tissue enveloped both the medial and lateral LSA (the arteries were included in the tumor edge rather than being located on it). The tumor was resected at the Burdenko Neurosurgical Institute. We were unable to visualize the proximal part of the arteries, as they were ingrown by the tumor and the risk of their damaging the arteries when attempting to isolate them from the tumor tissue was significant. The morphological diagnosis was grade II diffuse astrocytoma. No motor impairments were detected in the early postoperative period; however, the postoperative MRI identified the remaining part of the tumor in the area of the limen insulae and in the anterior perforated substance.

Clinical case 2. **LSA without involvement into the tumor tissue (variant II)**

A 35-year-old female: about two years before, the patient started to smell unfavorable odor for about 1—2 min, followed by seizures accompanied by loss of consciousness. The brain MRI revealed a tumor in the right insular lobe, spreading into the pole of the temporal lobe and the basal regions of the frontal lobe, not accumulating contrast (Yaşargil type 5A) **(Fig. 2)**. The tumor was resected at the Burdenko Neurosurgical Institute. The morphological diagnosis was grade II diffuse astrocytoma. The patient's neurological status after the surgery remained the same.

Clinical case 3. **Impairment of the proximal zone of the LSA (variant III)**

A 37-year-old female: the clinical symptoms included generalized and partial paroxysms with loss of consciousness for 30 min, feeling of numbness in the right arm and speech impairments. The brain MRI (**Fig. 3a**) revealed a brain tumor of the left insular lobe and the left temporal lobe (Yaşargil type 5A), which did not accumulate contrast. According to the 3D-TOF

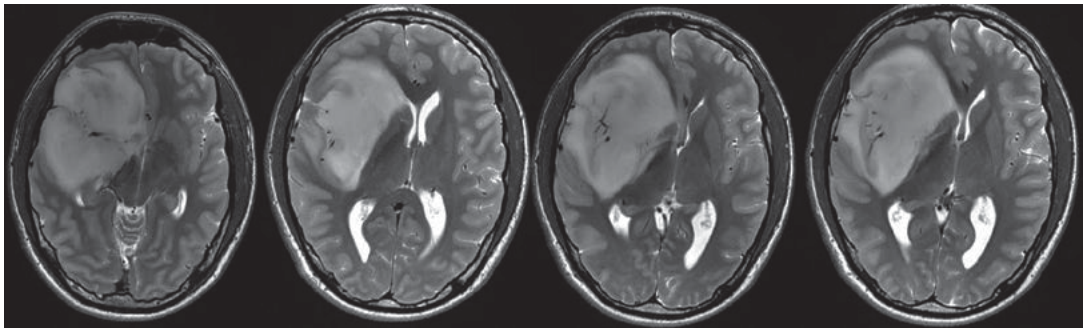

a

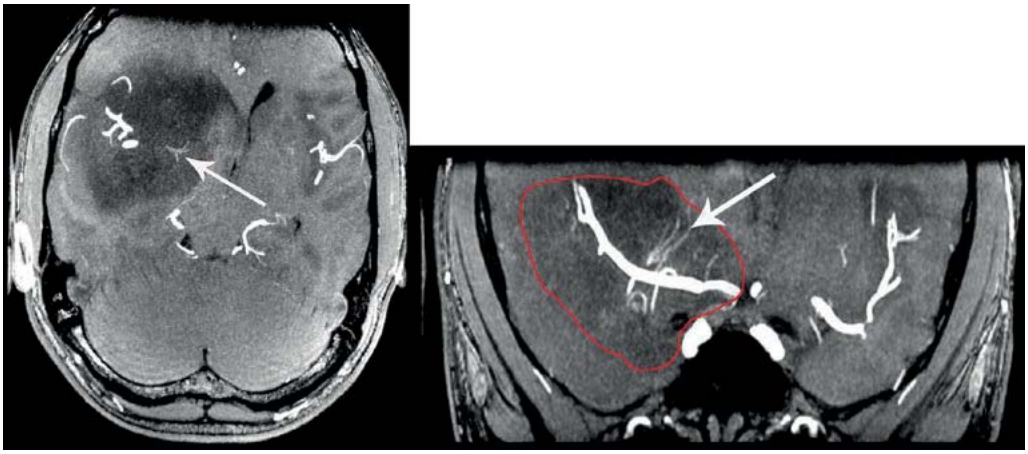

b

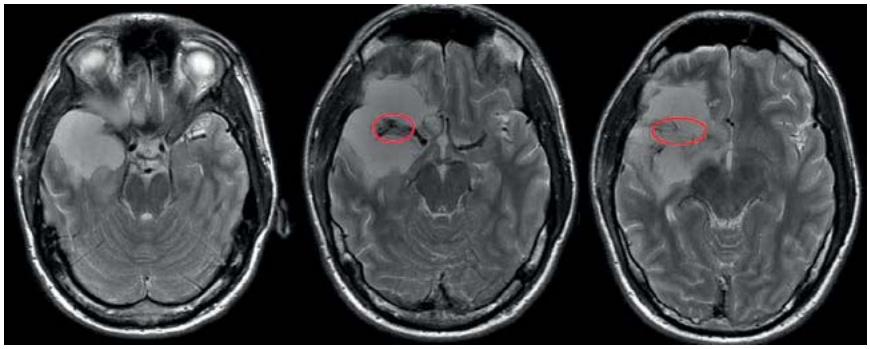

c

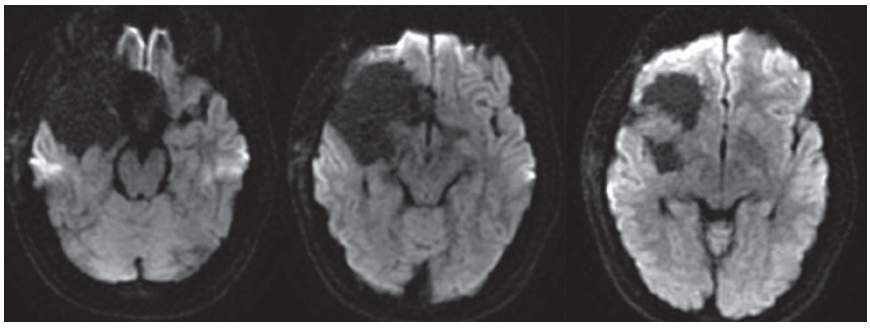

d

Fig. 1. **Clinical case 1. Tumor growth around LSA (variant I).**

a — preoperative T2-weighted MRI (4 scans at different levels): a large intracerebral tumor of the right insular, frontal, and temporal lobes (Yaşargil type 5B) with hyperintense signal; b —3D-TOF reformatted MRA images after i/v contrast enhancement in the coronal and axial projections: tumor tissue involving the medial and lateral LSA (arrows) (the tumor edge is shown with red line); c — postoperative T2-weighted MRI (3 scans at different levels): subtotal resection of the tumor (the tumor remnants are shown in red); d — postoperative diffusion-weighted images (3 scans at different levels) without postoperative ischemic lesions in the surgical area.

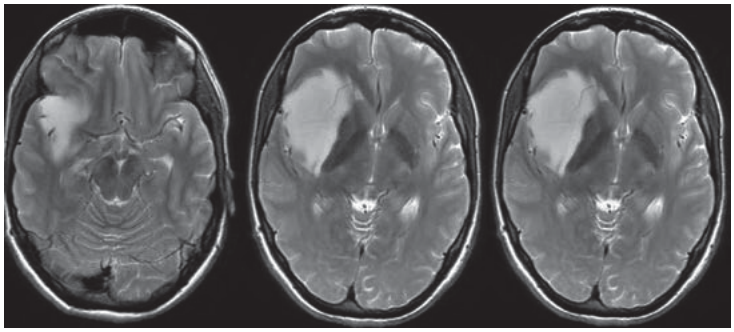

a

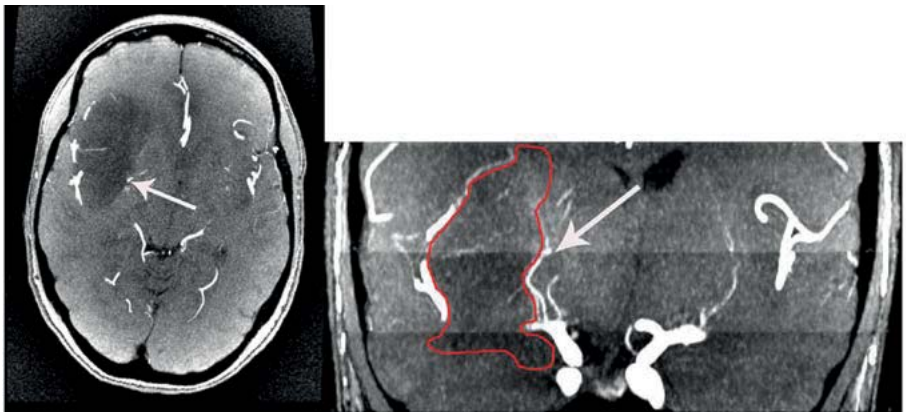

b

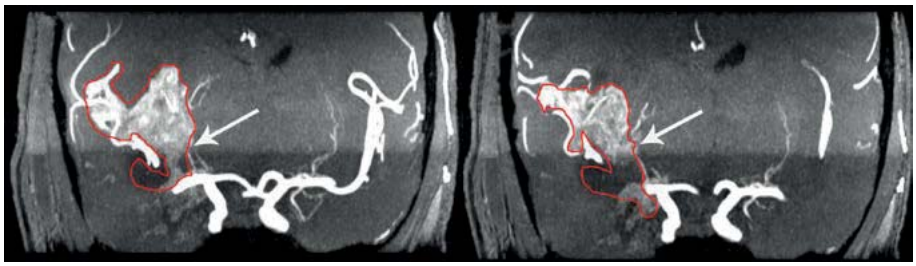

c

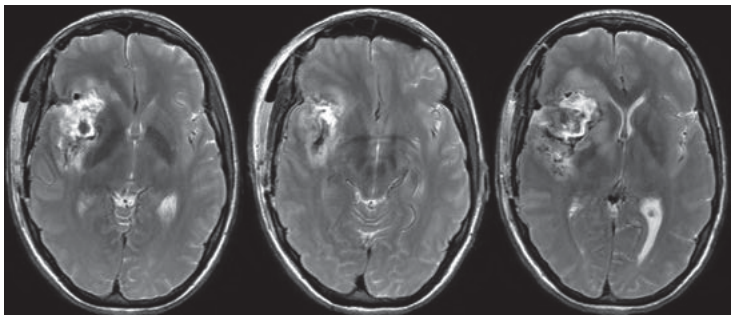

d

Fig. 2. **Clinical case 2: LSA not involved in tumor (variant II).**

a — A T2-weighted MRI image (3 scans at different levels): a brain tumor of the right insular lobe insignificantly spreading to the temporal pole and the basal portions of the frontal lobe (Yaşargil type 5A) with hyperintense MR signal; b — 3D-TOF MRA (axial and frontal reformatted images): LSA position along the medial tumor edge (shown with a red line) not involved into the tumor tissue (arrow), a tumor with hypointense MR signal; c, d, e — 3D-TOF (c), as well as brain MRI 36 h after the surgery in T2-weighted (d) and diffusion images (e): intactness of LSA in subtotal resection of the tumor (an MR signal from the postoperative cavity in the remote tumor projection with a highly intensive signal as 3D-TOF due to the paramagnetic effect of methemoglobin; the DWI images show local hyperintense micro-zones along the resection edge — acute ischemia foci); f — an intraoperative image.

Footnote. M1 — the M1 segment of the middle cerebral artery. LSA — lenticulostriate arteries.

Fig. 2 is continued on the next page

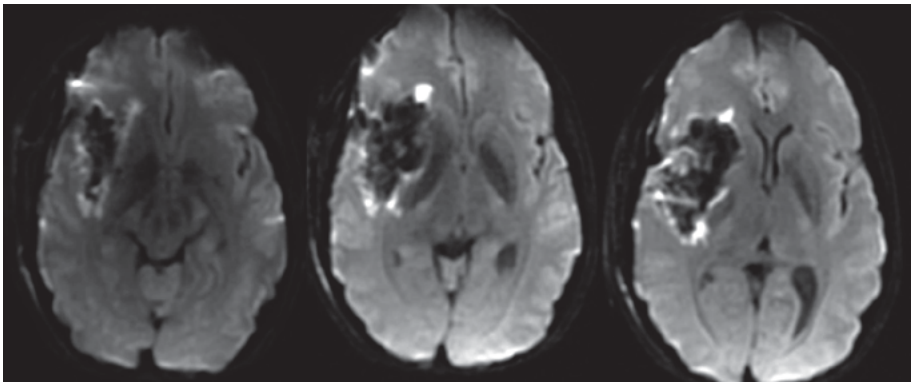

e



f

Fig. 2. *(continued).*

MRA, the LSA were located along the medial edge of the tumor; however, some lateral arteries were included in the tumor tissue. Since the tumor was localized in the hemisphere dominant for speech, the patient was operated on using the 'craniotomy in the conscious patient' method. When the tumor was resected from the limen insulae and the adjacent anterior perforated substance, the lateral LSA was damaged in the region of its branching from the M1 segment. As a result, the patient stopped following motor instructions with her right limbs, due to which the tumor resection was stopped.

Motor impairments started in the early postoperative period (right hemiparesis up to grade 2). The diffusion MRI of the brain conducted on the first day after the surgery allowed visualization of ischemic impairment in the area of basal ganglia and the adjacent departments of the internal capsule on the left side.

Clinical case 4. **Impairment of the distal section of LSA (variant I)**

A 41-year-old male: the man suffered from complex partial seizures, which occurred up to 6 times per month. The brain MRI showed a cerebral tumor of the left insular and temporal lobes, which did not accumulate contrast (Yaşargil type 5A). Preoperative 3D-TOF MRA showed displacement of the LSA in the medial direction without tumor tissue ingrowth (variant I). We were able to identify these arteries and to preserve their proximal portion during the surgery at the stage of dissecting the M1 segment of the middle cerebral artery and extracting the tumor from limen insulae. However, two small arteries were damaged and subsequently coagulated at the final stage of the surgery (extraction of the medial part of the tumor mass, along which these arteries were located according to 3D-TOF MRA).

In the early postoperative period, the patient had right-sided hemiparesis (up to grade 3). Diffusion MRI of the brain performed within 24 h after the surgery showed ischemic lesions along the medial edge of the resected tumor bed and in the posterior limb of the internal capsule.

Discussion

Saving LSA remains one of the challenges in surgery of the insular lobe. Being branches of the M1 segment of the middle cerebral artery, these arteries perforate the central and lateral parts of the anterior perforated substance and supply blood to the basal ganglia and the internal capsule. Although the number of LSAs varies from 5 to 24 [10], occlusion even of one artery may result in extensive infarction in the area of subcortical ganglia and the internal capsule [11]. In most cases, due to the extensive effect caused by the tumor mass, LSAs get displaced in the medial direction to form an arch-like

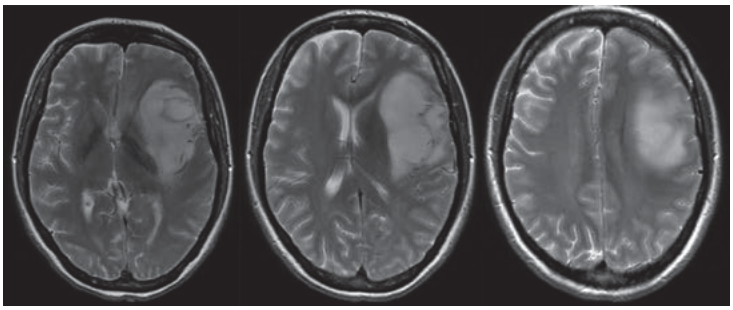

a

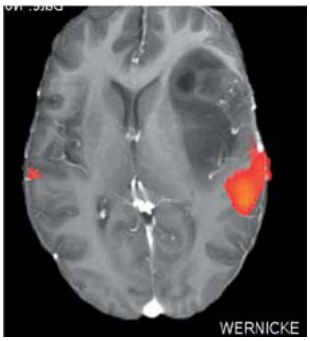

b

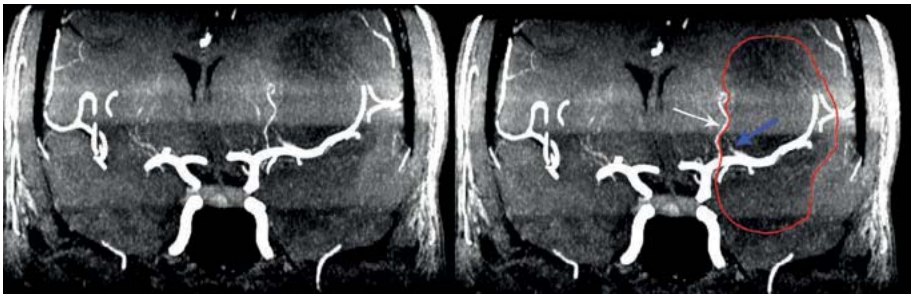

c

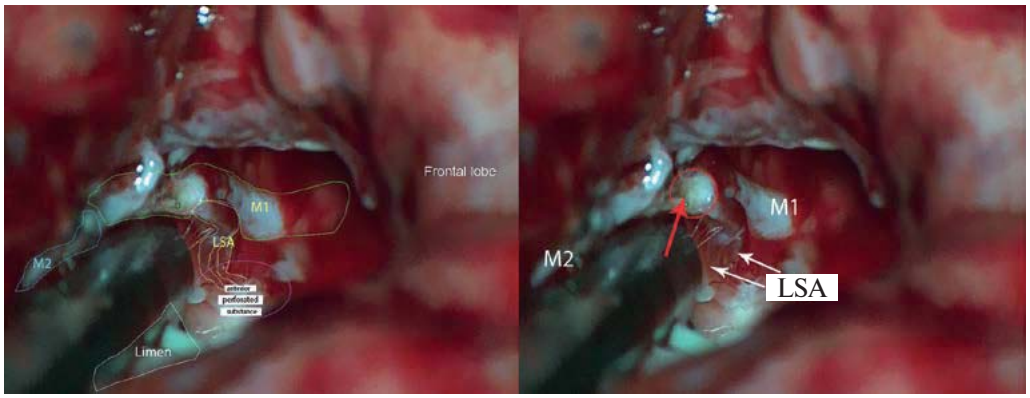

d

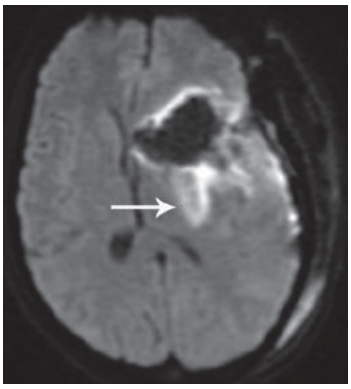

e

Fig. 3. **Clinical case 3: impairment of a proximal segment of LSA (variant III).**

a — cerebral MRI (T2-weighted image) in the axial projection before surgery (3 scans at different levels): an intracerebral tumor of the left temporal-frontal area with hyperintense MR signal, b — functional MRI with mapping of speech areas: on the left — Wernicke center, the typical location (red color) and at a certain distance from the posterior pole of the tumor; c — 3D-TOF MRA (frontal reformatted images): medial LSA (white arrow) are located along the medial edge of the tumor (the edges of the tumor tissue are shown in red), lateral LSA (blue arrow) are partially involved into the tumor tissue; d — intraoperative image (the red arrow indicates the site of coagulation of the lateral LSA): LSA, anterior perforated substance, limen —limen insulae; e — postoperative diffusion MRI of the brain: an ischemic stroke in the projection of the posterior limb of the internal capsule (arrow).

Footnote. M1 and M2 — M1 segments of the middle cerebral artery.

bend along the medial edge of the tumor (**Fig. 4b**), which we observed in 11 (55%) cases.

LSA impairment is referred to as the main cause of persistent neurological deficit in virtually all the known studies devoted to the surgery of insular gliomas [5—9, 12]. Intraoperative tracking of the LSA is quite difficult, especially when the transcortical access to the insular lobe is used. A number of authors have offered to use a micro-Doppler sensor to ensure intraoperative identification of LSA localization; however, this method is not used in practice due to technical challenges it involves [11].

In order to identify the plane in which a LSA diverged, M. Yaşargil et al. [13], followed by F. Lang et al. [8] (advocates of the transsylvian approach to the insular lobe) suggested dissecting the horizontal portion of the Sylvian fissure as far as the first (counting from the approach) perforating artery diverging from the M1 segment of the middle cerebral artery. As a result, an essential landmark emerged: the vertical plane transecting the first lateral LSA, determining the medial border of the tumor resection.

In surgical practice, even in the case of maximal proximal dissection of the stem of the middle cerebral artery until the first lateral LSA diverges, it is very difficult to track the subsequent position of the arteries and the site of their inflow into the anterior perforated substance due to small diameter (about 1 mm) and variability of the number of arteries. Therefore, originally M. Yaşargil et al., followed by M. Simon et al. [15] and H. Duffau et al. [5], suggested leaving a small portion of the tumor mass in the area of the anterior perforated substance to prevent damage to the perforating arteries.

To estimate the LSA course, M. Yaşargil et al. [13] suggested preoperative carotid artery angiography for all the patients having impairment of the insular lobe. For the same purpose, H. Duffau et al. [5] used a non-invasive approach, CT angiography, for two patients in the series of cases they observed. However, the resolution power of the method proved to be insufficient for the task to be solved.

To reduce the probability of transecting the LSA during tumor resection, F. Lang et al. [8] performed MRI in standard modes before the operation and thoroughly analyzed the ratio of these arteries (the flow void effect in the T2-weighted image was the absence of signal from the arteries in this imaging, i.e. the arteries looked like black dots) and the tumor and planned the amount of surgical intervention accordingly.

Y. Moshel et al. [16] obtained interesting results by comparing preoperative MRI and carotid angiography. According to their findings, determining displacement of the LSA by the angiography results and overlapping these data on the preoperative MRI scans may be of help in predicting the degree of tumor invasion in the LSA. In accordance with this, the authors identified two types of insular tumors: the first type of tumors displaces the LSA medially, with LSA not involved into the tumor tissue and located on the border of the cerebral tissue and the tumor (the presence of a clear medial border of the tumor according to the T2-weighted MRI images is characteristic of this type); growth of the second type of tumors located both medially and laterally does not result in medial displacement of perforating arteries (these tumors normally do not have clear borders on T2-weighted MRI images). The authors arrived at a conclusion that, according to carotid angiography results, the patients having large tumors that are located more laterally than the LSA and cause displacement of the arteries in the medial direction proved to be the most suitable candidates for total resection of insular tumors without further development of neurological deficit.

In addition to CT angiography, 3D-TOF MRA is a non-invasive method allowing the position of the LSA in relation to the tumor tissue edge. According to R. Saito et al. [17], preoperative imaging of LSA allows one to reduce the risk of intraoperative damage to these structures and enhance the degree of tumor resection. However, the authors did not report the number of the patients involved in the study and only described three clinical cases of using the technique. We have not found any other studies analyzing the use of high-resolution MRA in imaging of medial and lateral LSAs in patients with insular gliomas (including intraoperative confirmation of the angiography results).

Our study demonstrated that performing high-resolution 3D-TOF MRA after i/v injection of Gd-containing contrast allowed imaging of both medial and lateral LSA in patients with insular gliomas in 100% cases, whereas angiography conducted before contrast enhancement revealed medial LSA in 95% of cases and lateral LSA in 90% of cases. In addition, contrast enhancement allows better imaging of both the proximal and distal segments of the LSA. High-resolution 3D-TOF MRA allowed one to clearly determine the ratio between LSA and insular gliomas not accumulating contrast in 75% of cases. In the remaining 25% of cases, 3D-TOF MRA did not allow imaging of a clear border between the brain tissue and the tumor tissue, thus making it impossible to detect the course of the LSA in relation to the tumor edge.

Thus, in cases with hypointensive T1-weighted images of gliomas, 3D-TOF MRA is a highly informative method of LSA identification with three possible variants of their location in relation to the tumor tissue.

However, the weak point of this study is the fact that we did not use 3DT2, 3DT2-FLAIR pulse sequences in our protocol of cerebral MRI, which did not allow us to compare them in 3D-TOF MRA. In the future, this may possibly solve the problem of the absence of signal differences between the brain tissue and the tumor tissue that is isointentive in the T1-weighted images (which was so rare and constituted ¼ of all the cases) but hyperintensive in the T2-weighted images.

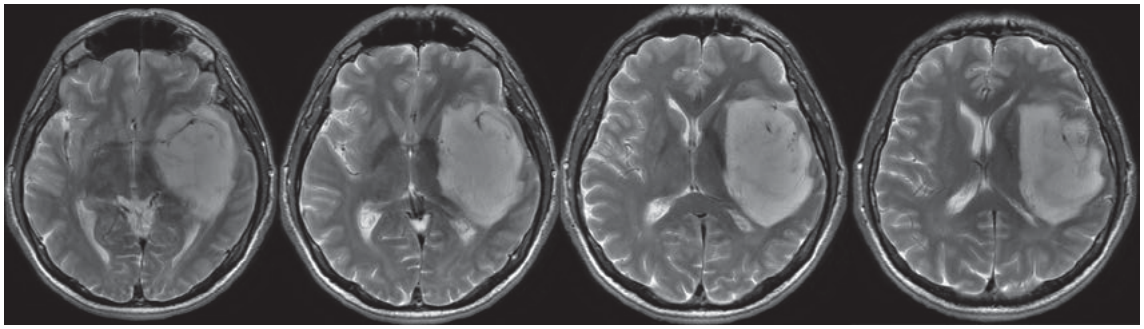

a

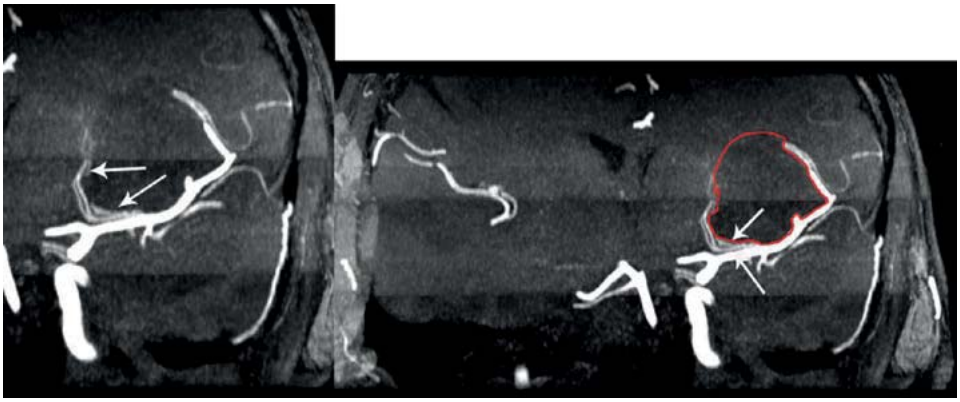

b

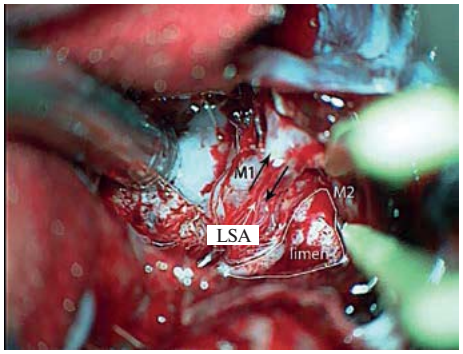

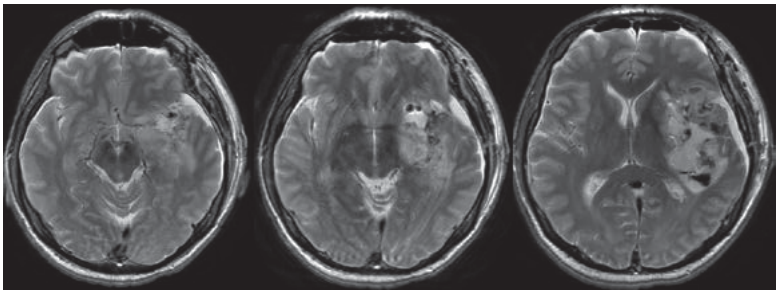

c d

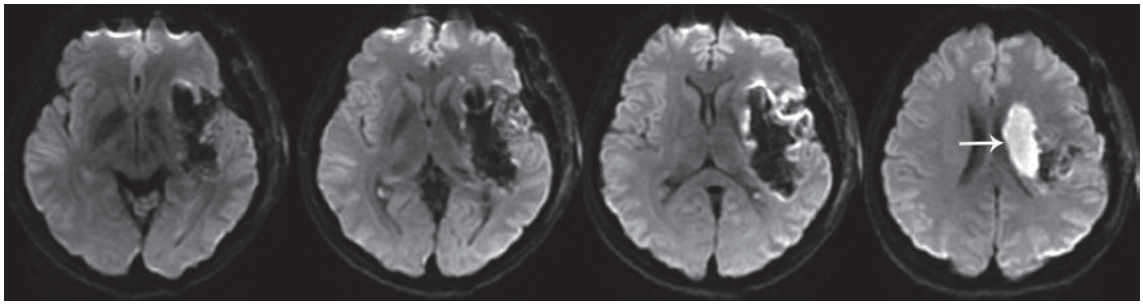

e

Fig. 4. **Clinical case 4: impairment of a distal segment of the LSA (variant I).**

a — cerebral MRI (T2-weighted image, 4 scans at different levels) in the axial projection before surgery, a largely expanded tumor with hyperintense MR signal; b — 3D-TOF MPA (frontal reformatted images): imaging of LSA (white arrow) located along the medial edge of the tumor and displaced in the medial direction; c — intraoperative image (black arrows show the direction of blood flow along the M1 and LSA, white arrow shows the LSA); d — postoperative T2-weighted MRI of the brain (3 scans at different levels); e — postoperative diffusion MRI of the brain: ischemic lesions in the area adjacent to the posterior limb of the internal capsule.

Conclusions

High-resolution time-of-flight (3D-TOF) MRA may be recommended for preoperative imaging of lenticulostriate arteries in planning the volume of neurosurgical operations for patients with insular gliomas. Performed after contrast enhancement, 3DTOF MRA increases the chances of visualizing compressed distal lenticulostriate arteries, especially of their distal segments.

REFERENCES

1. Duffau H, Capelle L. Preferential brain locations of low-grade gliomas. *Cancer*. 2004;100(12):2622-2626. doi:10.1002/cncr.20297.
2. Sanai N, Polley M, Berger M. Insular glioma resection: assessment of patient morbidity, survival, and tumor progression. *J Neurosurg*. 2010;112(1):1-9. doi:10.3171/2009.6.jns0952.
3. Skrap M, Mondani M, Tomasino B, Weis L, Budai R, Pauletto G, Eleopra R, Fadiga L, Ius T. Surgery of Insular Nonenhancing Gliomas. *Neurosurgery*. 2012;70(5):1081-1094. doi:10.1227/neu.0b013e31823f5be5.
4. Sanai N, Berger M. Glioma extent of resection and its impact on patient outcome. *Neurosurgery*. 2008;62(4):753-766. doi:10.1227/01.neu.0000318159.21731.cf.
5. Duffau H, Capelle L, Lopes M, Faillot T, Sichez J, Fohanno D. The Insular Lobe: Physiopathological and Surgical Considerations. *Neurosurgery*. 2000;47(4):801-811. doi:10.1097/00006123-200010000-00001.
6. Duffau H, Taillandier L, Gatignol P, Capelle L. The insular lobe and brain plasticity: Lessons from tumor surgery. *Clin Neurol Neurosurg*. 2006;108(6):543-548. doi:10.1016/j.clineuro.2005.09.004.
7. Hentschel S, Lang F. Surgical Resection of Intrinsic Insular Tumors. *Neurosurgery*. 2005;57(Supplement 1):176-183. doi:10.1227/01.neu.0000163603.70972.ab.
8. Lang F, Olansen N, DeMonte F, Gokaslan ZL, Holland EC, Kalhorn C, Sawaya R. Surgical resection of intrinsic insular tumors: complication avoidance. *J Neurosurg*. 2001; 95(4):638-650. doi:10.3171/jns.2001.95.4.0638.
9. Neuloh G, Pechstein U, Schramm J. Motor tract monitoring during insular glioma surgery. *J Neurosurg*. 2007;106(4):582-592. doi:10.3171/jns.2007.106.4.582.
10. Marinković SV, Kovacević MS, Marinković JM. Perforating branches of the middle cerebral artery. Microsurgical anatomy of their extracerebral segments. *J Neurosurg*. 1985;63(2):266-271. doi:10.3171/jns.1985.63.2.0266.
11. Marinković S, Gibo H, Milisavljević M, Cetković M. Anatomic and clinical correlations of the lenticulostriate arteries. *Clin Anat*. 2001 May;14(3):190-195. doi:10.1002/ca.1032.
12. Vanaclocha V, Saiz-Sapena N, Garcia-Casasola C. Surgical treatment of insular gliomas. *Acta Neurochirurgica*. 1997;139(12):1126-1135. doi:10.1007/bf01410972.
13. Yaşargil MG, Krisht AF, Türe U, Al-Mefty O, Yaşargil DCH. Microsurgery of insular gliomas: Part I. Surgical anatomy of the sylvian cistern. *Contemp Neurosurg*. 2002;24:1-8. doi:10.1097/00029679-200206010-00001.
14. Yaşargil MG, von Ammon K, Cavazos E, Doczi T, Reeves JD, Roth P. Tumours of the limbic and paralimbic systems. *Acta Neurochir (Wien)*. 1992;118(1-2):40-52. doi:10.1007/bf01400725.
15. Simon M, Neuloh G, von Lehe M, Meyer B, Schramm J. Insular gliomas: the case for surgical management. *J Neurosurg*. 2009;110(4):685-695. doi:10.3171/2008.7.jns17639.
16. Moshel Y, Marcus J, Parker E, Kelly P. Resection of insular gliomas: the importance of lenticulostriate artery position. *J Neurosurg*. 2008;109(5):825-834. doi:10.3171/jns/2008/109/11/0825.
17. Saito R, Kumabe T, Inoue T, Takada S, Yamashita Y, Kanamori M, Sonoda Y, Tominaga T. Magnetic resonance imaging for preoperative identification of the lenticulostriate arteries in insular glioma surgery. *J Neurosurg*. 2009;111(2):278-281. doi:10.3171/2008.11.jns08858.

Commentary

The problem of successful management of insular gliomas is related to the maximum reduction of traumatization of the adjacent functionally important structures and the LSA system, which are often included in the tissue of the infiltrative glial tumor of this localization.

Most researchers have pointed out the objective challenges associated with intraoperative identification of these arteries even in their thorough micro-preparation and if maximum proximal dissection of the stem of the middle cerebral artery until branching of the first LSA was performed. It is difficult to track down the further course of the arteries and the place of their inflow into the anterior perforated substance due to the variability of their number and the small (less than 1 mm) diameter. Therefore, preoperative refinement of the relationship between the tumor and the LSA system tract is essential for reducing the possible postoperative complications (ischemic lesions) and consequences such as aggravation of neurological deficit.

For this purpose, the authors used the new technique of 3D-TOF MRA; they have convincingly demonstrated its effectiveness by thoroughly analyzing the technique using sufficient clinical material. The images presented illustrate well the details of the microanatomic relationship between the LSA course and insular gliomas, as well as inclusion of the stems of the microvascular bed into the tumor tissue and other details that need to be taken into consideration by an operating surgeon during microsurgical intervention.

Four clinical cases are described, good discussion is provided, and the conclusion made substantiates the necessity of conducting 3D-TOF MRA after i/v injection of Gd-containing contrast agent.

The paper is innovative, interesting, and contains practically important information for neurosurgeons and neuroradiologists.

V.L. Puchkov (Moscow, Russia)