doi: 10.17116/engneiro201579217-27

The Effect of APOE3 Gene Therapy on Structural and Functional Manifestations of Secondary Hippocampal Damages in Experimental Traumatic Brain Injury

E.G. PEDACHENKO[1], V.V. BILOSHYTSKY[1]*, S.A. MIKHAL'SKY[2], N.YA. GRIDINA[1], T.YU. KVITNITSKAYA-RYZHOVA[2]

[1]A.P. Romodanov State Institute of Neurosurgery, Kiev, Ukraine; [2]D.F. Chebotarev State Institute of Gerontology, Kiev, Ukraine

Aim of the study was to investigate the efficacy of gene therapy for traumatic brain injury (TBI) by evaluating the effect of liposomal transfection of the brain tissue with a *APOE3*-containing plasmid vector on the structural and functional manifestations of secondary brain injuries in acute experimental TBI in rats of various ages. Material and methods. Severe diffuse TBI was inflicted in rats under general anesthesia by weight (450 g) dropped from a height of 1.5 m. A suspension of DOTAP liposomes bearing 25 μg of a plasmid vector pCMV·SPORT6 with cDNA of the APOE3 gene was infused intraventricularly using ALZET osmotic pumps. After investigation of motor functions (using a composite neurological motor score) and cognitive functions (Morris water maze), combined morphological, electron microscopic, immunohistochemical, and morphometric studies of the CA1 hippocampal field were conducted in rats on days 5 and 10 after TBI and gene therapy. Results. Significant changes in the morphofunctional state of the hippocampus as well as in the neurological and cognitive functions were observed in a model of severe TBI in adult and old Wistar rats. Gene therapy, specifically cationic liposome-mediated transfection of central nervous system cells with the plasmid vector carrying the human *APOE3* gene, decreased TBI-induced death of neurons and improved a qualitative composition of the neuronal population, normalized neuron-glia relationships, and decreased gliosis and microglial reaction, axonal damage, myelin destruction, and lipofuscin accumulation. All these effects had age-related peculiarities. A lower intensity of apoptosis processes was observed in the animal brain after gene therapy (the effect was more pronounced in adult animals). These changes were accompanied by faster and more pronounced regression of neurological and cognitive deficits typical of TBI. Administration of the plasmid vector after TBI resulted in a higher survival rate in old animals vs. old animals lacked gene therapy. Conclusion. *APOE3* gene therapy has a therapeutic potential in the treatment of severe TBIs.

Keywords: *traumatic brain injury, gene therapy, apolipoprotein E, hippocampus, ultrastructure, age peculiarities, neurological impairment, cognitive dysfunction.*

Traumatic brain injury (TBI) still remains an urgent social problem; ca. 10 million TBI patients are hospitalized worldwide each year. According to the WHO forecast [1], traumatic brain injury will be ranked third among causes of death by 2020. Another serious problem is the consequences of TBI: in the USA only, 2.5 to 6.5 million people suffer from social and economic challenges associated with neurological, cognitive, and psychosocial effects of TBI [2].

Demographic changes in the modern society and, in particular, the aging of the population, have led to significant changes in the epidemiology of TBI. In the European Union countries, a lower number of severe traffic accidents and a lower mortality from TBI in the young are accompanied by a significantly increased level of brain injuries sustained at home by the elderly. The injury progression in these patients is more severe (e.g., mortality is the highest in patients of over 75 years of age), and the highest number of surgeries for TBIs is performed on patients aged 65—75 [3]. Therefore, it is necessary to study features of TBI progression and treatment in older age groups.

One of the factors underlying the course of post-traumatic processes in TBI is apolipoprotein E (APOE), a glycoprotein encoded by the *APOE* gene, that plays a central role in metabolism, transport, and regulation of the cholesterol and triglyceride levels. After TBI, the synthesis of APOE becomes important for repair of the lipid component of membranes of neurons and gliacytes [4, 5]. In addition to the recognized adaptive functions of APOE in injuries to the central nervous system (CNS), the main determinants of the APOE protective properties were recently demonstrated to be its ability to modify the inflammatory response of activated microglia in the brain and protect nerve cells from excitotoxic injury [6, 7].

There are three human *APOE* alleles: *APOE2*, *APOE3*, and *APOE4*. In contrast to *APOE4*, carriage of the *APOE3* and *APOE2* alleles is associated with better structural and functional outcomes in TBI [8, 9]. Therefore, an idea was put forward to use APOE3 and APOE2 proteins as therapeutic agents providing a therapeutic effect. Since APOE does not pass through the blood brain barrier, its synthesis in CNS cells can be amplified by gene therapy (GT), "a therapeutic procedure in which nucleic acids are used to modulate gene functions" [10].

The aim of this study was to investigate the efficacy of gene therapy for TBI by evaluating the effect of liposomal transfection of the brain tissue with an *APOE3*-containing plasmid vector on the structural and functional manifestations of secondary brain injuries in acute experimental TBI in rats of various ages.

Materials and Methods

The study was conducted in 25 adult (6—8 months) and 20 old (24 months) Wistar male rats. Changes in the cognitive function, exploratory behavior, and emotional state were evaluated at various times after TBI and

© Group of authors, 2015

*e-mail: headinjury@ukr.net

introduction of a plasmid vector (Pl). For morphological studies of the hippocampus and assessment of brain cell apoptosis, the animals were sacrificed on days 5 and 10 after TBI and/or introduction of the vector. The animals were divided into ten groups:

— two control groups: one group of 5 intact adult rats and the other of 4 old rats;

— four TBI groups: two groups of adults rats (5 each) and two groups of old rats (4 each) with experimental TBI;

— four TBI + Pl groups: two groups of adults rats (5 each) and two groups of old rats (4 each) with experimental TBI and a cannula placed in the left lateral cerebral ventricle and connected to an ALZET osmotic pump (DURECT Corp, USA) implanted under the dorsal skin, which infused cationic liposomes and the *APOE3*-carrying plasmid vector for 25 h at the rate of 1 μL/h (1 μg of the vector per hour).

Severe diffuse TBI was inflicted in rats under general anesthesia by weight (450 g), dropped from a height of 1.5 m [11]. Simulation of experimental TBI and subsequent surgical procedures associated with cannula placement and administration of appropriate solutions were performed under general anesthesia (0.7 mg/kg ketamine, intramuscularly). A suspension of DOTAP Methosulfate cationic liposomes (Sigma, USA) containing 25 μg of a pCMV•SPORT6 plasmid vector (Invitrogen, USA) with the human *APOE3* gene under the control of cytomegalovirus promoter was used as a therapeutic agent.

The animals were sacrificed by intraperitoneal injection of a thiopental sodium solution (200 mg/kg). The transfection efficiency (presence of *APOE3*-mRNA) was confirmed in the cerebellum and medulla oblongata by visualization of amplification products (295 base pairs (bp) and 180 bp for the first and second pairs of used primers, respectively) using a reverse transcription polymerase chain reaction (RT-PCR).

Morphological examination. The brain (a portion from the chiasm to the midbrain) was fixed in a 4% paraformaldehyde solution in 0.1 M phosphate buffer for 20 h. The right part of the brain was separated for further processing and confocal microscopy studies. Another part was dehydrated and embedded in paraffin (paraplast) by a standard procedure. Frontal serial sections (6 μm thick) at the level of the sensorimotor cortex, hippocampus, and hypothalamus were prepared from the resulting blocks using a Microm HM 325 rotary microtome (Carl Zeiss, Germany). Some sections were stained with thionine according to Nissl, some were used to detect apoptotic cells by the TUNEL assay.

Immunohistochemical analysis of apoptosis. Fragmentation of the nuclear DNA, which characterizes the final step of cell apoptosis, was assessed by the TUNEL assay using the Apoptag Plus Peroxidase *In Situ* Apoptosis Detection Kit of reagents according to the manufacturer's recommendations (Chemicon, USA). The number of nuclei in each rat was counted in (20±2) fields of a constant area in various parts of the brain using a ×20 objective and a ×10 eyepiece. The apoptotic index (AI) was calculated as a ratio (in percent) of TUNEL-positive nuclei to the total number of cell nuclei.

Immunohistochemical analysis of neurons and astrocytes (double immunolabeling). A Vibroslice 752M vibrotome (Campden Instruments Ltd, UK) was used to produce frontal sections (50 μm) of the right half of the brain, containing the hippocampus. Further processing was performed according to the protocol of the Department of Cytology of the Bogomolets Institute of Physiology. The processing led to the binding of murine anti-NeuN antibodies (1:1,000, Dako, Denmark) to the NeuN neuronal marker and rabbit anti-GFAP antibodies (1:1,000, Dako) to the GFAP astrocyte marker. Green fluorescence at the NeuN localization sites was due to binding of anti-murine Alexa Fluor 488-conjugated antibodies, and red fluorescence at the GFAP localization sites was due to binding of the anti-rabbit antibody conjugated to Alexa Fluor 568 (Molecular Probes Inc, USA). We used a FV1000-BX61WI confocal microscope (Olympus, Japan) available at the center for shared usage of the Bogomolets Institute of Physiology.

Electron microscopic study. Frontal plane slices (0.5 mm thick) were excised from the hippocampus during the sacrifice and were processed according to the standard procedure of sample preparation for electron microscopy. Semithin sections (1 μm) of the hippocampus were stained with toluidine blue and used to localize the CA1 hippocampal field, from which ultra-thin sections (60—70 nm) were prepared for examination on a PEM125K electron microscope (Selmi, Ukraine).

Semithin sections were also used for morphometry, determination of a linear density of neurons (LDN), glia (astro- and oligodendrocytes) (LDG), and microglia (LDM) of the CA1 hippocampal region (100 fields per group using a ×20 objective and a ×10 eyepiece), i.e. counting of the number of cells per unit of the hippocampus length.

The fraction of destructively changed mitochondria (MTs) in the cytoplasm was determined by counting the total number of MTs on a microphotograph and calculating the percentage of destructively changed ones. To determine the volume fraction of lipofuscin (Lf) in the neuron cytoplasm, the Lf total area was measured, and the volume fraction (percentage) was calculated as the Lf to cytoplasm area ratio. The fraction of damaged myelin fibers in the neuropil was calculated by the following formula:

(number of damaged axons/total number of axons) × 100%.

Motor function analysis [12]. A 5-point scale (from 0 — severe injury to 4 — normal motor function) was used to assess a set of indicators on the day of the experiment beginning before inflicting injury and on days 1—7 after the injury. The indicators were as follows:

1) left forelimb flexion during suspension by the tail;

2) right forelimb flexion during suspension by the tail;

3) left hindlimb flexion with the forelimbs remaining on a flat surface while the hindlimbs suspended by the tail;

4) right hindlimb flexion with the forelimbs remaining on a flat surface while the hindlimbs suspended by the tail;

5) resistance to lateral push to the left;

6) resistance to lateral push to the right;

7) ability to stand on an inclined plane in the left direction;

8) ability to stand on an inclined plane in the right direction;

9) ability to stand on an inclined plane in the vertical direction.

The three latter tests assessed the ability of an animal to stand on an inclined plane at an angle of 40° (the maximum score of 4), 37.5° (3), 35° (2), 32.5° (1), and less than 32.5° (0). The composite neurological motor score for each animal was calculated by totaling of individual test scores.

Analysis of cognitive functions. Evaluation of animal spatial memory in the Morris water maze was performed on days 7—10 after injury [13]. A total of 16 trials (4 per day) were conducted, in which rats learned how to find a platform hidden under the surface of colored water, relying on external visual references. Each day during the study, the "searching time" indicator was determined for each rat as a mean time of 4 trials (in seconds) required for the animal to reach the platform. The mean searching time for each group in the experiment was calculated based on these data for a specific day of the study. Longer searching time was indicative of more pronounced deficit in spatial memory and learning ability.

Statistical analysis was performed using the nonparametric Wilcoxon-Mann-Whitney test.

Results and Discussion

Light-optical histological examination on day 10 after injury revealed pronounced structural changes in neurons, glial cells, and capillaries of the brain. They were characterized by fragmentary detachment of the leptomeninges, their swelling, and dissection by diffuse-focal (often massive) agglomerations of modified erythrocytes, the formation of zones with necrobiotically changed nerve cells around hemorrhages, and diffuse edema of cerebral tissue. Areas of neuron loss, i.e. a neuronal depopulation in the hippocampus, were detected in the CA1 hippocampal field. LDN was significantly reduced (1.4-fold) in TBI **(Fig. 1)**.

Several, most common types of neurons of the CA1 field were distinguished: unchanged large (hypertrophic) and hyperchromic. An increase in the number of hyperchromic neurons, with the number of unchanged neurons being reduced, was the most striking finding. The results of an electron microscopic analysis indicate significant destructive changes in the CA1 hippocampal field in TBI and an increase in TBI heterogeneity. Both apoptotically changed, dying cells and activated cells were observed among hyperchromic neurons **(Fig. 2)**. Intranuclear inclusions, of fibrillary kind usually, were often present in neuronal nuclei **(Fig. 3)**, which may indicate profound rearrangement of nuclear proteins and the start of irreversible destructive processes in the nucleus. Vacuolation of Golgi cisterns and significant changes in MTs were observed in the neuronal cytoplasm. Most MTs were represented by destructively changed and dramatically swollen vacuolated forms with destruction and dyscomplexation of christae and damaged membranes **(see Fig. 3)**. Mitochondrial membrane remnants were incorporated into residual Lf bodies and granules, the volume and amount of which increased from 1—4 in control groups to 10 or more in TBI groups **(see Fig. 3)**.

Application of gene therapy (TBI + Pl) was associated with the fact that the TBI-induced destructive and degenerative changes in neurons were less intense and extensive. Induction of the APOE3 synthesis had a positive effect on the state of nervous tissue and prevented the development of secondary disintegration zones in the injured brain. The fraction of destructively changed MTs in neurons was lower than that in the TBI group: 55 and 70%, respectively **(see Fig. 3)**. GT not only reduced the level of MT destruction but also altered the ratio of functionally different organelles. In the TBI + Pl group, the fraction of unchanged and functionally active (moderately swollen) organelles was slightly increased due to a reduction in the amount of destructive forms (dramatically swollen at the initial stages of membrane destruction). GT had a much more pronounced effect on Lf accumulation in younger animals compared to older ones. For example, the fraction of Lf in the cytoplasm of old rats decreased due to treatment from 12% of the area in the TBI group to 11% in the TBI + Pl group. In this case, the inhibitory effect of GT on accumulation of Lf was stronger in adult rats: the Lf fraction amounted to 5% of the cytoplasm area in the TBI + Pl group and to 8% in the TBI group **(see Fig. 3)**.

After TBI, deep ultrastructural changes were detected not only in the perikaryons but also in the processes of nerve cells. More than 1/3 of myelin fibers appeared to be damaged **(Fig. 4)**. A rather typical reaction is damage of axons in the form of their local swelling and deformation of the axial cylinder, its obliteration, and, in some cases, detachment from the myelin sheath (with the formation

of vacuoles between them) that was combined with disintegration, homogenization, and destruction of intracellular neurite structures. There were marked changes in the cytoskeleton, such as damage to a neurofilament and local (less often, complete) loss of microtubules, which led to disruption of axonal transport.

Significant changes occurred in axonal MTs: dyscomplexation of cristae and dramatic swelling, associated with hypertrophy of some organelles, were observed. There was disruption of myelin sheaths in the form of their dissection, disaggregation, disruption of the lamellar structure, and formation of swellings and protrusions. In addition, there were destructive changes in the synapses. Local damages to the axolemma cause the release of calcium, which leads to intraaxonal disruption of the cytoskeleton and MTs as well as interneuronal connections. Damage to MTs may also lead to the release of cytochrome C that, in turn, activates catalases and plays a certain role in neuronal apoptosis. TBI-induced destructive and degenerative changes in axons were less intense and extensive in the case of gene therapy (TBI + Pl). In particular, the axonal structure was less damaged in the TBI + Pl group than in the TBI group. Both the structure of the axial cylinder, its cytoskeleton, and MTs and the structure of myelin sheaths were normalized. Swelling and deformation of axons were less common. The fraction of damaged myelin fibers in the TBI + Pl group was 22%, whereas it amounted up to 35% in the TBI group **(Fig. 5)**.

Immunohistochemical analysis of apoptosis. The structure of hippocampal pyramidal layer is affected by TBI; there appear areas of local thinning with the loss of neurons (due to their destruction and elimination). GT prevented death of some neurons in the injured brain, and LDN of the hippocampus was 12% higher in the TBI + Pl group than in the TBI group. Also, the qualitative composition of the neuronal population was improved: an increase in the number of hyperchromic neurons was less pronounced, which was more evident in old rats. The observed decrease in the number of neurons in TBI is closely related to the apoptotic processes that, most likely, occur within the first days after injury [14]. The TUNEL assay showed that on day 10, and even on day 5, after injury, the level of apoptosis was low in all studied groups: the number of cells in the apoptotic state was less than 4.4% of the total cell number **(Fig. 6)**.

The severity of apoptotic processes in the brain significantly increased with age. In all experimental groups, AI of intact old rats was 5—6 times higher than that of adult rats (**see Fig. 6**). The maximum level of apoptotic death of neurons and glia was observed after injury (in the TBI group), which was particularly evident in old animals. The difference with the intact control, however, was more pronounced in adult rats: their AI increased 6 times, on average, whereas only a 2.6-fold increase was in old animals.

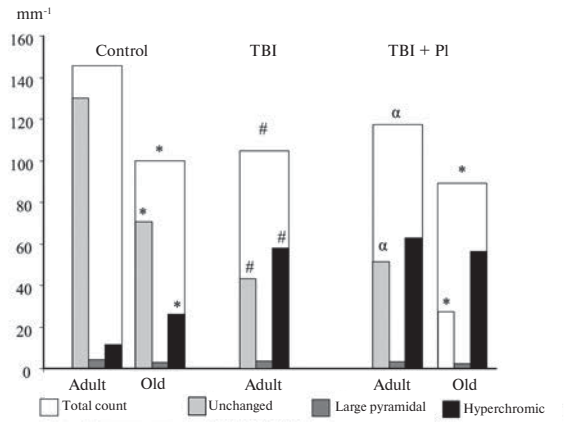

Fig. 1. **The linear density of neurons in the hippocampal CA1 field of rats with allowance for their qualitative characterization (on day 10 after the experiment beginning).**

Here and in Fig. 3, 5, and 7: * — $p<0.05$ compared to adult rats, # — $p<0.05$ compared to an appropriate control group, α — $p<0.05$ compared to an appropriate TBI group.

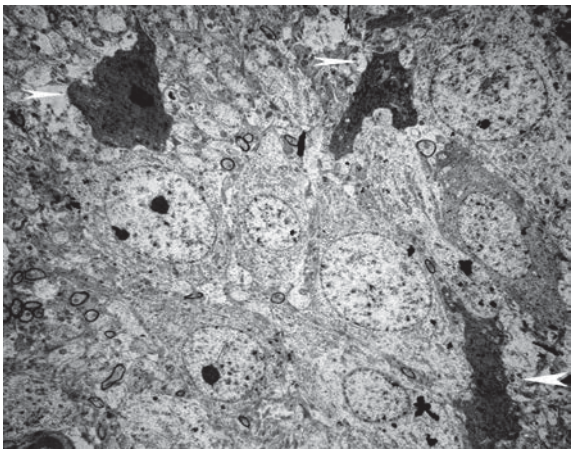

Fig. 2. **A part of the hippocampal CA1 field of an adult rat on day 10 after TBI: heterogeneity of the morphological picture.**

Unchanged and electron-dense, destructively changed cells (the latter are indicated by pointers), ×1600.

After TBI, the apoptotic processes in all experimental groups were more intense after 5 days than after 10 days, indicating gradual attenuation of the apoptotic activity. However, the differences between AI values on days 5 and 10 were statistically significant only in adult animals from TBI and TBI + Pl groups, which, in our opinion, reflects a better ability of adult animals to restore nerve tissue and block apoptosis compared to old animals. In the TBI group, AI increased more in adult rats than in old ones.

Application of GT (TBI + Pl) induced positive dynamics of cell death: there was a decrease in AI on days 5 and 10 after injury compared with the TBI group. GT was more effective in the group of adult animals.

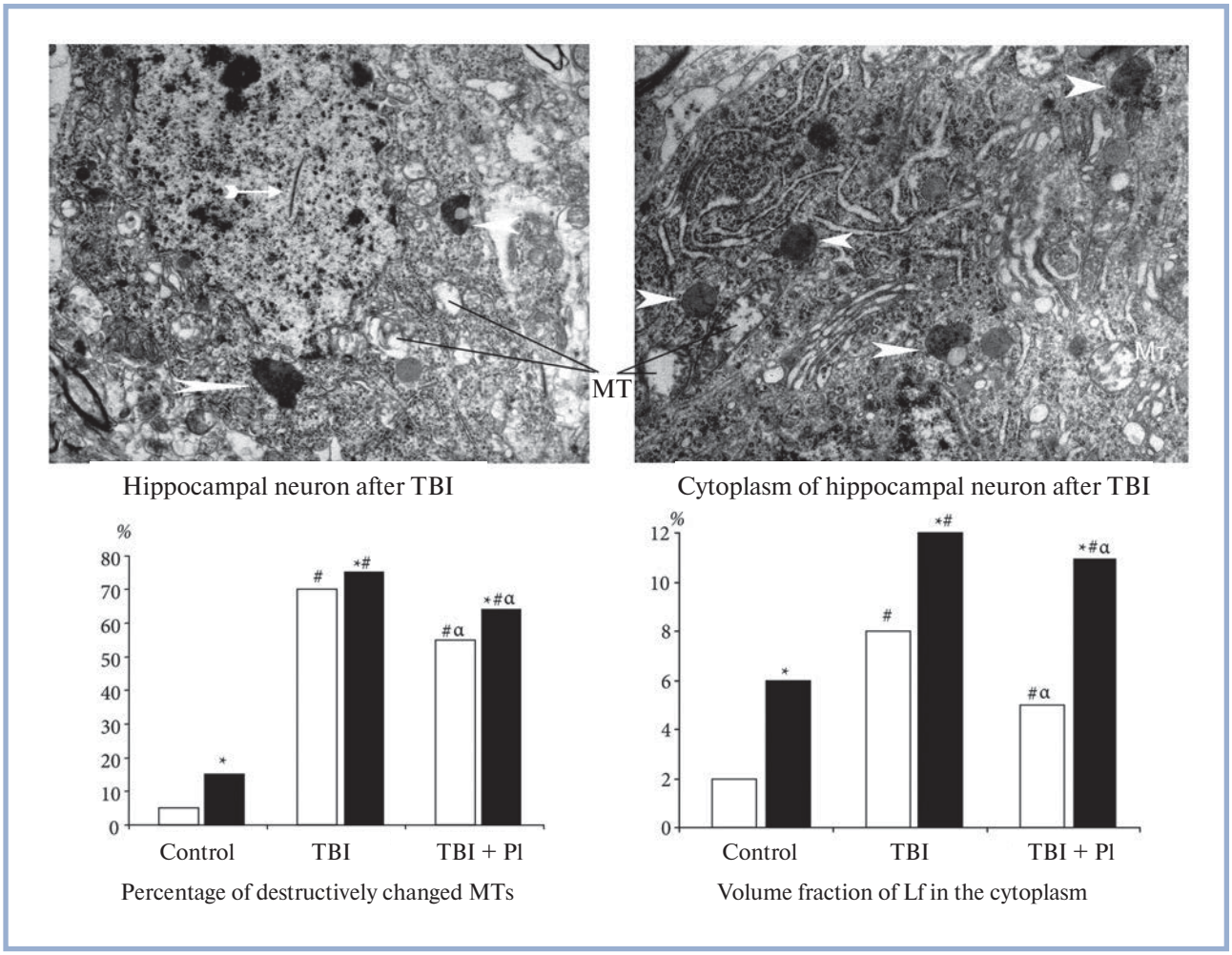

Fig. 3. **Destructive changes in neurons of the hippocampal CA1 field of rats on day 10 after TBI.**

Fibrillar intranuclear inclusions (arrow), Lf granules (pointers), vacuolation of MT, uneven expansion of the granular endoplasmic reticulum tubules and loss of ribosomes on their membranes, destruction of Golgi complex elements (× 3200 in the left panel, × 6400 in the right panel); white bars — adult animals, black bars — old animals.

Compared with the TBI group, administration of the plasmid vector resulted in a 1.25-fold decrease in AI on day 5 and a 1.20-fold decrease on day 10. At the same time, in old animals, there was only a 1.13-fold decrease on day 5 and a 1.09-fold decrease on day 10. The less pronounced effect in old rats may be attributed to pre-existing age-related morphological changes of nerve tissue. A high variability of AI values in these groups prevents any conclusions on the validity of the decrease due to gene therapy. However, given the data on LDN, which was 1.17 times higher in the TBI + Pl group than in the TBI group, as well as improved indicators of some structural characteristics of the nervous tissue, it is possible to claim that GT has an inhibitory effect on the apoptotic processes and a positive influence on the morphofunctional condition of neurons in the CA1 hippocampal field.

A characteristic feature of the TBI-induced changes in the hippocampus is pronounced gliosis. It was less intense in the TBI + Pl group.

A morphometric analysis of macroglia revealed a significant increase in LDG (total of astro- and oligodendrocytes) **(Fig. 7)**. The highest increase in LDG was observed in the TBI group (41%), whereas it was less pronounced (8%) in the GT (TBI + Pl) group.

According to electron microscopy, rats from the TBI group had marked degenerative changes in their glia, such as significant accumulation of Lf (1—4 granules in the cytoplasm of control animals vs. 10 or more in the TBI group) and vacuolation of the Golgi cisterns. The number of Lf granules in gliacytes increased to a greater extent than in neurons, and the granule volume increased as well. There was also an increase in the number and size of residual bodies. An important component of post-TBI changes in the nervous tissue is a redistribution of intra- and intercellular fluid, which is manifested as swelling of astrocyte processes (especially pronounced in perivasal areas and, in some cases, quite large-scale), focal or diffuse swelling of bodies of gliacytes and neurons and neuronal processes.

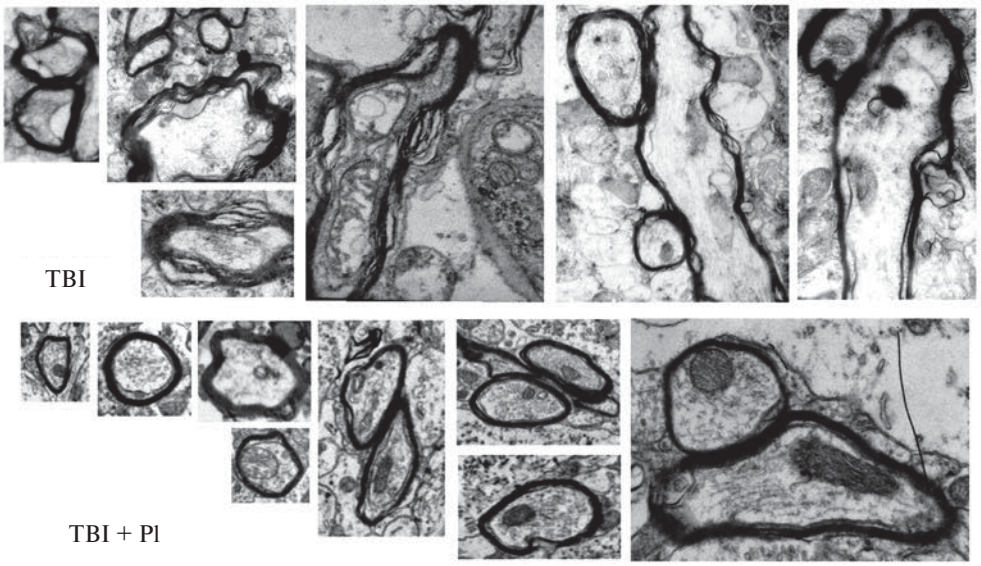

Fig. 4. **Electron diffraction patterns of a part of neuropil of the hippocampal CA1 field of rats from different groups.**

TBI — different degree of manifestations of destruction of axial cylinders and axonal myelin sheaths, deformation of axial cylinders, local swelling, disruption of the cytoskeleton, swelling of hypertrophic mitochondria (up to the formation of vacuoles), dissection of myelin sheaths; TBI + Pl: normalizing effect of gene therapy on the structure of myelinated axons of the hippocampal field. ×4,800—12,000.

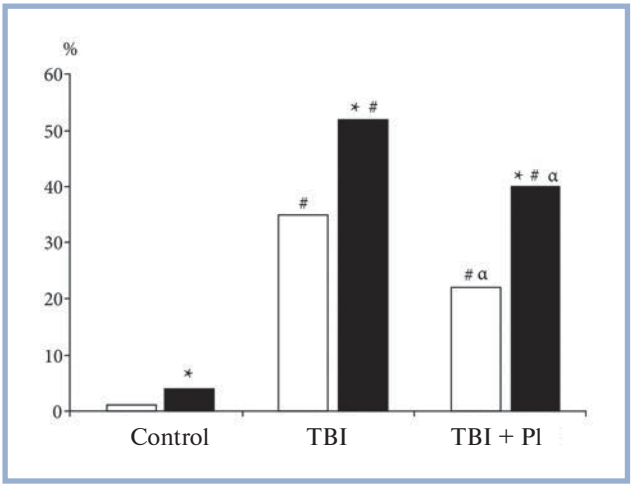

Fig. 5. **The effect of gene therapy on the fraction of affected myelin fibers on day 10 after TBI in adult (white bars) and old (black bars) rats.**

TBI-induced destructive and degenerative changes in gliacytes were less intense and extensive in the case of GT (TBI + Pl). The morphometric analysis showed that GT contributed to smaller accumulation of Lf in gliacytes; compared to the control group, the number of Lf granules was 3 and 6 times higher in TBI + Pl and TBI groups, respectively. However, swelling remained significant, especially in the area of astrocyte processes in the pericapillary zone.

Hyperplasia and hypertrophy of the microglia also occurred in TBI. At the ultrastructural level, there were large macrophage-like cells with numerous large electron-dense vesicles. The morphometric analysis of LDM revealed signs of its activation in the hippocampus of injured animals. A significant increase of LDM in all experimental groups compared to control animals reflects proliferation of microglia and migration of its cells to a lesion. The increase in LDM was much stronger than that in LDG (in 4.5 times) **(see Fig. 7)**. The GT (TBI + Pl) group had a tendency to inhibit the increase in LDM.

Immunohistochemical analysis of neurons and astrocytes (double immunolabeling). A typical sign of hippocampal damage in severe diffuse experimental TBI was activation of neuron-glia relationships. The data of fluorescent immunohistochemical confocal microscopy confirmed the loss of neurons (lower density of NeuN-positive neurons) in the hippocampus. The observed changes included hypertrophy of astrocyte bodies, an increase in their volume, and an increase in the number and size of their processes whose branching was increased, and the branching pattern changed from star-like to bushy **(Fig. 8)**. In this case, astrocyte bodies got closer to the neuron layer; the contact area of neurons and astrocytes was enlarged, and astrocyte processes often spread in neurons of the pyramidal layer. GT had a positive influence on the structure and ultrastructure of the hippocampus, including a reduction in the number of astrocytes in the radial layer and normalization of their structure (process branching in the TBI + Pl group was predominantly star-like, as in the control).

The identified distortion of the CA1 hippocampal field cytoarchitectonics is the morphological substrate of cognitive impairments in traumatic brain injuries.

Motor function analysis. Since a significant part of old animals died after TBI, and the state of survivors was

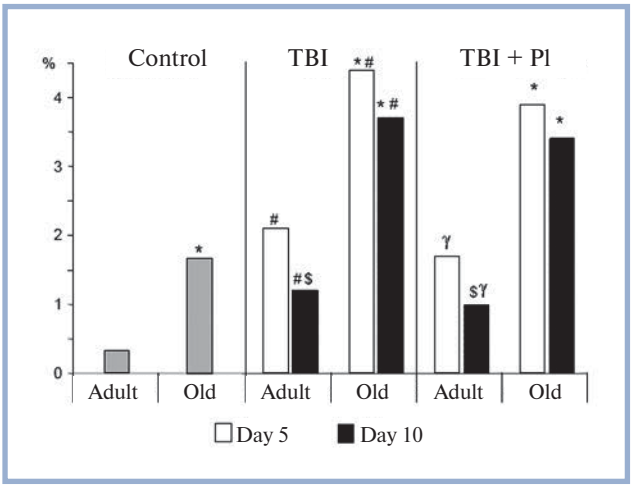

Fig. 6. **The apoptotic index in the brain of rats after TBI and gene therapy on days 5 and 10.**

* — $p<0.05$ compared to adult rats from a corresponding group, # — $p<0.05$ compared to intact rats of corresponding age, γ — $p<0.05$ compared to an appropriate TBI group, $ — $p<0.05$ compared to day 5 for thisv age group.

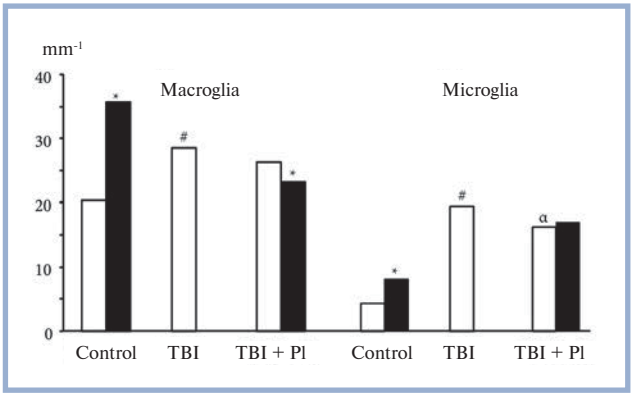

Fig. 7. **Linear density of macro- and microglia in the hippocampal CA1 field of rats on day 10 after TBI in adult (white bars) and old (black bars) animals.**

often unsatisfactory, they were not included in functional studies whose results are presented below. However, administration of the plasmid vector after TBI (TBI + Pl group) increased the number of animals survived till day 10 (the day of sacrifice).

Investigation of neurological disorders in rats with experimental TBI using the composite neurological motor score **(Fig. 9)** revealed that animals subjected to liposomal transfection of brain tissue with the APOE3-carrying plasmid vector demonstrated in the posttraumatic period faster regression of neurological symptoms compared with rats in the TBI group and rapid recovery of impaired functions, including the strength and range of reflex forelimb and hindlimb movements and motion coordination. On days 3 and 4 after injury, the composite neurological motor score in treated animals was significantly higher than that in the group of rats with TBI: (24.0±3.81) points on day 3 after injury compared to (17±2.95) points in the TBI group (p=0.02); (26.4±3.36) points on day 4 after injury compared to (19.8±3.27) points in the TBI group (p=0.02).

Cognitive function analysis. The evaluation of the gene therapy impact on the dynamics of spatial memory deficits in rats with TBI revealed that the searching time required for control animals to reach a platform rapidly decreased during the posttraumatic period **(Fig. 10)**. In the TBI group, the searching time decreased at a slower rate and statistically significantly exceeded this indicator for the control group throughout the study: (74.2±4.32) s vs. (17.2±3.27) s on day 8 (p=0.01); (64.2±4.21) s vs. (16.2±2.49) s on day 9 (p=0.01); (61.2±4.32) s vs. (9.6±2.41) s on day 10 after injury (p=0.01). In the TBI + Pl group, *APOE3* gene transfer facilitated a more rapid regression of cognitive disorders, in particular, a reduction in deficit of spatial memory and learning ability. On day 8 of the experiment, the searching time value in the experimental group was (49.0±6.21) s compared to (74.2±4.32) s in the TBI group (p=0.01); on day 9, it was (34.8±3.96) s compared to (64.2±4.21) s (p=0.01); and on day 10, it was (30.2±3.96) s compared with (61.2±4.32) s (p=0.01).

In the recent decades, advances in molecular biology and genetics made it possible to use new approaches to evaluation of dynamics of structural and functional changes in TBI. It has been recognized that pathological changes in traumatic brain injury are "not isolated events but processes set in motion by mechanical impact. These processes are not completed within any reasonable period of time after injury" [15]. At present, primary brain injuries are proved to develop within a relatively short period of time. They are followed by a process referred to as "delayed cell death". In this case, the number of nerve cells dying due to secondary injuries may greatly exceed that due to primary injury. With allowance for this, the contribution of delayed cell death to the development of neurological deficit appears to be very significant, and the length of the period of secondary death of nerve cells defines the so-called "therapeutic window" that enables therapeutic measures facilitating neuroprotection [16, 17].

Conclusions

The study results demonstrate that severe diffuse experimental TBI is characterized by the development of secondary injuries to the hippocampus with disruption of its cytoarchitectonics as well as by the development of destructive and degenerative changes in all of its elements (neurons, glia, capillaries). These structural-cellular disruptions manifested at the functional level as neurological deficit and cognitive impairments. The use of gene therapy (liposomal transfection with the *APOE3*-carrying plasmid vector) had a positive effect on the structure and ultrastructure of the hippocampus: TBI-induced death of neurons was decreased (the decrease was more pronounced in adult animals than in old ones);

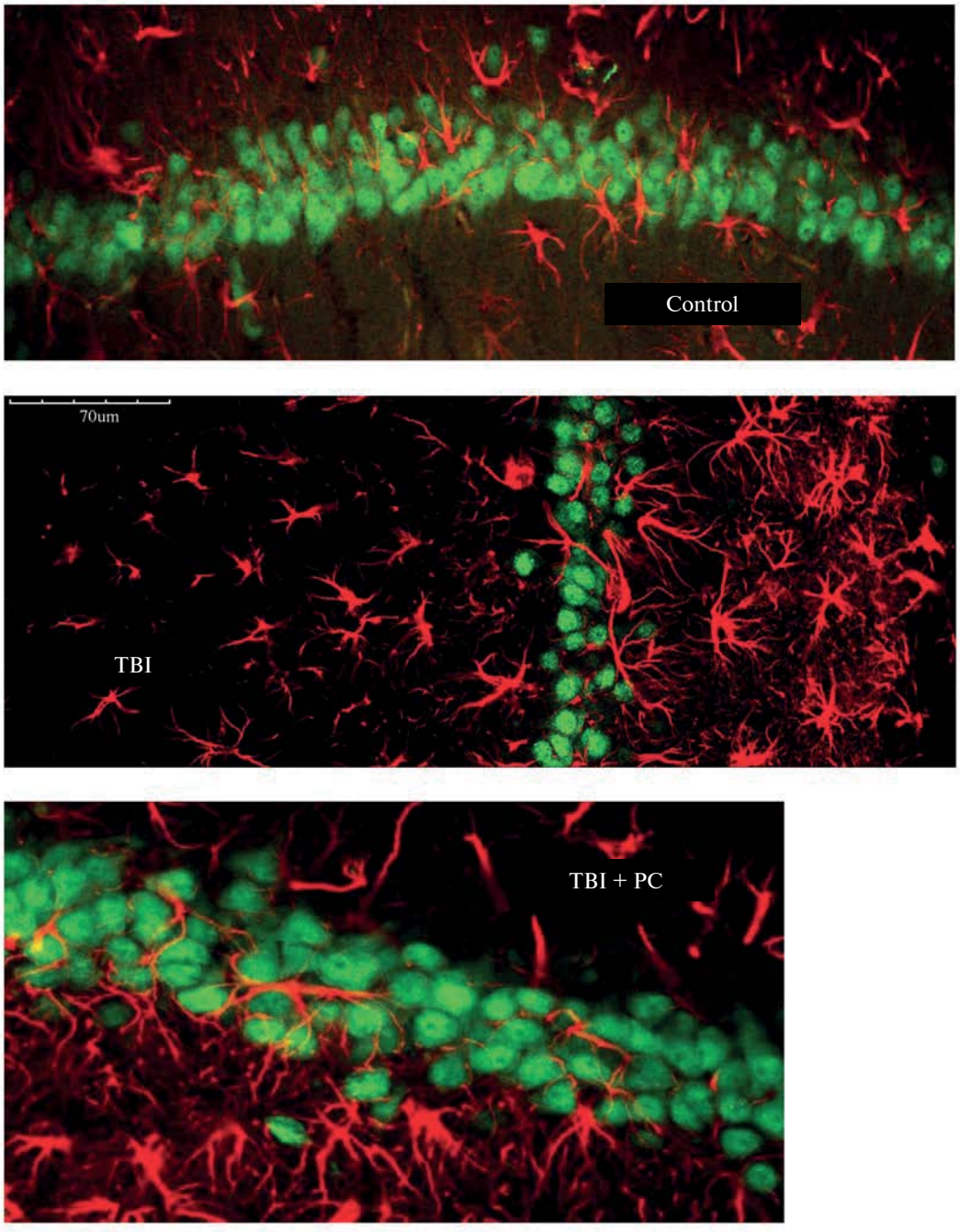

Fig. 8. **Immunofluorescence (laser scanning confocal microscope) of *NeuN*-positive neurons (green) and *GFAP*-positive astrocytes (red) of the hippocampal CA1 field of rats.**

TBI group: hypertrophy of astrocyte cell bodies, increased number of their processes, changes in the process branching pattern from star-like to bushy; TBI + Pl group: normalization of processes branching forms with preservation of hypertrophy (×200 for the control group and TBI, and × 400 for TBI + Pl).

the qualitative composition of neurons was improved; also, there was a reduction in axonal damage and myelin destruction, gliosis and microglial reaction, pericapillary edema and lipofuscin accumulation; the structure of astrocytes was normalized, and the number of small neurons in the hippocampal radial zone was increased. These changes were accompanied by lower severity and more faster regression of neurological and cognitive deficits caused by injury.

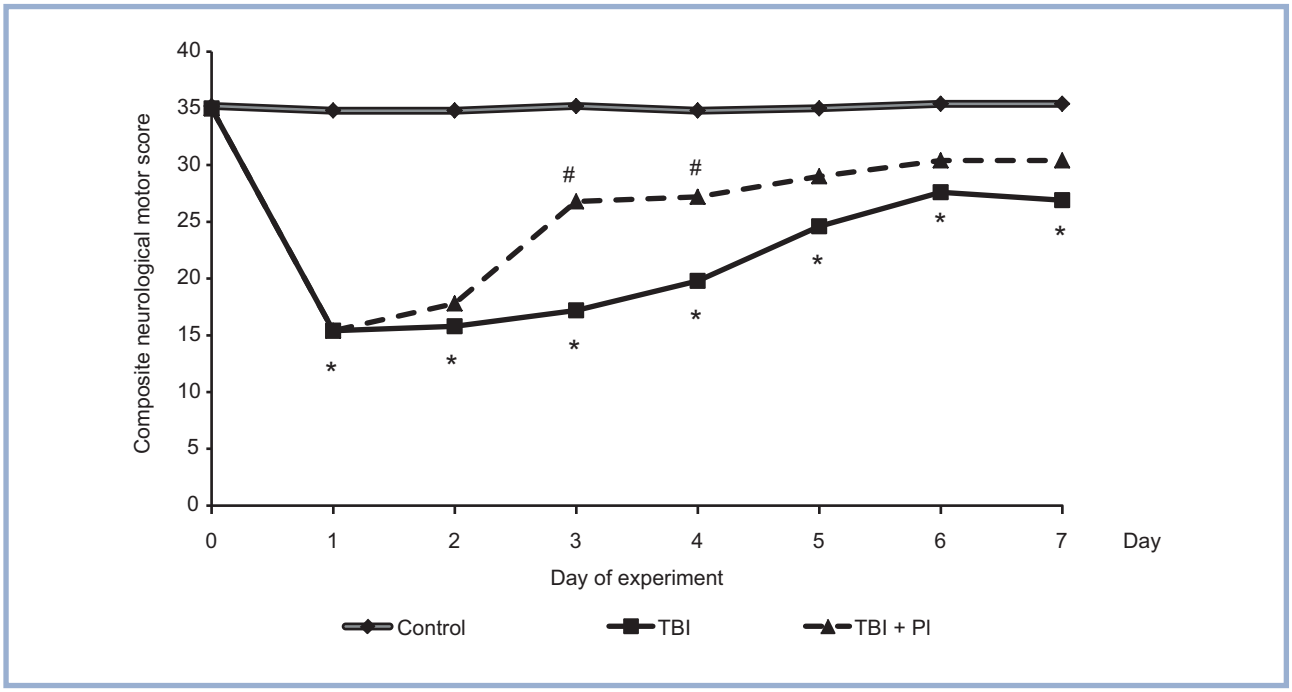

***Fig. 9*. The effect of gene therapy on the dynamics of neurological deficit in adult rats with experimental TBI.**
Here and in Fig. 10: * — $p<0.05$ compared to the control group, # — $p<0.05$ compared to TBI.

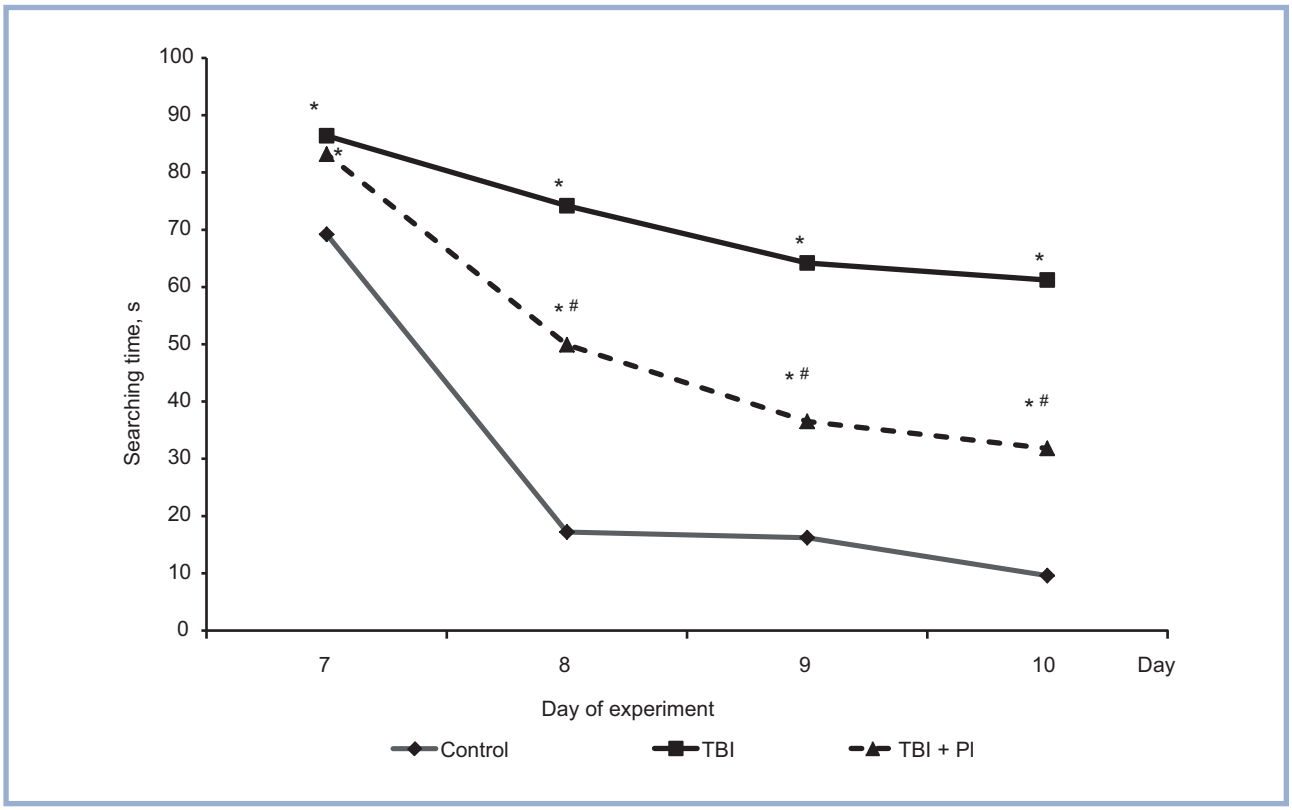

***Fig. 10.* The effect of gene therapy on the dynamics of cognitive deficit in adult rats with experimental TBI.**

The literature data [4, 6, 7, 18, 19] suggest several possible mechanisms of APOE influence on TBI outcomes, namely: 1) the influence of APOE on normalization of the lipid component of nerve cells; 2) a role of APOE in the regulation of glial reactions and inflammatory response of the CNS to injury; 3) antioxidative effects of APOE; 4) involvement of APOE in the regulation of cell death; 5) the effect of APOE on expression of other genes and regulation of genomic response of CNS cells in the case of CNS diseases and injuries.

In recent years, interest in APOE neuroprotective properties has led to the development of another approach to its use in experimental traumatic and ischemic brain damages. In contrast to the full APOE molecule, peptides corresponding to an APOE molecule fragment responsible for binding to low density lipoprotein receptors (this domain is identical in different isoforms of the protein) demonstrated the ability to penetrate through the blood-brain barrier. A team of US researchers showed that single intravenous administration of similar peptides to mice after TBI reduced the neuroinflammation effects, decreasing activation of micro- and macroglia. This was accompanied by a decrease in death of hippocampal neurons and in the volume of focal damages to the brain as well as by improvement in neurological and cognitive manifestations of TBI [7, 20]. Later, a similar effect of APOE fragments was found in a model of transient focal cerebral ischemia and reperfusion in the same laboratory [21] as well as in collaboration with Russian scientists from the Shemyakin-Ovchinnikov Institute of Bioorganic Chemistry [22].

Further development of effective methods of neuroprotection in TBI may be based on a more detailed understanding of mechanisms of the APOE protective action, development of the most appropriate mechanisms for delivery of APOE molecules or its functionally important fragments (given that the effects of APOE are implemented through the interaction of its receptor-binding domains with corresponding LDL-receptors) into the injured CNS by gene therapy or another possible way as well as on evaluation of the potential of using APOE or APOE-derived therapeutic agents in clinical practice.

REFERENCES

1. *Murray C.J., Lopez A.D.* Alternative projections of mortality and disability by cause 1990—2020: Global Burden of Disease Study. Lancet 1997; 349: 1498—1504.
2. *Fujimoto S.T., Longhi L., Saatman K.E., Conte V., Stocchetti N., McIntosh T.K.* Motor and cognitive function evaluation following experimental traumatic brain injury. Neurosci Biobehav Rev 2004; 28: 365—378.
3. *Steudel W.I.* Epidemiological data of TBI in Europe and Germany: facts and trends International neurosurgical forum in Siberia, June 18—21, 2012. In: Collection of scientific papers. Novosibirsk: Science Design 2012; 187.
4. *Hauser P.S., Narayanaswami V., Ryan R.O.* Apolipoprotein E: from lipid transport to neurobiology. Prog Lipid Res 2011; 50: 62—74.
5. *Poirier J.* Apolipoprotein E in animal models of CNS injury and in Alzheimer's disease. Trends Neurosci 1994; 17: 525—530.
6. *Hayashi H., Campenot R.B., Vance D.E., Vance J.E.* Apolipoprotein E-containing lipoproteins protect neurons from apoptosis via a signaling pathway involving low-density lipoprotein receptor-related protein-1. J Neurosci 2007; 27: 1933—1941.
7. *Laskowitz D.T., Vitek M.P.* Apolipoprotein E and neurological disease: therapeutic potential and pharmacogenomic interaction. Pharmacogenomics 2007; 8: 959—969.
8. *Pedachenko E.G., Beloshitskiy V.V., Vasil'eva I.G.* Apolipoprotein E: its physiological role and potential theurapeutic efficacy in traumatic brain injury Neirokhirurgiya. 2003; 1: 59—65. In Russian.
9. *Novikova S.M., Muravs'kiy A.V.* The role of apolipoprotein E in development of neurological pathologies (review). Zhurn. AMN Ukraini 2009; 15: 476—487. In Ukrainian.
10. *Russel S.J.* Gene therapy. In: Russel S.J., Peng K.W. Pharmacology and Therapeutics — Principles to Practice. Eds. S.A. Waldman, A. Terzic. New York: Elsevier Saunders 2009; 1295—1316.
11. *Marmarou A., Foda M.A., van den Brink W., Campbell J., Kita H., Demetriadou K.* A new model of diffuse brain injury in rats. Part I: Pathophysiology and biomechanics. J Neurosurg 1994; 80: 291—300.
12. *Philips M.F., Mattiasson G., Wieloch T., Björklund A., Johansson B.B., Tomasevic G., Martínez-Serrano A., Lenzlinger P.M., Sinson G., Grady M.S., McIntosh T.K.* Neuroprotective and behavioral efficacy of nerve growth factor-transfected hippocampal progenitor cell transplants after experimental traumatic brain injury. J Neurosurg 2001; 94: 765—774.
13. *Jenkins L.W., Lu Y., Johnston W.E., Lyeth B.G., Prough D.S.* Combined therapy affects outcomes differentially after mild traumatic brain injury and secondary forebrain ischemia in rats. Brain Res 1999; 817: 132—144.
14. *Jia F., Mao Q., Liang Y.-M., Jiang J.-Y.* Effect of post-traumatic mild hypothermia on hippocampal cell death after traumatic brain injury in rats. J Neurotrauma 2009; 26: 243—252.
15. *Sahuquillo J., Poca M.A., Amoros S.* Current aspects of pathophysiology and cell dysfunction after severe head injury. Curr Pharm Des 2001; 7: 1475—1503.
16. *Beauchamp K., Mutlak H., Smith W.R., Shohami E., Stahel P.F.* Pharmacology of traumatic brain injury: where is the «golden bullet»? Mol Med 2008; 14: 731—740.
17. *Johnston M. V., Trescher W.H., Ishida A., Nakajima W.* Novel treatments after experimental brain injury. Semin Neonatol 2000; 5: 75—86.
18. *Crawford F., Wood M., Ferguson S., Mathura V., Gupta P., Humphrey J., Mouzon B., Laporte V., Margenthaler E., O'Steen B., Hayes R., Roses A., Mullan M.* Apolipoprotein E-genotype dependent hippocampal and cortical responses to traumatic brain injury. Neuroscience 2009; 159: 1349—1362.
19. *Jofre-Monseny L., Loboda A., Wagner A.E., Huebbe P., Boesch-Saadatmandi C., Jozkowicz A., Minihane A.M., Dulak J., Rimbach G.* Effects of apoE genotype on macrophage inflammation and heme oxygenase-1 expression. Biochem Biophys Res Commun 2007; 357: 319—324.
20. *Hoane M.R., Pierce J.L., Holland M.A., Birky N.D., Dang T., Vitek M.P., McKenna S.E.* The novel apolipoprotein E-based peptide COG1410 improves sensorimotor performance and reduces injury magnitude following cortical contusion injury. J Neurotrauma 2007; 24: 1108—1118.
21. *Wang H., Anderson L.G., Lascola C.D., James M.L., Venkatraman T.N., Bennett E.R., Acheson S.K., Vitek M.P., Laskowitz D.T.* ApolipoproteinE mimetic peptides improve outcome after focal ischemia. Exp Neurol 2013; 241: 67—74.
22. *Tukhovskaya E.A., Yukin A.Y., Khokhlova O.N., Murashev A.N., Vitek M.P.* COG1410, a novel apolipoprotein-E mimetic, improves functional and morphological recovery in a rat model of focal brain ischemia. J Neurosci Res 2009; 87: 677—682.

Commentary

It is now becoming increasingly clear that the course and outcome of traumatic brain injury (TBI) are defined not only by its biomechanism, severity, age, presence of premorbid factors, etc. but also by individual features of the genome of each patient, which refers traumatic brain disease to multifactorial diseases. Over the last few years, genetic studies of multifactorial diseases and traumatic injuries of the nervous system have acquired great importance. The genome defines the presence or absence of genes of predisposition to the development of certain complications and consequences of TBI that, in general, determines the course of traumatic brain disease. The predisposition genes are mutant genes (alleles) coexiting with birth and life; however, under certain adverse conditions (in particular, in trauma), they may contribute to the development of a certain multifactorial disease (in particular, traumatic brain disease and its complications) [1].

In particular, one of the factors defining the course of traumatic brain disease was demonstrated to be the presence of a particular allele of the gene encoding apolipoprotein E (*APOE*), which is involved in the lipid metabolic cycle both in the brain and in the body [2, 3]. The role of the *APOE* gene was described in detail in a recent review by A.A. Potapov et al. [4].

On the basis of an experimental model of severe traumatic brain injury in adult and old Wistar rats, E.G. Pedachenko and coauthors demonstrated that administration of the *APOE3*-carrying plasmid vector is associated with significant changes in the morphofunctional state of the hippocampus as well as in neurological and cognitive functions. After analysis of the motor and cognitive functions, a comprehensive morphological, electron microscopic, immunohistochemical, and morphometric analysis of the CA1 hippocampal field was performed on days 5 and 10 after TBI and gene therapy. Animals receiving gene therapy demonstrated faster and more pronounced regression of neurological and cognitive deficits typical of TBI. This was accompanied by a decrease in the intensity of apoptosis (more pronounced in adult animals) in the brain. Introduction of the plasmid vector after TBI significantly increased the survival rate in old rats compared to old animals without gene therapy.

It should be noted that no clear relationship has been established yet between a certain polymorphism and the development of adverse outcomes or complications of TBI. Undoubtedly, further investigation of genetic polymorphism in TBI is crucial for the development of diagnostic algorithms and treatment strategies for traumatic brain disease in order to prevent secondary damage and accelerate recovery of these patients. Therefore, the work of E.G. Pedachenko et al. is topical, interesting to neurologists, neurosurgeons, and specialists in related fields.

E.V. Aleksandrova (Moscow, Russia)

REFERENCES

1. *Baranov V.S.* Genomics on the path to predictive medicine. Acta Naturae 2009; 3: 77—88. In Russian.
2. *Alexander S., Kerr M.E., Kim Y. et al.* Apolipoprotein E4 allele presence and functional outcome after severe traumatic brain injury. J Neurotrauma 2007; 24 (5): 790—797.
3. *Artiga M.J., Bullido M.J., Sastre I. et al.* Allelic polymorphisms in the transcriptional regulatory region of apolipoprotein E gene. FEBS Lett 1998. 421 (2): 105—108.
4. *Potapov A.A., Yusupova M.M., Tenedieva V.D., Nikitin A.G., Nosikov V.V.* Clinical and prognostic value of APOE gene markers in traumatic brain injury. Vopr neirokhir 2010; 3: 54. In Russian.