S.S. Korsakov Journal of Neurology and Psychiatry
2026, vol. 126, no. 3, part 2, pp. 40–45
https://doi.org/10.17116/jnevro202612603240

Evaluation of the neuroprotective activity of Mexidol in a model of hemorrhagic stroke

© A.V. Shchulkin, I.V. Chernykh, S.K. Pravkin, Yu.V. Abalenikhina

I.P. Pavlov Ryazan State Medical University, Ryazan, Russia

Abstract

Objective. To assess the neuroprotective potential of Mexidol with systemic administration in various formulations in a model of hemorrhagic stroke.

Material and methods. The study included 130 outbred male rats weighing between 180 and 200 grams at the age of 7 to 8 weeks. All animals were divided into three sets: Set 1 received intravenous Mexidol at doses of 50 mg/kg and 100 mg/kg; Set 2 received intramuscular Mexidol at the same doses; and Set 3 received Mexidol via oral gavage at doses of 50 mg/kg, 100 mg/kg, and 200 mg/kg. An acute hemorrhagic stroke was induced by administering a volume of 0.05 mL/kg body weight of autologous blood to the internal capsule region of the right hemisphere. Mexidol administration was initiated 30 minutes after the induction of an acute focal stroke. A day post-procedure, the severity of neurological deficits was evaluated using the Stroke-Index McGraw scale, as modified by I.V. Gannushkina. Subsequently, the animals were euthanized, the brain tissues were extracted, fixed in formalin, and underwent tomography.

Results. Intravenous administration of Mexidol at a dose of 100 mg/kg resulted in a statistically significant reduction in the severity of clinical symptoms observed 24 hours post-procedure when compared to control animals. Intramuscular administration produced similar effects at both 50 and 100 mg/kg, whereas intragastric administration was effective at 100 and 200 mg/kg. Notably, intravenous and intramuscular administration at 50 and 100 mg/kg did not significantly alter lesion size in rat brains; in contrast, intragastric administration at 200 mg/kg effectively reduced lesion size.

Conclusions. The findings indicate that Mexidol demonstrates a pronounced neuroprotective effect in cases of small intracranial hematomas, including those persisting post-surgical removal of the primary hematoma.

Keywords: *Mexidol, neuroprotection, hemorrhagic stroke.*

Information about the authors:
Shchulkin A.V. — https://orcid.org/0000-0003-1688-0017
Chernykh I.V. — https://orcid.org/0000-0002-5618-7607
Pravkin S.K. — https://orcid.org/0000-0002-2088-6350
Abalenikhina Yu.V. — https://orcid.org/0000-0003-0427-0967
Corresponding author: Shchulkin A.V. — e-mail: alekseyshulkin@rambler.ru

To cite this article:
Shchulkin AV, Chernykh IV, Pravkin SK, Abalenikhina YuV. Evaluation of the neuroprotective activity of Mexidol in a model of hemorrhagic stroke. *S.S. Korsakov Journal of Neurology and Psychiatry*. 2026;126(3-2):40–45. (In Russ.). https://doi.org/10.17116/jnevro202612603240

Stroke remains the second leading cause of death globally and the leading cause of long-term disability among survivors [1]. Acute ischemic stroke and intracranial hemorrhage (hemorrhagic stroke) are differentiated based on their etiology. Although hemorrhagic stroke occurs less frequently than ischemic stroke, it is associated with higher mortality rates and a limited range of therapeutic interventions available [2].

Irrespective of the stroke type, the imbalance between the metabolic demands of the central nervous system and their corresponding supply triggers a cascade of brain tissue damage and neuronal death. The pathogenesis of ischemic stroke primarily involves a reduction in cerebral blood flow resulting from the occlusion of cerebral arteries or systemic hypoperfusion. Conversely, in hemorrhagic stroke, metabolic failure arises due to the rupture of the vascular wall and subsequent blood loss [3]. The pathophysiological mechanisms underlying ischemic and hemorrhagic strokes present both common features (such as oxidative stress and neuroinflammation) and critical distinctions. Excitotoxicity and intracellular calcium overload are particularly pivotal in ischemic stroke [4, 5]. Hemorrhagic stroke is characterized by initial damage caused by the hemorrhage itself (mass effect), along with secondary damage attributed to the toxic effects of blood components, including iron and thrombin, as well as edema [6].

Mexidol (2-ethyl-6-methyl-3-hydroxypyridine succinate) is a pharmaceutical developed in Russia, recognized for its antihypoxic, antioxidant, and membrane-stabilizing properties [7]. Research demonstrates that Mexidol mitigates glutamate excitotoxicity, inhibits neuroinflammation and apoptosis, and promotes neuroplasticity [8, 9]. Many nonclinical studies have established the efficacy and safety of Mexidol as part of comprehensive therapy for ischemic stroke [7, 9].

In a multicenter, randomized, double-blind, placebo-controlled trial examining the effects of long-term sequential therapy, Mexidol demonstrated statistically significant improvements in patient outcomes during the acute and early recovery phases following hemispheric ischemic stroke. Improvements were noted in the Modified Rankin Scale (mRS) for quality of life, reductions in neurological deficits as assessed by the National Institutes of Health Stroke Scale (NIHSS), and significant

improvements in quality of life as assessed by the EQ-5D questionnaire, alongside a decrease in depressive symptoms as measured by the Beck Depression Inventory [10].

A recent international, multicenter, randomized, double-blind, placebo-controlled, parallel-group study demonstrated the superiority of Mexidol and Mexidol FORTE 250 therapy versus placebo for patients in the acute and early recovery phases of moderate ischemic stroke. The study indicated significant improvements in disability, reduced neurological deficits, enhanced motor function, and increased mobility among the patients [11].

However, few studies have explored the use of Mexidol for the treatment of hemorrhagic stroke [12, 13]. Considering the distinct pathophysiological mechanisms underlying hemorrhagic and ischemic strokes, it is imperative to conduct a thorough nonclinical and clinical evaluation of the effectiveness of Mexidol in addressing this condition.

The objective of the study was to assess the neuroprotective potential of Mexidol with systemic administration in various formulations in a model of hemorrhagic stroke.

Material and methods

The study included 130 outbred male rats weighing between 180 and 200 grams at the age of 7 to 8 weeks. The study protocol received approval from the Bioethics Commission, as documented in Minutes No. 134 dated June 6, 2023.

All animals were divided into three sets: Set 1 received intravenous Mexidol, Set 2 received intramuscular Mexidol, and Set 3 received Mexidol via oral gavage. Sets 1 and 2 were subdivided into four groups: Group 1 comprised intact animals; Group 2 consisted of control animals undergoing induced pathology with an equivalent volume of normal saline administered; and Groups 3 and 4 received Mexidol at doses of 50 mg/kg and 100 mg/kg, respectively

Set 3 was subdivided into five groups: Group 1 comprised intact animals; Group 2 consisted of control animals undergoing induced pathology with an equivalent volume of normal saline administered; and Groups 3, 4, and 5 received Mexidol at doses of 50 mg/kg, 100 mg/kg and 200 mg/kg, respectively Each group included 10 rats. Mexidol was used as a substance (LLC NPK "Pharmasoft," Russia) and diluted in sterile saline (Mospharm LLC, Russia). Animals were randomly allocated to groups based on body weight, ensuring that individual weights did not deviate by more than 10% from the group average.

An acute autohemorrhagic stroke was induced in the internal capsule region of the right hemisphere. The procedure was performed under general anesthesia with chloral hydrate at a dose of 300 mg/kg. After induction of deep anesthesia, blood samples were collected from the rats' tail veins using a syringe. A linear incision of 1.0 cm in the frontal plane was made in the parietal region of the scalp, followed by hemostasis. Subsequently, bone skeletization and periosteal separation were performed. A burr hole, measuring 2 mm in diameter, was made in the right parietal region using a dental drill. Utilizing a puncture needle and stereotactic guidance, the needle was inserted into the internal capsule region at the following coordinates: H=4 mm, L=3 mm, A=1.5 mm from the bregma according to G. Paxinos atlas, to a depth of 3 mm. Using aseptic technique, 0.05 mL/kg of autologous blood was injected via bolus. The occurrence of brainstem seizures was used to assess the injection effect. Then, the puncture needle was withdrawn, and the wound was drained and sutured with hemostatic control. Post-surgery, the animals were housed in large cages with clean sawdust, with five individuals per cage. The sham-operated animals underwent all procedures, except that saline solution was injected into the brain instead of autologous blood. Administration of Mexidol or saline was initiated after the animals regained consciousness from anesthesia, approximately 30 minutes after stroke induction.

Twenty-four hours following the surgical procedure, a comprehensive clinical examination of all animals was conducted to document the clinical manifestations of stroke, using the Stroke-Index McGraw, as modified by I.V. Gannushkina [14]. Subsequently, the animals were euthanized, and brain imaging was performed.

Micro-computed tomography (Micro-CT) of the rat brains was performed at the Center for Nonclinical Research of the First Moscow State Medical University (Sechenov University). The rat brains were fixed in 10% buffered formalin for 48 hours. Post-fixation, the specimens underwent dehydration using graded ethanol concentrations (50%, 70%, 80%, 90%, and 96%), with each solution applied for 1 hour. The brains were then immersed in a 1% iodine solution in 96% alcohol for 14 hours, followed by a 1-hour washout of iodine with 96% alcohol. For the scanning procedure, the samples were placed in a plastic container filled with 96% alcohol. Scanning was conducted at 90 kV and 200 μA, with Al+Cu filters. Image reconstruction was performed using the NRecon software integrated with the Bruker scanner, and rendering was conducted with 3DSlicer. The samples were viewed in a classic black-and-white mode, and brain damage was assessed by measuring the affected area.

Statistical analysis was carried out using GraphPad Prism version 8.1.2. Data are presented as arithmetic means with standard deviations ($M \pm SD$). The significance of differences was evaluated using a one-way analysis of variance (ANOVA) followed by Tukey's post hoc test. The differences at $p<0.05$ were considered statistically significant.

Results

On Day 1 post-surgery, all rats exhibited clinical symptoms indicative of stroke. The total score of neurological disorders was 1.55±0.37 **(table)**.

Intravenous administration of Mexidol at a dose of 100 mg/kg resulted in a statistically significant improvement of clinical symptoms at 24 hours post-surgery compared with control animals, achieving a 54.8% reduction ($p=0.0012$). Neurological deficits in this group of animals did not differ from those in rats subjected to sham surgery. Intramuscular administration of Mexidol also reduced neurological deficits by 31.25% at 50 mg/kg ($p=0.0231$), and by 46.88% at 100 mg/kg ($p=0.0004$). The evaluated indicators in animals receiving both doses of Mexidol were superior ($p<0.05$) to those in animals subjected to sham surgery.

Intragastric administration of Mexidol at 100 mg/kg and 200 mg/kg resulted in a decrease in the severity of neurological deficits compared with control animals, by 43.75% ($p=0.0014$) and 62.5% ($p<0.0001$), respectively. Notably, the neurological status of animals treated with Mexidol at 200 mg/kg was statistically comparable to that of animals subjected to sham surgery ($p>0.05$). Therefore, the findings suggest that Mexidol, when administered through various routes (intravenous, intramuscular, and intragastric), exhibits a dose-dependent neuroprotective effect in models of intracerebral hemorrhage.

Additionally, the study assessed the impact of different administration routes of Mexidol on the size of brain lesions in rats, evaluated 24 hours after the stroke induction, as determined by micro-CT imaging **(table)**.

The effect of intravenous Mexidol on the severity of clinical symptoms and the lesion area in hemorrhagic stroke (*M±SD*)

Route of administration	Group	Behavior, points	Lesion volume, mm³
Intravenous	Control/placebo	1.55±0.37	0.155±0.053
	Mexidol 50 mg/kg	1.05±0.55##	0.12±0.06#
	Mexidol 100 mg/kg	0.7±0.59**	0.107±0.033
	Sham surgery	0.22±0.26****	0.058±0.02****
Intramuscular	Control/placebo	1.60±0.32	0.156±0.047
	Mexidol 50 mg/kg	1.10±0.46*###	0.135±0.043###
	Mexidol 100 mg/kg	0.85±0.41*** ##	0.132±0.045##
	Sham surgery	0.20±0.26****	0.059±0.018****
Intragastric	Control/placebo	1.60±0.21	0.164±0.033
	Mexidol 50 mg/kg	1.30±0.35###	0.137±0.043##
	Mexidol 100 mg/kg	0.90±0.46** ##	0.140±0.044###
	Mexidol 200 mg/kg	0.60±0.52****	0.106±0.045*
	Sham surgery	0.20±0.26****	0.066±0.021****

Note. * — $p<0.05$; ** — $p<0.01$; *** — $p<0.001$; **** — $p<0.0001$ — statistically significant differences versus the control group; # — $p<0.05$; ## — $p<0.01$; ### — $p<0.001$ — statistically significant differences versus to sham-operated animals (ANOVA, Tukey's post-hoc test).

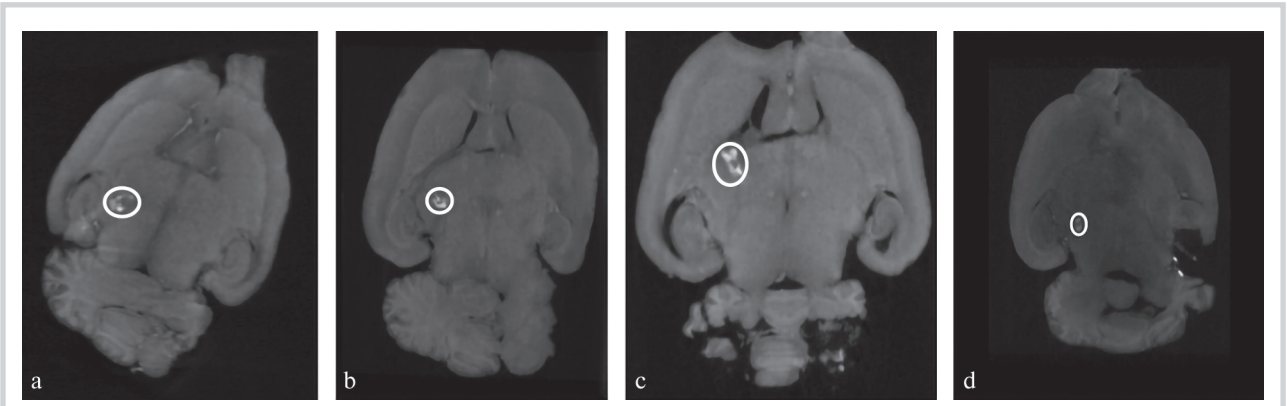

Micro-CT scans of rat brain.
a — sham-operated rat; b, c, d — intragastric administration of Mexidol at 50 mg/kg, 100 mg/kg, and 200 mg/kg, respectively. The circles indicate focal strokes.

CT images of the brains of rats from the control group after focal stroke induction revealed hemorrhagic lesions in the basal ganglia, with volumes of 0.155±0.053 mm³ in animals receiving normal saline intravenously, 0.156±0.047 mm³ in those receiving normal saline intramuscularly, and 0.164±0.033 mm³ in those receiving intragastric administration. Following intravenous administration of Mexidol at doses of 50 mg/kg and 100 mg/kg, the lesions observed in the brains of rats were not statistically different from those observed in control animals; however, there was a tendency toward a reduction in lesion volume at the 100 mg/kg (by 30.96%, $p=0.092$). Furthermore, in the same set, the lesion volume did not differ significantly from that in animals subjected to sham procedures.

The findings reveal that intramuscular administration of Mexidol at all doses tested did not significantly alter lesion volume; it was not statistically different from that in the control group ($p>0.05$) and was higher than that in animals subjected to sham surgery.

The intragastric administration of Mexidol at 50 mg/kg and 100 mg/kg did not significantly alter lesion volume; it was not statistically different from that in the control group ($p>0.05$) and was higher than that in animals subjected to sham surgery. However, the administration of Mexidol at 200 mg/kg resulted in a statistically significant 35.37% reduction in lesion volume ($p=0.0123$) compared to the control, reaching levels similar to those of sham-operated animals, with no significant differences between these groups **(Figure)**. Thus, the results obtained suggest that both intravenous and intragastric administration of Mexidol at higher doses may contribute to a reduction in the volume of lesions in hemorrhagic stroke.

Discussion

Despite notable advancements in the management of acute ischemic stroke, treatment outcomes of intracerebral hemorrhages remain poor. Several factors, including hematoma volume and localization, determine the unfavorable prognosis associated with this condition. Randomized clinical studies have evaluated the potential to limit the size and progression of hemorrhage through methods such as hemostatic interventions, blood pressure reduction, and surgical intervention [15]. However, aside from surgical evacuation of the hematoma in a carefully selected

cohort of patients [16], no other treatment modalities have demonstrated significant improvements in functional outcomes.

Secondary brain injury plays a critical role in both the progression and long-term outcomes of intracranial hemorrhage. Various blood components activate cytotoxic, excitotoxic, oxidative, and inflammatory pathways. Thrombin, iron, and hemoglobin released from the hematoma are principal contributors to secondary brain damage post-intracerebral hemorrhage. Hemorrhagic stroke is associated with neuroinflammation, exacerbating cerebral edema and disrupting the integrity of the blood-brain barrier (BBB) due to the effects of neurotoxic agents such as thrombin, fibrin, and erythrocytes. The accumulation of red blood cells can activate microglia via Toll-like receptor 4 (TLR4), enhancing the secretion of pro-inflammatory cytokines such as TNFα and IL-1β. This emerging inflammatory response leads to leukocyte recruitment through adhesion molecules, further aggravating endothelial damage and tight junction breakdown of the BBB while attracting additional immune cells. Microglia and macrophages phagocytose erythrocytes and cellular debris [3]. The inflammatory response following intracerebral hemorrhage may result in the production of large amounts of free radicals, contributing to exacerbated brain damage. The activation of neutrophils disrupts the respiratory chain and promotes the release of substantial amounts of reactive oxygen and nitrogen species, ultimately resulting in lipid peroxidation. Excessive lipid oxidation alters the physical properties of cellular membranes and may modify proteins and nucleic acids, leading to brain damage. Furthermore, breakdown products of blood cells, such as iron ions and heme, can directly damage brain tissue by generating large amounts of reactive oxygen species [17].

The present study assessed the efficacy of varying doses of Mexidol administered via different routes (intravenous, intramuscular, and intragastric) in an intracranial hemorrhage model. Experimental animals were injected with approximately 10 μl of blood into the internal capsule of the brain, equivalent to approximately 4.4 mL in the human brain, based on a total brain volume of 2.7 mL in rats [18] and 1200 mL in humans [19]. This intracerebral hemorrhage model replicates small residual hematomas that may persist following surgical removal of a thrombus in patients [20]. Notably, only 58% of patients in the MISTIE III trial achieved the specified surgical endpoint of a residual thrombus volume ⩽15 mL [21].

The findings of this study indicate that intravenous, intramuscular, and intragastric administration of Mexidol significantly improves the neurological status of the animals and reduces the lesion volume. The drug was dose-dependent, with a statistically significant effect observed at the maximal dose. The pronounced efficacy of Mexidol may be attributed to its influence on critical pathogenetic mechanisms contributing to brain damage associated with intracranial hemorrhage. Specifically, Mexidol is recognized for its robust antioxidant properties, membrane-stabilizing effects, enhancement of energy production in hypoxic settings, anti-inflammatory actions, inhibition of apoptosis, and stimulation of neuroregeneration [7—9].

Conclusion

The findings indicate that Mexidol demonstrates a pronounced neuroprotective effect in cases of small intracranial hematomas, including those persisting post-surgical removal of the primary hematoma. The administration of Mexidol via both intravenous and intragastric routes effectively reduces neurological deficits and decreases hematoma volume. Therefore, the combined therapy with Mexidol post-surgery for hematoma removal represents a promising approach for the management of hemorrhagic stroke.

Authors contribution: research concept and design — Shchulkin A.V.; animal experiments — Chernykh I.V., Shchulkin A.V.; text writing —Abalenikhina Yu.V., Pravkin S.K.; scientific editing — Shchulkin A.V., Abalenikhina Yu.V., Pravkin S.K.

The authors declare no conflicts of interest.

REFERENCES

1. Feigin VL, Stark BA, Johnson CO, et al. Global, regional, and national burden of stroke and its risk factors, 1990-2019: a systematic analysis for the Global Burden of Disease Study 2019. *Lancet Neurol.* 2021;20(10):1-26. https://doi.org/10.1016/S1474-4422(21)00252-0
2. Kurepina IS, Zorin RA, Zhadnov VA, et al. Nonuniform course of acute period of hemorrhagic stroke: analysis using methods of multivariate stat. *Eruditio Juvenium*. 2021;9(1):59-67. (In Russ.). https://doi.org/10.23888/HMJ20219159-67
3. Maida CD, Norrito RL, Rizzica S, et al. Molecular pathogenesis of ischemic and hemorrhagic strokes: background and therapeutic approaches. *Int J Mol Sci.* 2024;25(12):6297. https://doi.org/10.3390/ijms25126297
4. Kalinin RE, Suchkov IA, Pshennikov AS, et al. Evaluation of Cognitive and Biochemical Brain Status in Patients after Carotid Endarterectomy. *I.P. Pavlov Russian Medical Biological Herald*. 2023;31(4):601-612. (In Russ.). https://doi.org/10.17816/PAVLOVJ585436
5. Campbell BCV, Khatri P. Stroke. *Lancet.* 2020;396(10244):129-142. https://doi.org/10.1016/S0140-6736(20)31179-X
6. Magid-Bernstein J, Girard R, Polster S, et al. Cerebral hemorrhage: pathophysiology, treatment, and future directions. *Circ Res.* 2022;130(8):1204-1229. https://doi.org/10.1161/CIRCRESAHA.121.319949
7. Voronina TA, Litvinova SA, Gladysheva NA, et al. The known and new ideas about the mechanism of action and the spectrum of effects of Mexidol. *S.S. Korsakov Journal of Neurology and Psychiatry*. 2025;125(5):22-33. (In Russ.). https://doi.org/10.17116/jnevro202512505122
8. Shchulkin AV. Effect of mexidol on the development of the phenomenon of the neuronal excitotoxicity *in vitro*. *S.S. Korsakov Journal of Neurology and Psychiatry*. 2012;112(2):35-39. (In Russ.).
9. Shchulkin AV, Chernykh IV, Abalenikhina YuV, et al. The effect of Mexidol on the level of neurogenesis markers in acute cerebrovascular accident in the experiment. *S.S. Korsakov Journal of Neurology and Psychiatry*. 2025;125(2):107-112. (In Russ.). https://doi.org/10.17116/jnevro2025125021107
10. Stakhovskaya LV, Shamalov NA, Khasanova DR, et al. Results of a randomized double blind multicenter placebo-controlled, in parallel groups trial of the efficacy and safety of prolonged sequential therapy with mexidol in the acute and early recovery stages of hemispheric ischemic stroke (EPICA). *S.S. Korsakov Journal of Neurology and Psychiatry.* 2017;117(3-2):55-65. (In Russ.). https://doi.org/10.17116/jnevro20171173255-65
11. Shamalov NA, Fedin AI, Rakhimbaeva GS, et al. Results of the international multicenter randomized, double-blind, placebo-controlled clinical trial for the evaluation of the efficacy and safety of the sequential therapy with ethylmethylhydroxypyridine succinate in patients in the acute and early recovery periods of ischemic stroke (MIR). *S.S. Korsakov Journal of Neurology and Psychiatry*. 2025;125(8-2):40-53. (In Russ.). https://doi.org/10.17116/jnevro202512508240

12. Kurdyumov IN, Gan'shina TS, Maslennikov DV, et al. Influence of mexidol and hemisuccinate 2-ethyl-6-methyl-3-hydroxypyridine on cerebral hemodynamics at hemorrhagic and ischemic damage of brain. *Eksp Klin Farmakol*. 2019;82(5):3-6. (In Russ.).
https://doi.org/10.30906/0869-2092-2019-82-2-3-6

13. Kraineva VA. The experimental study of peculiarities and mechanism of neuroprotective action of mexidol in hemorrhagic stroke. *Bulletin of Experimental Biology and Medicine*.2006;1:40-44. (In Russ.).

14. Gannushkina IV. Pathomorphological mechanisms of cerebral circulation disorders and new directions in their prevention and treatment. *Journal of Neuropathology and Psychiatry*. 1996;(1):14-18. (In Russ.).

15. Krishnan K, Campos PB, Nguyen TN, et al. Cerebral edema in intracerebral hemorrhage: pathogenesis, natural history, and potential treatments from translation to clinical trials. *Front Stroke*. 2023;2:1256664.
https://doi.org/10.3389/fstro.2023.1256664

16. Ratcliff JJ, Hall AJ, Porto E, et al. Early minimally invasive removal of intracerebral hemorrhage (ENRICH): study protocol for a multi-centered two-arm randomised adaptive trial. *Front Neurol*. 2023;14:1126958.
https://doi.org/10.3389/fneur.2023.1126958

17. Shao Z, Tu S, Shao A. Pathophysiological mechanisms and potential therapeutic targets in intracerebral hemorrhage. *Front Pharmacol*. 2019;10:1079.
https://doi.org/10.3389/fphar.2019.01079

18. Pfefferbaum A, Adalsteinsson E, Sullivan EV. In vivo structural imaging of the rat brain with a 3-T clinical human scanner. *J Magn Reson Imaging*. 2004;20(5):779-785.
https://doi.org/10.1002/jmri.20181

19. Allen JS, Damasio H, Grabowski TJ. Normal neuroanatomical variation in the human brain: an MRI-volumetric study. *Am J Phys Anthropol*. 2002;118(4):341-358.
https://doi.org/10.1002/ajpa.10092

20. Tao C, Keep RF, Xi G, Hua Y. CD47 blocking antibody accelerates hematoma clearance after intracerebral hemorrhage in aged rats. *Transl Stroke Res*. 2020;11(3):541-551.
https://doi.org/10.1007/s12975-019-00745-4.

21. Hanley DF, Thompson RE, Rosenblum M, et al. Efficacy and safety of minimally invasive surgery with thrombolysis in intracerebral haemorrhage evacuation (MISTIE III): a randomised, controlled, open-label, blinded endpoint phase 3 trial. *Lancet*. 2019;393(10175):1021-1032.
https://doi.org/10.1016/S0140-6736(19)30195-3

Received 18.02.2026
Accepted 27.02.2026