https://doi.org/10.17116/oftalma202013603110

Choroidal thickness in children with myopia and its changes after surgical strengthening of the sclera

© E.P. TARUTTA, G.A. MARKOSSIAN, A.A. SIANOSYAN, S.V. MILASH

Helmholtz National Medical Research Center of Eye Diseases, 14/19 Sadovaya-Chernogryazskaya St., Moscow, Russian Federation, 105062

ABSTRACT

Purpose — to study the choroidal thickness (CT) in children with myopia and hyperopia and its changes after sclera reinforcement surgeries addressing the progression of myopia.

Material and methods. The study involved 133 patients: 78 children (average age 12.5±0.35 years) with mild hyperopia, low, moderate and high myopia and 55 children with moderate and high myopia who received low invasive scleroplasty (LSP, average age 12.31±0.49 years), or bandaging scleroplasty (BSP, average age 12.59±0.24 years) according to Snyder—Thompson technique and were examined prior to and after the procedure. All patients underwent standard ophthalmologic examination and had choroidal thickness manually measured with EDI-SD-OCT; 55 patients were examined before and 1 week after scleroplasty.

Results. A reduction of CT with refraction growth and axial elongation was found in 78 patients. Among the 55 patients, changes in CT were statistically significant: in the operated eyes, CT increased by 42.5±3.17 μm after LSP and by 62.1±1.06 μm after BSP. In fellow eyes, CT showed an increase of 26.1±1.79 μm after LSP and 33.7±0.55 μm after BSP.

Conclusion. In the early period after sclera strengthening, CT significantly increased both in the operated and in the fellow eye. An increase of CT seems to stimulate the collagen biosynthetic activity of the scleral matrix and the collagen synthesis, and to boost the inhibitory effect that scleroplasty has on the myopia progression.

Keywords: *myopia, choroidal thickness, low-invasive scleroplasty, bandaging scleroplasty.*

INFORMATION ABOUT THE AUTHORS:

Tarutta E.P. — https://orcid.org/0000-0002-8864-4518
Markossian G.A. — https://orcid.org/0000-0002-2841-6396
Sianosyan A.A. — https://orcid.org/0000-0002-1882-0483
Milash S.V. — https://orcid.org/0000-0002-3553-9896
Corresponding author: Sianosyan A.A. — e-mail: alisasianosyan@gmail.com

Vestnik _Oftalmologii_2020-3_10EN

The choroid is a multifunctional structure of the eye which supports the metabolism of the exterior layers of the retina, thermoregulation, the synthesis of growth factors and the regulation of intraocular pressure. Changes in the thickness of the choroid were observed during the development of various diseases, such as age-related macular degeneration, pathological myopia, central serous chorioretinopathy and others [1].

In addition, the important role that the choroid plays in refractogenesis has been revealed [1]: the choroid thickness changes are optically oriented releasing the growth factors, which are part of the cascade of signals going from the retina to the sclera. In an experiment carried out on chicks, Wallman et al. [2] first demonstrated a bidirectional compensatory change in CT in response to optical defocuses of the opposite sign. Particularly, the eyes of the chicks would weaken their refraction by +7,0 D by increasing their CT in response to a myopic defocus, and strengthen it by (–)7,0 D, decreasing their CT in response to a hyperopic defocus. Such a compensatory mechanism which lessens the defocus of an image by changing the CT and thus adjusting the position of the retina towards the focal plane is commonly referred to as "choroidal accommodation".

Experimentally induced reactions in the choroid precede the increased or inhibited growth of the eye of an animal (sclera remodulation) caused by changes in the synthesis of proteoglycans, collagen and matrix metalloproteinase (MMP) activity. Several studies have shown that the choroid can secrete molecules, capable of affecting the synthesis of scleral proteoglycans, and, consequently, be able to regulate the rate of axial elongation [3].

It has been demonstrated in a series of experimental studies that the increase in CT caused by a myopic defocus is accompanied by long-lasting changes in the molecule synthesis of the extra-scleral matrix, as well as a slowing down of axial elongation, or, in other words, the development of myopia [1].

Myopia is known to inhibit blood circulation in both the vascular and retinal membranes, and this defect worsens with the stage of myopia. A failure blood-filling of the uveal tract can, in turn, bring about irreversible retino-choroidal defects and alterations in the optic nerve [4, 6]. It has been proven that as the stage of myopia and axial length increase, the thickness of the choroid decreases [5, 6–8]. Astakhov et al. [5] observed a decrease in CT by an average of 18,03 μm per 1,0 D increase in refraction.

The study of the changes which occur in the choroid in response to various treatments, scleral reinforcement surgery in particular, is of considerable interest. An increase in CT, retained for 6-9 months after scleroplasty, was observed in an experiment carried out by Mirzayants et al. [9]: by a factor of 3–4 in treated eyes and 2-3 in fellow eyes. Such research has not yet been done in clinical practice.

The aim of our research is to study the CT in children with myopia and hyperopia, as well as its changes after scleral reinforcement operations on progressive nearsightedness.

Material and methods

A total of 133 patients were examined: 78 children and adolescents between the ages of 6 and 17 (mean age 12,5±0,35 years) with various refraction values: 14 subjects had hyperopia (+1,29±0,26 D on average) and 64 had myopia: 22 with mild myopia ((–)1,9±0,57 D), 20 with moderate myopia ((–)4,63±0,67 D) and 22 people with high myopia ((–)7,43±1,02 D). Among the subjects were 55 patients suffering from mild and high myopia, whose CT was measured before and after a scleral reinforcement operation.

All patients underwent a standard ophthalmological examination, which included a visual acuity test and refractometry under natural conditions, as well as under cycloplegia, pneumotonometry, biomicroscopy and optical biometry. Additionally, apart from the main examinations, the choroid thickness in the subfoveal area was measured using a Nidek OCT-RS-3000 Advance device.

The examination of the choroid thickness was carried out on a undilated pupil both prior to and after a scleral reinforcement operation: a low-invasive scleroplasty (LSP), carried out on 25 patients (mean age – 12,13±0,49 years; moderate or acute myopia – from (–)3,72 to (–)6,5 D), while a bandaging scleroplasty (BSP) in accordance with the Snyder-Thompson method was performed on 30 patients (mean age – 12,59±0,24 years; acute myopia ranging from (–)6,75 to (–)16,0 D). The LSP was carried out with the use of ophthalmological polyester tricot with a biologically active chitosan coating. The BSP was performed with the use of a cadaver sclera. The patients were examined before and 1 week after their surgical procedures. Data on both the treated eye and its pair was considered.

The statistical analysis was carried out with the SPSS Statistics 22.0 software package (Statistical Package for the Social Sciences for Windows, version 22.0. IBM Corp., USA). Continuous variables are represented by $M \pm SD$, where M is the arithmetic mean and SD is the standard deviation. The normality of the distribution was checked using the Shapiro-Wilk test. The differences between samples with a normal distribution were analyzed using Student's t-test for independent samples and dependent paired samples. The significance level was taken to be 0,05 (α=0,05), which is the traditional value for medical and biological research. The differences were considered valid for a confidence level of $p<0,05$. High-value differences for $p<0,01$ were mentioned separately.

Results and discussion

The data on the choroidal thickness in children with various types of refraction can be found in **Tab. 1 and 2**.

As seen in Tab. 1,2, an increase in refraction and axial length causes a decrease in CT.

Thus, the CT would amount to 350±14,95 μm for low hyperopia **(Fig. 1)**, 245,2±20,85 μm ($p<0,01$) for myopia in general, 269±26,18 μm for low myopia, and 226,2±38,85 μm ($p<0,05$) for high myopia **(Fig. 2–4)**.

Over the course of this study, 2 children with congenital high myopia ((–)14,0 and (–)16,0 D) and an increased axial length of 27,9 and 29,4 mm were found to have an extremely low CT: 42 and 83 μm respectively **(Fig. 5, a, b)**.

The CT values in children before and after the undertaken surgical operations are shown in **Tab. 3 and 4**.

It is worth noting the difference in initial CT values between the groups of children who underwent LSP and BSP. In the first case, the CT was considerably larger by 77,2 μm. This correlates with the much lower stage of myopia and axial length in this group ((-)5,42±0,4 and (-)8,71±0,69 D; 25,38±0,42 and 26,71±0,3 mm respectively), which is what determined the choice of sclera reinforcement method.

The CT in both groups increased following scleroplasty, by 42,5±3,17 μm ($p<0,01$) after LSP and 62,1±1,06 μm ($p<0,01$) after the Snyder-Thompson method of BSP. This difference does not seem at all random, considering

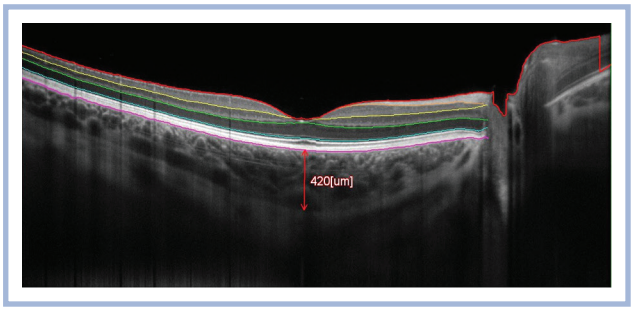

Fig. 1. **Choroidal thickness in hypermetropia.**

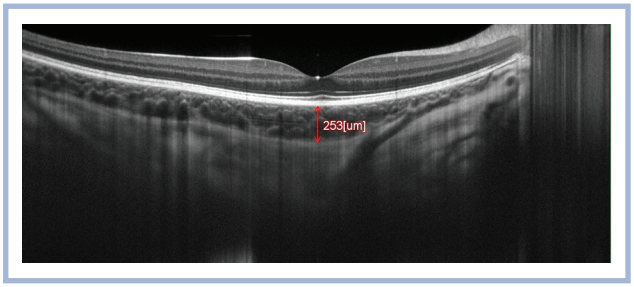

Fig. 2. **Choroidal thickness in low myopia.**

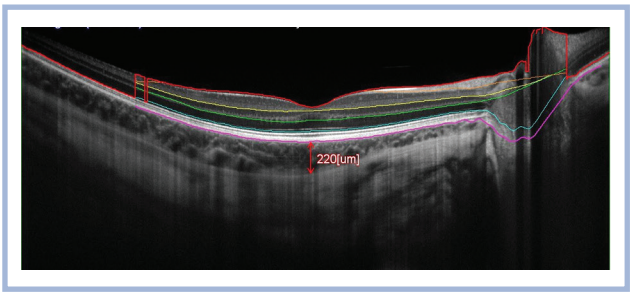

Fig. 3. **Choroidal thickness in moderate myopia.**

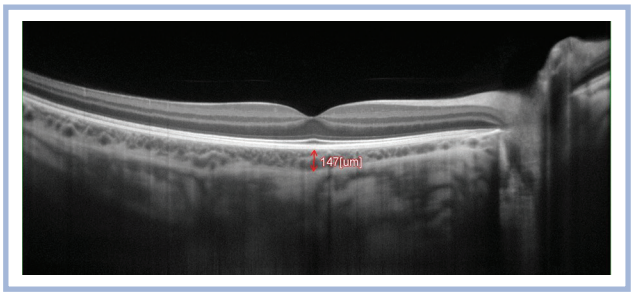

Fig. 4. **Choroidal thickness in high myopia.**

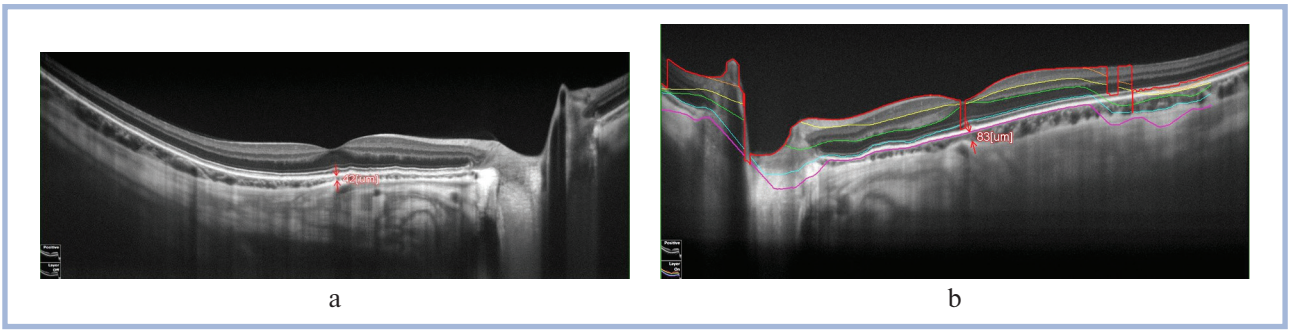

Fig. 5. **Choroidal thickness in congenital high myopia in 2 patients (a, b).**

the difference in the level of surgical intervention. In the first case, a 5×12 mm synthetic and partially resorbable transplant was implanted, whereas the second case involved a 10×50-56 mm resorbable allosclera transplant. At the same time, the CT of the untouched pair eye also increased by 26,1±1,79 μm (p>0,05) in the LSP group and by 33,7±0,55 μm (p<0,05) in the BSP group **(Fig. 6 and 7)**.

In our opinion, the fact that an increase in CT was observed in both the treated eye and its pair after BSP, as well as after LSP (which itself does not involve stretching the transplant nor positioning it at the exit zones of vorticose veins) allows us to exclude a possible connection that an increase in choroidal blood filling might have to the compression of said veins.

There are 3 factors in the scleroplastics working mechanism, regardless of the method and type of plastic material: the mechanical reinforcement of the sclera, its revascularization, and the tissue biostimulation by the transplant [10–14]. The aseptic inflammation and immune reaction which develop post-surgery are accompanied by a dispersion of physiologically active (and, particularly, vasoactive) substances, which stimulate haemodynamics and the regeneration of blood vessels in the sclera and other tissue surrounding the transplant, as well as trigger several biosynthetic and metabolic processes in these tissues [4]. Even though they are less observable, such reactions do obviously occur in the fellow eye as well, in the form of an oculo-ocular reflex. Following the performance of various scleral reinforcement surgeries, Tarutta et al. [15] established an improvement in haemodynamic readings in both the treated eye and its pair. This study showed that the degree of improvement in the rheographic index was

Table 1. **Choroidal thickness (μm) in hypermetropia and myopia**

Refraction	Age, years	Amount of eyes	Spherical equivalent, D, $M\pm m$	Axial length, mm, $M\pm m$	CT in the sub-macular area, $M\pm m$
Hyperopia	10,0±1,17	14	+1,29±0,26	22,17±0,20	350±14,95
Myopia	11,85±1,4	64	–4,65±0,44	25,3±0,46	245,2±20,85*

Note. *p<0,01 in comparison to hyperopia.

Table 2. **Choroidal thickness (μm) in low and high myopia**

Refraction	Age, years	Amount of eyes	Spherical equivalent, D, $M\pm m$	Axial length, mm, $M\pm m$	CT in the sub-macular area, $M\pm m$
Low myopia	10,55±2,1	22	–1,9±0,57	24,39±0,39	269±26,18
High myopia	14,1±2,46	22	–7,43±1,02	26,2±0,98	226,2±38,85*

Note. *p<0,05 in comparison to low myopia.

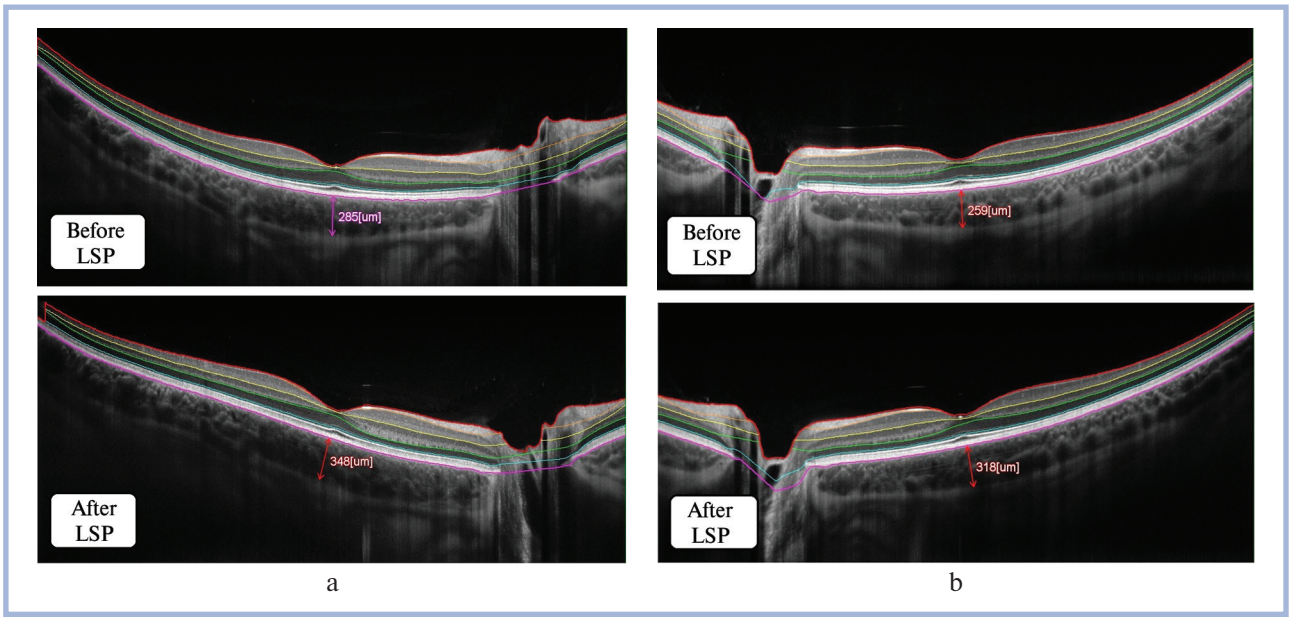

Fig. 6. **Choroidal thickness in the operated (a) and fellow (b) eye before and after BSP.**

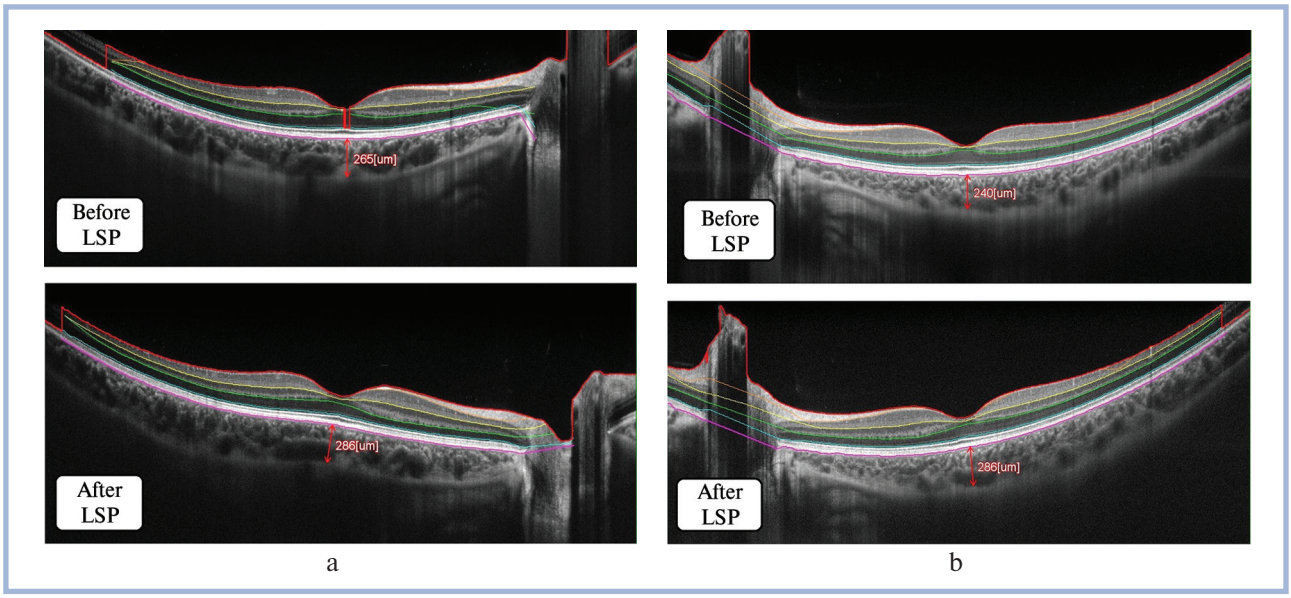

Fig. 7. **Choroidal thickness in the operated (a) and fellow (b) eye before and after LSP.**

Table 3. **Choroidal thickness (μm) before and after LSP**

Spherical equivalent, D		Axial length, mm		CT in the sub-macular area, μm			
				before LSP		1 week after LSP	
TE (*n*=25)	FE (*n*=25)	TE	FE	TE	FE	TE	FE
–5,42±0,4	–4,96±0,35	25,38±0,42	25,29±0,35	275,5±8,13*	292,8±8,5**	318±11,3*	318,9±10,33

Note. TE – treated eye, FE – fellow eye, *n* – amount of eyes.; * – $p<0,01$; ** – $p>0,05$

Table 4. **Choroidal thickness (μm) before and after BSP according to Snyder—Thompson technique**

Spherical equivalent, D		Axial length, mm		CT in the sub-macular area, μm			
				before BSP		1 week after BSP	
TE (*n*=30)	FE (*n*=30)	TE	FE	TE	FE	TE	FE
–8,71±0,69	–8,21±0,75	26,71±0,3	26,54±0,2	198,3±13,21**	207,8±10,1*	260,4±14,27**	241,5±10,65*

Note. TE – treated eye, FE – fellow eye, *n* – amount of eyes; *$p<0,05$, **$p<0,01$.

directly proportional to the extent of the surgical invasion and the amount of implanted material.

Recently, an opinion on the existence of this oculo-ocular phenomenon has been brought forth, describing it as a complex set of traits which characterize a reaction of a pair eye occurring under unilateral ophthalmo-pathology of various genesis, including trauma and surgery [16]. Many studies note reduced progression of myopia and improvements in the anatomo-functional characteristics of pair eyes, which had not been operated on. Among these were enhanced haemodynamics, which would gradually increase over the course of the first 6 months after surgery in both the treated eye and its untouched pair, and which would then smoothly fade and return to their initial condition within a year after the procedure [13, 17–21]. This fact led to the development of an algorithm for scleral reinforcement treatment for progressive myopia in children, involving a series of operations on an eye pair with periods of 1-1,5 years in between, rather than undertaking several immediate ones [21, 22].

All of the listed aspects of the mechanism behind scleroplasty were not only confirmed experimentally, but were also established in clinical trials, which showed an increase in the strength parameters of the sclera, regional haemodynamics and the functional activity of treated eyes [12, 23, 24]. Many researchers hold that scleroplasty can thicken the sclera, provide new vascular ingrowth and improve the bloodstream at the posterior pole [25–28]. Libman et al. [19] discovered an intensive increase in pulse volume in the rheo-ophthalmographic data recorded during the first few months after Nesterov-Belyaev scleroplasty: the rheographical coefficient was 1,8 times larger than its initial value. After taking rheo-ophthalmographical, ophthalmoplethysmographical and ophthalmo-sphygmographical measurements, Antipova found a significant improvement of haemodynamic readings in the first 6 months following scleroplasty: a 23% increase in the rheographical coefficient, a twofold increase in overall pulse volume, and a threefold increase in pulse volume of the arterio-capillary network. Abnizova also notes an increase of the rheographical coefficient 6 months following Pivovarov scleroplasty, attributing it to the transplanted allosclera acting as a biogenic stimulant, activating metabolic processes in the eye and initiating an immune response from the recipient organism. A similar explanation was offered by Levchenko et al. [10], who likewise observed an increase in the rheographical coefficient in the first 6 months after scleroplasty. Ivashina and Mikhaylova noted an increase in linear blood circulation rates along the optic artery 3 months after Snyder-Thompson scleroplasty, which correlated with the surgery results [23, 24].

Fyodorov et al. [29], who recorded an increase in CT after vascular reconstructional surgery under high myopia (according to data from ultrasound scans), point out that this observation signifies an improvement in the blood filling of the choroidea. In previous years, other authors have also highlighted that choroidal circulation is directly connected to CT: a decrease in the former leads to a decrease in the latter and vice versa.

In a recent study [30], optical coherent tomography with angiography was used to determine that scleral reinforcement surgery does not, in fact, worsen the haemodynamics of the treated eye, rather evidently stabilizing it over a lengthy period of time.

In his thoughts on the general mechanisms behind scleroplasty, Kornilovsky [4] underlined the fact that the process of biodestruction and replacement of the transplant, occurring together with a reaction of cellular elements and the secretion of physiologically active substances, stimulate the synthesis of collagen in the sclera. It is then obvious that such reactions lead to an increase in the haemic saturation of the choroid, which is manifested in its thickening. Experimental research of the last decades has shown that the choroid plays an important role in the homeostatic control of eye growth [1]. The choroid changes its thickness when exposed to various visual and pharmacological stimulants. This is then followed by a change in the secretion of different mediators, which directly affect the biosynthetic activity of the sclera, thereby accelerating or slowing down the elongation of the eye. An increase in the thickness of the choroid is accompanied by a slowing down of eye growth, i.e. a retardation of its myopization. All of this can give a new explanation for the slowing down of myopia progression. Scleroplasty does not just induce an extra-scleral stimulation of biosynthesis of collagen in the sclera with physiologically active substances and the products of transplant biodegradation. It also causes a direct trans-choroidal remodeling of the scleral matrix, which raises the biosynthesis of collagen and strengthens the sclera. This is, quite possibly, the new explanation for how the mechanism of scleroplasty works.

Conclusion

1. Optical coherent tomography is an informative method of monitoring myopia in children.

2. The CT in children reduces as the axial length and refraction of the eye increase: by an average 104,8 μm for myopia in general in comparison to hyperopia, and by 42,8 μm for high myopia in comparison to moderate myopia.

3. An evident increase in CT was noted after scleroplasty: by an average 42,5±3,17 μm ($p<0,01$) after LSP and 62,1±1,06 μm ($p<0,01$) after BSP. An increase in CT was also registered in the unoperated fellow eyes, by 26,1±1,79 μm ($p>0,05$) and 33,7±0,55 μm ($p<0,05$), respectively.

4. The increase in CT which was established after surgery is, quite possibly, responsible for an increase in biosynthetic activity of sclera collagen, due to a remodeling of the scleral matrix. This, in turn, significantly contributes to the inhibitory effect of scleroplasty on myopia.

The authors declare no conflicts of interest.

ЛИТЕРАТУРА/REFERENCES

1. Nickla DL, Wallman J. The multifunctional choroid. *Progr Retinal Eye Res.* 2010;2:144-168. https://doi.org/10.1016/j.preteyeres.2009.12.002
2. Wallman J, Wildsoet C, Xu A, et al. Moving the retina: choroidal modulation of refractive state. *Vision Res.* 1995;35(1):37-50.
3. Rada JA, McFarland AL, Cornuet PK, et al. Proteoglycan synthesis by scleral chondrocytes is modulated by a vision dependent mechanism. *Curr Eye Res.* 1992;11:767-782.
4. Kornilovskiy IM. Pathogenetic aspects of stabilization of myopia after scleroplastic operation. *Oftal'mologicheskiy zhurnal.* 1987;6:343-347. (In Russ.).
5. Astakhov YuS, Belekhova SG. Choroidal thickness in eyes with different degress of myopia. *Oftal'mologicheskie vedomosti.* 2013;4:34-38. (In Russ.).
6. Katsnel'son LA, Forofona TI, Bunin AYa. Anatomiya sosudistoi sistemy glaza. In: *Sosudistye zabolevaniya glaza.* M.: Meditsina; 1990. (In Russ.).
7. Zal'tsman M. Sosudistaya obolochka. In: *Anatomiya i gistologiya chelovecheskogo glaza.* M.; 1913. (In Russ.).
8. Avetisov SE, Budzinskaya MV, Zhabina OA, et al. Fluorescein angiography and optical coherence tomography findings in central fundus of myopic patients. *Vestnik oftal'mologii.* 2015;(4):38-48. (In Russ). https://doi.org/10.17116/oftalma2015131438-48
9. Mirzayants MG, Pristavko EF, Pivovarov NN. O mehanizmah lechebnogo deistviya operacii ukrepleniya sklery. In.: *Reconstructive ophthalmosurgery.* M. 1979. (In Russ.).
10. Levchenko OG. *Progressiruyushaya blizorukost u detei.* Tashkent: Meditsina; 1985. (In Russ.).
11. Bagrov SN, Ronkina TI, Balashova NKh, et al. Experimental and clinical substantiation of collagen-based scleroplasty. *Oftal'mohirurgiya.* 1991;(4):48-55. (In Russ.).
12. Krasnikov PG, Antonova AI. The influence of alloscleroplastic operations on the state of visual functions in persons with high myopia and various stages of chorioretinal dystrophy. *Oftal'mologicheskiy zhurnal.* 1985;(3):156-158. (In Russ.).
13. Tarutta EP, Iomdina EN, Markosyan GA. Transpalpebral rheoophthalmography as a method for evaluating the effectiveness of sclera-strengthening and trophic treatment of progressive myopia. *Oftalmologiya.* 2018;15(4):439-446. (In Russ.). https://doi.org/10.18008/1816-5095-2018-4-439-446
14. Svirin AV, Antipova OA, Serebryakova TV. The administration of a homogenated tissue suspension into the interfacial space of patients with high progressive myopia. *Vestnik oftal'mologii.* 1984;(4):31-33. (In Russ.).
15. Tarutta EP, Markosyan GA, Sianosyan AA, et al. Choroidal thickness in varied types of refraction and its changes after sclerastrengthening surgeries. *Rossiyskiy oftalmologicheskiy zhurnal.* 2017;10(4):48-53. (In Russ.). https://doi.org/10.21516/2072-0076-2017-10-4-48-53
16. Zueva MV, Slepova OS, Gundorova RA, et al. Classification oculo-ocular reactions in severe mechanical injury to the eye according to the electrophysiological and immunological studies. *Refrakcionnaja hirurgija i oftal'mologija.* 2007;(1):35-41. (In Russ.).
17. Babeshko LB, Pisarenko SL. Experience of introduction and results of scleroplastic operations on occasion of high progressive myopia. *Oftal'mologicheskiy zhurnal.* 1986;(3):158-159. (In Russ.).
18. Tarutta EP. A choice of scleroplastic therapy of progressive myopia in children. *Vestnik oftal'mologii.* 1992;(2):10-13. (In Russ.).
19. Bochkareva ZG, Libman ES, Belyaev VS, Melkumyants TA. Clinical and functional condition of the eye with high complicated myopia after scleroplastic operations. *Vestnik oftal'mologii.* 1980;(6):32-36. (In Russ.).
20. Kagermazova NKh, Zakharov VD. Prevention of progression of myopia by scleroplasty. *Oftal'mologicheskiy zhurnal.* 1975;(7):485-488. (In Russ.).
21. Tarutta EP. Pathogenetically validated system of diagnostics, prevention and sclera-reconstructive treatment in pathologic myopia. *Rossiyskaya pediatricheskaya oftal'mologiya.* 2008;(1):25-28. (In Russ.).
22. Tarutta EP, Iomdina EN, Ahmedjanova EV. Progressing myopia in children: does it need to treatment or not? *Vestnik oftal'mologii.* 2005;121(2):5-8. (In Russ.).
23. Svirin AV, Antipova OA. Remote results of introduction of allotissues into tenons space in progressive myopia. *Oftal'mologicheskiy zhurnal.* 1984;(8):471-472. (In Russ.).
24. Mikhaylova GD, Ivashina AI, Shilkin GA. Theuse of Doppler ultrasound in ophthalmology. *Oftal'mologicheskiy zhurnal.* 1981;(7):411-415. (In Russ.).
25. Ward B, Tarutta EP, Mayer MJ. The efficacy and safety of posterior pole buckles in the control of progressive high myopia. *Eye.* 2009;23(12):2169-2174. https://doi.org/10.1038/eye.2008.433
26. Zhu SQ, Zheng LY, Pan AP, et al. The efficacy and safety of posterior scleral reinforcement using genipin cross-linked sclera for macular detachment and retinoschisis in highly myopic eyes. *Brit J Ophthalmol.* 2016;100(11):1470-1475. https://doi.org/10.1136/bjophtalmol-2016-309731
27. Xue A, Bao F, Zheng L, et al. Posterior scleral reinforcement on progressive high myopic young patients. *Optometry Vision Sci.* 2014;91(4):412-418. https://doi.org/10.1097/OPX.0000000000000201
28. Zhu Z, Ji X, Zhang J, et al. Posterior scleral reinforcement in the treatment of macular retinoschisis in highly myopic patients. *Clin Exper Ophthalmol.* 2009;37:660-663. https://doi.org/10.1111/j.1442-9071.2009.02111.x
29. Федоров С.Н., Иоффе Д.И., Свердлова З.Ю. и др. Хирургическая коррекция гемодинамики у больных с осложненной миопией высокой степени. *Офтальмохирургия.* 1990;(1):12-14. Fedorov SN, Ioffe DI, Sverdlova ZYu, et al. Surgical correction of hemodynamics in patients with high complicated myopia. *Oftal'mohirurgiya.* 1990;(1):12-14. (In Russ.).
30. Mo J, Duan AL, Chan SY, et al. Application of optical coherence tomography angiography in assessment of posterior scleral reinforcement for pathologic myopia. *Int J Ophthalmol.* 2016;9:1761-1765. https://doi.org/10.18240/ijo.2016.12.10

Received 16.05.19
Accepted 27.05.19