https://doi.org/10.17116/oftalma202013602113

Experimental study of hyaluronic acid gel fillers biodegradation in orbit

© Y.O. GRUSHA[1, 2], A.A. FEDOROV[2], J.U. PRAUSE[3], O.V. EKSARENKO[2], V.A. SHEPTULIN[2]

[1]I.M. Sechenov First Moscow State Medical University (Sechenov University), Department of Ophthalmology, 8-2 Trubetskaya St., Moscow, Russian Federation, 119991;
[2]Research Institute of Eye Diseases, 11A Rossolimo St., Moscow, Russian Federation, 119021;
[3]Eye Pathology Institute, University of Copenhagen, 11 Frederik V's Vej, Copenhagen, Denmark, 2100

ABSTRACT

Introduction. Recently, hyaluronic acid gel (HAG) fillers were proposed as an effective alternative treatment option for surgical orbital volume augmentation. Several authors reported about long-standing effect of the filler.
Purpose — to assess the features of HAG biodegradation after intraorbital injection in experimental environment.
Material and methods. In the course of the experiment, 7 chinchilla rabbits (14 eyes) received a single 1ml intraorbital HAG injection (Restylane SubQ, Galderma, Sweden) using a cannula. The animals' orbits were examined by ultrasound scan after the injection and at 1, 3, 6, 9, 12 and 18 months. The animals were subsequently sacrificed for morphological study of orbital tissue containing the HAG filler.
Results. The HAG filler persisted in the orbit of experimental animals during the whole follow-up period. The volume of HAG depot and its density diminished gradually till the 18th month, after which the particles of HAG could still be detected with the morphological study and ultrasound.
Conclusion. The HAG filler persisted in the orbit of experimental animals up to 18 months. Incomplete biodegradation explains the longstanding duration of the injection effect.

Keywords: *injectable fillers, hyaluronic acid, intraorbital injection, neocollagenogenesis, rabbit.*

INFORMATION ABOUT THE AUTHORS:

Grusha Y.O. — https://orcid.org/0000-0002-6461-8243; e-mail: grusha-y@mail.ru
Fedorov A.A. — e-mail: fean-doc@mail.ru
Prause J.U. — e-mail: jup@dadlnet.dk
Eksarenko O.V. — https://orcid.org/0000-0002-0714-0730; e-mail: dr.olesea@mail.ru
Sheptulin V.A. — https://orcid.org/0000-0002-5709-4795; e-mail: vsheptulin@gmail.com
Corresponding author: Sheptulin V.A. — https://orcid.org/0000-0002-5709-4795; e-mail: vsheptulin@gmail.com

Vestnik _Oftalmologii_2020-1_EN

Today, injectable implants (fillers) based on stabilized hyaluronic acid gel (HAG) are successfully used in plastic surgery and cosmetology in the presence of aesthetic defects associated with soft tissue deficiency after trauma or surgery. The high hydrophilicity of hyaluronic acid allows it to maintain the necessary hydration of the intracellular matrix ensuring the required volume of tissues, as well as their stability and elasticity [1, 2]. In ophthalmoplasty, HAG has become widespread as a minimally invasive method of treating patients with pathological conditions such as lagophthalmos, retraction and anomalies in the location of the eyelids, and enophthalmos. Also, various modifications of the filler with particles of 400 and 2000 μm were used depending on the area of filler injection. The efficacy and safety of HAG has been proven in a number of clinical studies [3–7].

In Russia, HAG fillers have been successfully used for the correction of lagophthalmos in endocrine ophthalmopathy and paralytic lagophthalmos, dry eye syndrome, soft tissue defects in the orbital and periorbital regions, as well as in the correction of enophthalmos in silent sinus syndrome – when this method is effective and justified in a severe somatic status of a patient or their refusal of surgical treatment [8–11]. These fillers have become an alternative to existing surgical techniques (including injection) with the implantation of materials for the correction of lagophthalmos and enophthalmos [12, 13].

Manufacturers have noted for the effect of the injection to preserve for up to 12–18 months on average. However, in a number of publications and in the course of clinical work, it was noticed that in some patients, when the drug is injected into the orbit, the clinical effect persists for a longer time. An earlier experimental study of intrapalpebral HAG administration has demonstrated the morphological features of drug biodegradation in the eyelid tissues and long-term retention of the filler in the form of a cellular structure were [14]. These results suggest the presence of similar morphological features when the filler stays for prolonged time after injection into the orbit.

The purpose of the study was to evaluate the features of HAG biodegradation after its intraorbital administration in experimental animals.

Material and methods

The pilot prospective non-comparative study included 7 Chinchilla rabbits (14 eyes) (average age 1.5 years, average body weight 4 kg). Each rabbit was housed in an individual steel cage under supervision of a vivarium employee. All manipulations were approved by the local ethical committee of the Federal State Budgetary Institution of Science "Research Institute of Eye Diseases". The hair covering the upper eyelid was removed with scissors. All animals received a single 1 ml injection of HAG with large particles (Restylane Sub-Q Lidocaine, Q-med AB, Sweden). The hair covering the lower eyelid was sheared with scissors and the injection site was treated with 96% ethanol solution. Under local anesthesia with eutectic mixture of local anesthetics (EMLA cream), a 1–2 mm long skin incision was made with a blade in the lateral third in the projection of the lower edge of the right orbit; the injection into the extraconal space was performed according to the standard method of retrobulbar injection using an original 21G cannula (Pix'l) **(Fig. 1, a)**. A slight exophthalmos was noted on the injection side after the procedure.

All experimental animals underwent ultrasonic digital scanning of the orbit immediately after the injection of the drug, as well as after 1, 3, 6, 9, 12 and 18 months using a VOLUSION E8 device (Kretz) equipped with a linear SP 10-16 MHz probe and a 5-12 MHz RSP volume probe. As a contact medium, a conventional contact gel for ultrasound examinations (Aquasonic by Parker, U.S.A.) was used. Ultrasound examination was performed in a standard horizontal position of the animal on its stomach through closed eyelids, avoiding pressure on the eyeball. The scanning depth was 6–7 cm; a minimum filter value was set at 50 Hz. The examination was carried out after injection, as well as after 1, 3, 6, 9, 12 and 18 months. The contralateral side remained as a control.

Ultrasound was performed according to the following algorithm: at the first stage in the B-mode (grayscale). Scanning was carried out sequentially in three projections, after which a three-dimensional scan of the visible HAG depot in the retrobulbar part of the orbit was performed. An RSP volumetric probe (5–12 MHz) was used for ultrasonic spatial scanning. The sensor surface was oriented the same way it was during 2D scanning. In the third step, the acoustic density (MG) was estimated using a 3D color histogram by comparing the number of color elements in the volumetric image with the number of elements in the volumetric image of the gray scale. The final stage was multiplanar analysis, i.e. volumetric remodeling and further spatial analysis of the studied object in three orthogonal planes mutually perpendicular to each other.

Each animal was withdrawn from the experiment at specific time using an intramuscular injection of Zoletil 100 at a lethal dose of 100 mg/kg after 1, 3, 6, 9, 12 and 18 months. The criteria for excluding experimental animals were: death, external signs of the disease (lethargy, hair loss, sudden loss of body weight, secretion on visible mucous membranes). All animals completed the study according to the protocol.

The animals underwent exenteration of the orbit according to the standard technique including isolation of the filler depot from the surrounding tissues and their subsequent cryofixation at the pathomorphological department of the Federal State Budgetary Institution "National Medical Research Center For Obstetrics, Gynecology And Perinatology Named After Academician V.I.Kulakov". The choice of the cryofixation technique is attributed to the dissolution of the studied filler outside the capsule during its preparation for morphological examination. Sections 8–9 μm thick were stained with hematoxylin and eosin (H&E), alcian blue without MgCl2 (Ab) (staining for non-sulfated glycosaminoglycans) and with 0.8 mol MgCl2 (0.8 mol Ab) (staining for sulfated glycosaminoglycans), Periodic acid–Schiff (PAS), and hematoxylin phloxine saffron (HPS), as well as Mowry colloidal iron stain (CIS) at the Institute of Eye Pathology, University of Copenhagen, Denmark, with their subsequent assessment and photo registration using Leica DM2500 photomicroscope (Leica, Germany).

Results of ultrasound of soft tissues of the orbit of experimental animals

According to the ultrasound data, immediately after the injection, a depot was revealed in the lower posterior part of the orbit, located extraconally between the lower and lateral rectus muscles. The filler depot had hypoechoic structure, the average volume of which remained stable **(Fig. 2, a)**. A gradual decrease in the size of the depot structures in the orbits of experimental animals was noted up to the 18th month of remote observation (from 0.96±0.04 to 0.51±0.05 cm3; $p<0.05$). One month after the injection, signs of an uneven hyperechoic contour were detected around the filler, and after 3 months – hyperechoic inclusions in the filler depot, respectively. The hyperechoic contour and inclusions were visualized continuously during the 18 months of remote observation.

When assessing the acoustic density of the filler structure in comparison with the surrounding tissues (orbital tissue, extraocular muscles, vitreous body), its relative stability was noted during 12 months of remote observation to be 66±4 c.u. with a subsequent decrease by the 18th month after injection to 50±7 c.u., which could indicate the ongoing biodegradation of the filler. Similar acoustic density of the HAG and fatty tissues was also noted **(Fig. 2, b)**. During the entire observation period, there were no blood vessels in the projection of the hypoechoic formation.

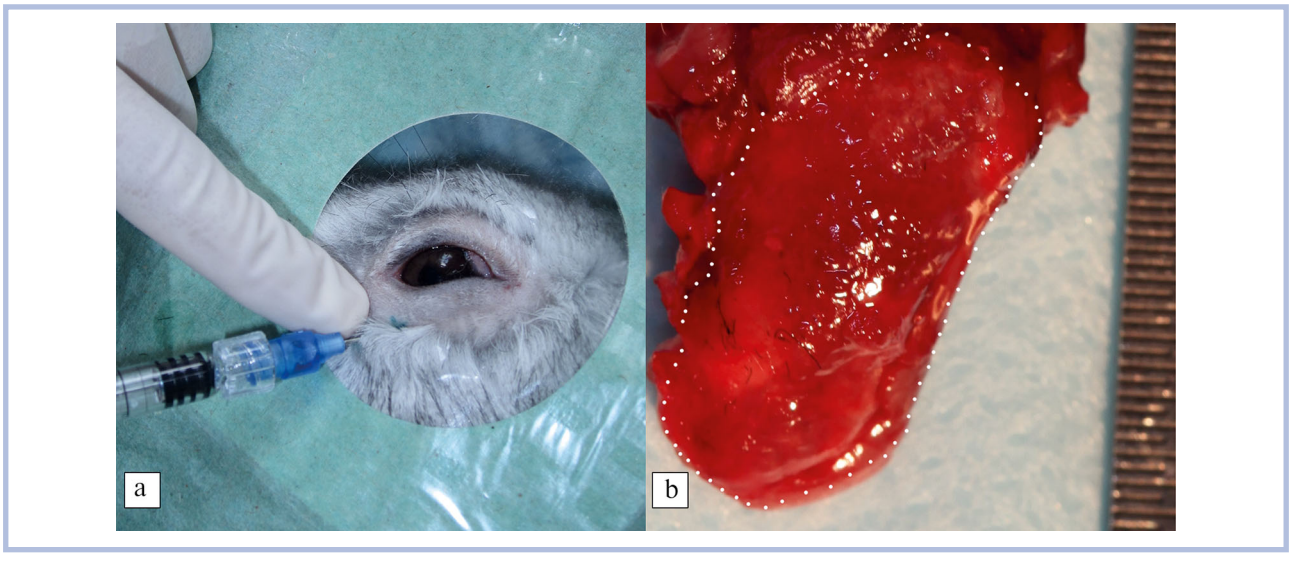

Фрагмент содержит депо с видимым ГГК (белый пунктир) и окружающими мягкими тканями орбиты через 6 мес после инъекции.

Fig. 1. **Method of animal preparation and intraorbital injection of the filler (a); macro-photo of a removed fragment of soft orbital tissues (b).**
The fragment contains a depo with visible HAG particles (white dotted line) and surrounding soft orbital tissues 6 months after the injection.

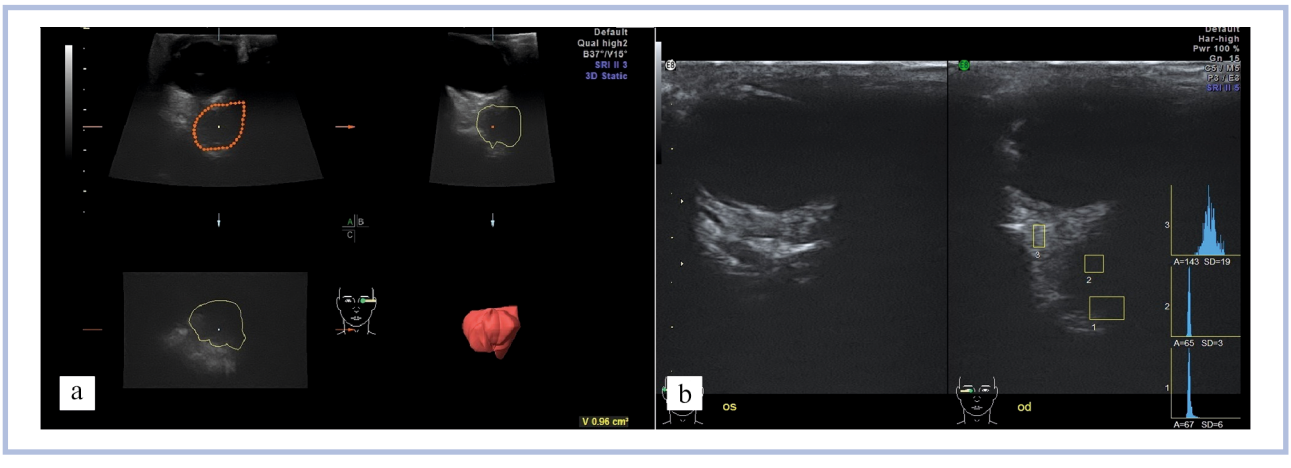

Fig. 2. **Ultrasound scan of the experimental animal immediately after HAG injection.**
a — virtual 3D model of the depo with injected filler by multiplanar analysis; b — comparative densitometric study of the texture of relatively homogenous parts of the planar section of retrobulbar fatty tissue (histogram 1), HAG depo (histogram 2), optic nerve (histogram 3).

Results of morphological study of the soft tissues of the orbit of experimental animals

In a morphological study, HAG filler with large particles (2000 μm) (Restylane SubQ), injected into the orbit of experimental animals, was visualized throughout the entire period of remote observation. Macroscopically, the preparation was a gel-like structure with a bluish tinge, enclosed in a connective tissue capsule and surrounded by orbital tissue. Rounded translucent masses were determined during transillumination **(see Fig. 1, b)**. The preparation was basophilic stained with H&E, weakly positive for PAS reaction and positive for Ab and CIS staining.

After 1 month. At this point there is a thickening of the tissues around the preparation and the surrounding fatty tissue. The HAG filler is surrounded by a poorly differentiated capsule (pseudocapsule), which, apparently, is represented by a local compaction of hypercellular tissues surrounding it. Attention was drawn to the absence of clear cellular structure. The administered filler was practically in its native form in high concentration **(Fig. 3, a b)**. There were no signs of an inflammatory reaction.

After 3 months. The injected filler is still surrounded on all sides by a thin fibrocellular pseudocapsule. Signs of neocollagenogenesis were observed in the peripheral parts of the filler depot, and active fibroblasts were found in the thickness of connective tissue growths from the sur-

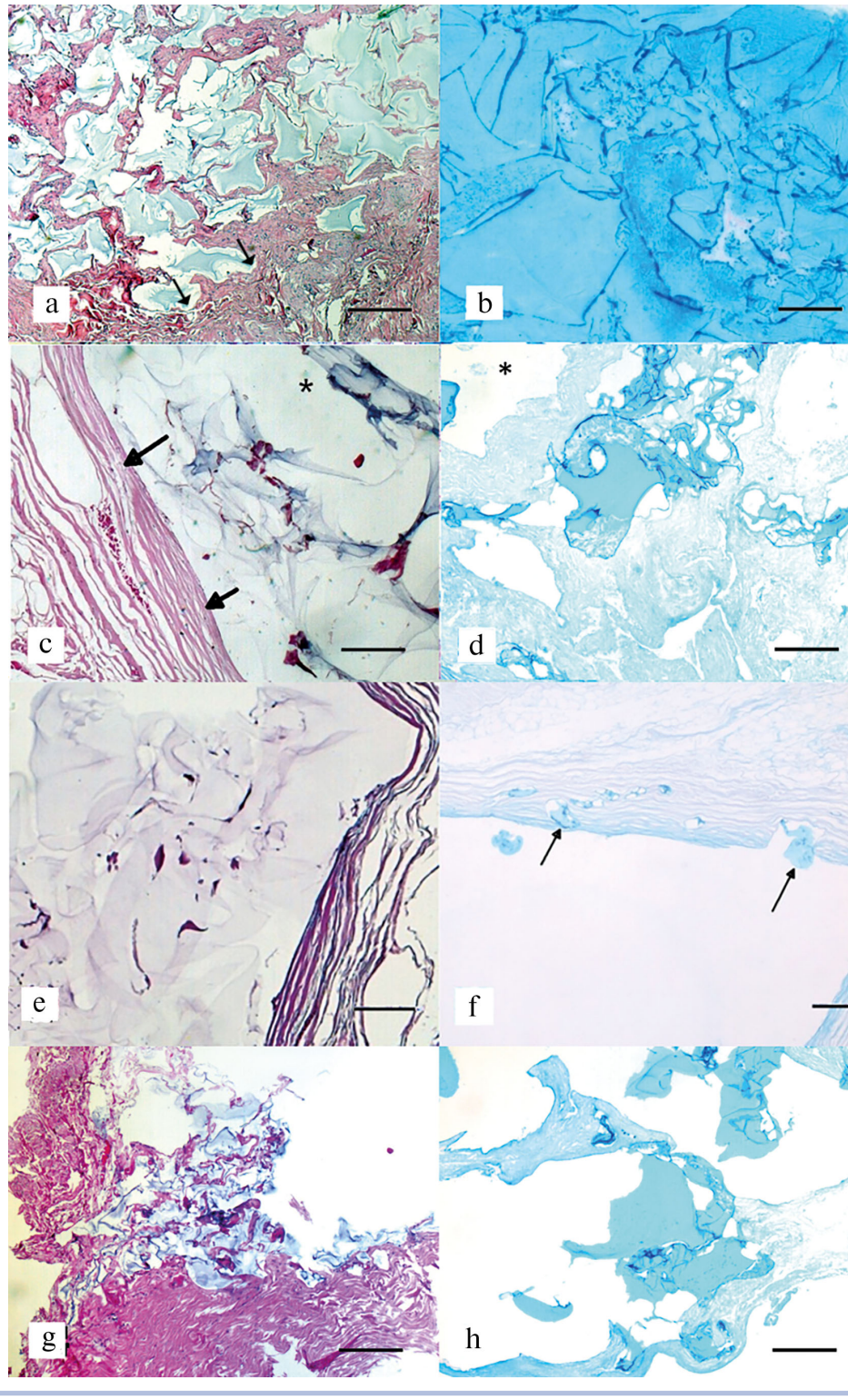

Fig. 3. **Results of histological study of the specimen at various observation times.**

a, b — peripheral segments of the HAG depo 1 months after the injection, local induration of surrounding tissues (marked with arrows); c, d — the HAG depo 6 months after the intraorbital injection, nonuniform thickness of the pseudocapsule wall (marked with arrows) surrounding HAG and inclusions of connective tissue; e, f — migration of filler particles with the foam cells through the pseudocapsule wall in the process of biodegradation (marked with arrows); g, h — peripheral segments of the HAG depo 1.5 years after the injection. a, c, g — H&E staining; b, d, h — Ab staining; e — Schiff staining; f — colloidal iron staining (CIS); scale bars 100 μm.

rounding tissues. HAG was still visualized in a form close to native, at a lower concentration compared to the previous observation period.

After 6 months. The pseudocapsule surrounding the injected HAG is clearly visualized at this point. It has thickened unevenly throughout. The form of the preparation is close to the native one, its concentration has decreased due to natural replacement by the intercellular fluid **(see Fig. 3, c d)**.

Of interest is the discovered fact of capture by foamy cells and migration of individual HAG particles outside the pseudocapsule in the course of phagocytosis **(see Fig. 3, e, f)**.

After 9 months. The pseudocapsule septum has become more tortuous along its entire length. In the peripheral sections, there are "blind pockets" delimiting the injected filler, which is in practically unchanged form. Visible fibroblasts support the process of neocollagenogenesis in the pseudocapsule border areas.

After 12 months. One year after the injection, the HAG filler still persists, it is surrounded by a pseudocapsule. The drug is clearly visualized at the periphery of the depot in cell-like structures. In the central region, the filler is surrounded by optically transparent cavities and remains at a much lower concentration. The fibrogenesis process is not complete.

After 18 months. The depot area is delimited from the surrounding tissues by an uneven hypocellular capsule. The filler depot is shrinking. Despite a significant reduction in volume according to light optical microscopy data, filler particles are visualized parietally at the border of the capsule **(see Fig. 3, g, h)**.

Discussion

Recently, large particles HAG fillers have found application in augmentation of orbital volume deficit for correction of conditions such as retraction of the eyeball in enophthalmos of various etiology or a prosthesis in anophthalmic syndrome, deepening of the upper orbital-palpebral fold. The classical approach usually involves the implantation of various allogenic materials such as porous polytetrafluoroethylene, sea coral hydroxyapatite, demineralized allograft bone, carbon felt, or autologous materials (e.g. fat) [15]. However, it is often the case that many patients with this problem have a history of multiple previous surgeries and would prefer an alternative, less invasive intervention. Thus, injection methods of correction have been proposed and remain relevant to this day, alongside with surgeries placing traditional implants.

One of these methods of correction was autologous fat injected intra- or extraconally, as well as periorbitally. Despite the advantages of this method (no rejection, allergic reactions or the formation of granulomas), its disadvantages include the complexity of technical preparation, the unpredictable duration of the effect, the need to repeat the procedure and, consequently, the risk of inflammatory complications [16, 17].

Another method of correction was injection of calcium hydroxyapatite in patients with anophthalmic syndrome. Despite the high biocompatibility of the drug, the absence of an allergic reaction and a significant duration of the effect – 6 to 18 months on average, 4 cases of drug dislocation into the lower eyelid have been described, as well as the absence of possibility of drug destruction when the effect is unsatisfactory [18].

In this regard, large particle gels based on hyaluronic acid became the drug of choice, meeting the necessary safety criteria, while having acceptable duration of effect, biocompatibility and a minimal risk of migration. According to a number of authors, the duration of the effect of intraorbital injection also remained different. R. Malhotra described the preservation of the positive effect until the 9th month of long-term follow-up, J. Olver noted the duration of 6 months after injection on average. The authors recommended peribulbar injection of a local anesthetic (bupivacaine) prior to direct administration to minimize the risk of vasovagal reactions due to oculocardial reflex in intraconal HAG administration [4]. However, on the other hand, the use of anesthesia does not allow correct calculation of the volume of the filler. In this regard, in patients with enophthalmos, we gave preference to HAG that already contains 0.3% lidocaine, and its extraconal placement.

As a probable reason for the prolongation of the effect of intraorbital injection, O. Crochelet and co-authors noted that HAG may be more stable in less mobile areas – in the case of anophthalmic syndrome; however, in our work, the effect of the injection was retained in patients without anophthalmic syndrome. The described works also raised the question of the correlation of the administered volume of the filler with the achieved correction effect [19–21].

According to the data of histological and ultrasound studies, despite the biodegradation of the injected filler and a decrease in the density and volume of its depot, it was retained 1.5 years after injection. The histological picture was similar to that with intrapalpebral administration [14]. However, due to the poverty of the connective tissue component, the active process of fibrogenesis with the proliferation of connective tissue septa as in the eyelids was not observed. The process was slowed down and proceeded mainly in the peripheral parts of the filler depot, directly adjacent to the zone of compaction of the surrounding tissues. Connective tissue inclusions found in the central sections of the depot most likely appeared upon injection of the filler and rupture of connective tissue pockets with fatty tissue.

The injection method of filling the deficit in the volume of the orbit of various etiology using fillers based on HAG seems to be a simple and promising alternative to surgical intervention. However, it is necessary to remember the possibility of complications, including iatrogenic damage to the eyeball or blindness due to intravascular administration of the filler. Despite

the absence of signs of damage to the vascular bed of the eyeball in the form of orbital hematomas or ischemic necrosis in the preparations, the possibility of such complications nevertheless exists. Recent major systematic reviews indicate low efficacy in the treatment of these conditions [22, 23]. In order to minimize or eliminate them, a standardized filler injection algorithm should be strictly followed, especially in areas with an increased risk from an anatomical point of view and mandatory examination using modern radiological diagnostic method. Particular care should be taken when this method is used in patients with previous interventions in orbit, deep-set eyes, elderly patients with involutional changes in periocular tissues [24].

The authors declare no conflicts of interest.

ЛИТЕРАТУРА/REFERENCES

1. Matarasso SL, Carruthers JD, Jewell ML. Consensus recommendations for soft-tissue augmentation with nonanimal stabilized hyaluronic acid (Restylane). *Plast Reconstr Surg.* 2006;117(3):3-34. https://doi.org/10.1097/01.prs.0000204759.76865.39
2. Comper WD, Laurent TC. Physiological function of connective tissue polysaccharides. *Physiol Rev.* 1978;58:255-315.
3. Malhotra R. Deep orbital sub-Q Restylane (Nonanimal stabilized hyaluronic acid) for orbital volume enhancement in sighted and anophthalmic orbits. *Arch Ophth.* 2007;125:1623-1629. https://doi.org/10.1001/archopht.125.12.1623
4. Tay E, Olver J. Intraorbital hyaluronic acid for enophthalmos. *Ophthalmology.* 2008;115:110-112. https://doi.org/10.1016/j.ophtha.2008.02.015
5. Goldberg RA, Fiashetti D. Filling the orbital hollows with hyaluronic acid gel: initial experience with 244 injections. *Ophthal Plast Reconstr Surg.* 2006;22:335-341. https://doi.org/10.1097/01.iop.0000235820.00633.61
6. Goldberg RA, Lee S, Jayasundera T, et al. Treatment of lower eyelid retraction by expansion of the lower eyelid with hyaluronic acid gel. *Ophthal Plast Reconstr Surg.* 2007;23:343-348. https://doi.org/10.1097/iop.0b013e318137aa41
7. Taban M, Mancini R, Nakra T, et al. Nonsurgical management of congenital eyelid malpositions using hyaluronic Acid gel. *Ophthal Plast Reconstr Surg.* 2009;25(4):259-263. https://doi.org/10.1097/iop.0b013e3181ac984b
8. Катаев М.Г. Применение имплантов внутридермальных Реплери на основе гиалуроновой кислоты для заполнения объема и коррекции дефектов мягких тканей орбитальной и периорбитальной области при анофтальме и наличии глаза. Практическая медицина. *Офтальмология.* 2012;04(12):194-198.
Kataev MG. Use of Repleri hyaluronic acid injectable implant as a fuller and corrector of and periorbital region soft tissues defects in case of anophthalmos and eye presence. Prakticheskaya meditsina. *Oftal'mologiya.* 2012;04(12):194-198. (In Russ.).
9. Grusha Y, Khovrin V, Stoyukhina A, Sheptulin V. Hyaluronic Acid Gel Re-Injection for Enophthalmos Correction in Silent Sinus Syndrome. *Orbit.* 2015;34(6):351-353. https://doi.org/10.3109/01676830.2015.1078376
10. Feldman I, Sheptulin VA, Grusha YO, Malhotra R. Deep Orbital Sub-Q Hyaluronic Acid Filler Injection for Enophthalmic Sighted Eyes in Parry-Romberg Syndrome. *Ophthalmic Plast Reconstr Surg.* 2018;34(5):449-451. https://doi.org/10.1097/IOP.0000000000001050
11. Груша Я.О., Агафонова Е.И., Исмаилова Д.С., Иванченко Ю.Ф. Первый опыт применения препарата стабилизированной гиалуроновой кислоты для коррекции лагофтальма. *Вестник офтальмологии.* 2010;1:39-42.
Grusha YO, Agafonova EI, Ismailova DS, Ivanchenko YuF. The first experience in using the stabilized hyaluronic acid preparation to correct lagophthalmos. *Vestnik oftal'mologii.* 2010;1:39-42. (In Russ.).
12. Атаманов В.В., Бурилов К.Б. *Способ устранения западения верхнего века при анофтальме Способ ранней диагностики вторичной плацентарной недостаточности.* Патент РФ на изобретение. Ссылка активна на 28.01.19.
Atamanov VV, Burilov KB. *Sposob ustraneniya zapadeniya verkhnego veka pri anoftal'me.* Patent RF na izobretenie №2342107/ 27.12.08. Accessed 28.01.19. (In Russ.). http://www.freepatent.ru/patents/2342107
13. Каспаров А.А., Грязнова И.И., Важди А.С. Способ формирования мягкой опорно-двигательной культи после энуклеации. *Вестник офтальмологии.* 1984;3:36-39.
Kasparov AA, Gryaznova II, Vazhdi AS. Formation of locomotor stump after enucleation. *Vestnik oftal'mologii.* 1984;3:36-39. (In Russ.).
14. Груша Я.О., Федоров А.А., Prause J.U., Шептулин В.А. Экспериментально-морфологическое исследование тканей век после введения геля гиалуроновой кислоты. *Вестник офтальмологии.* 2015;131(1):69-74.
Grusha YaO, Fedorov AA, Prause JU, Sheptulin VA. Histopathological study of experimental intrapalpebral injection of hyaluronic acid gel. *Vestnik oftal'mologii.* 2015;131(1):69-74. (In Russ.). https://doi.org/10.17116/oftalma2015131169-74
15. Груша Я.О., Федоров А.А., Баранов П.Ю., Бакаева Т.В., Павлюк А.С. Исследование пространственной структуры и биоинтегративных характеристик орбитальных пористых имплантационных материалов. *Вестник офтальмологии.* 2010;126(5):9-13.
Grusha YaO, Fedorov AA, Baranov PIu, Bakaeva TV, Pavliuk AS. Study of the three-dimensional structure and biointegrative characteristics of porous orbital implant materials. *Vestnik oftal'mologii.* 2010;126(5):9-13. (In Russ.).
16. Gutierrez ML, Pe-Yan MR, Ortiz AC, Cruz JJ. Use of autologous-fat graft in postenucleation-socket syndrome. *Philipp J Ophthalmol.* 2009;34(2):70-73.
17. Cakir B, Aygit AC, Omur-Okten O. Retro-orbital intraconal fat injection: an experimental study in rabbits. *J Oral Maxillofac Surg.* 2012;70(1):242-250. https://doi.org/10.1016/j.joms.2011.02.091
18. Vagefi MR, McMullan TF, Burroughs JR, et al. Injectable calcium hydroxlapatite for orbital volume augmentation. *Arch Facial Plast Surg.* 2007;9:439-442. https://doi.org/10.1001/archfaci.9.6.439
19. Carruthers J, Carruters A. Facial sculpting and tissue augmentation. *Dermatol Surg.* 2005;31:1604-1612. https://doi.org/10.2310/6350.2005.31248
20. Crochelet O, Maalouf T, Duron S, Froussart F, Rigal-Sastourné JC, George JC. Efficacy and tolerability of highly crosslinked hyaluronic acid injections in the management of the enophthalmous orbit. *Journal français d'ophtalmologie.* 2012;35:441-447. https://doi.org/10.1016/j.jfo.2012.04.005
21. Zamani M, Thyagarajan S, Olver JM. Adjunctive use of hyaluronic acid gel (Restylane Sub-Q) in anophthalmic volume deficient sockets and phthisical eyes. *Ophthal Plast Reconstr Surg.* 2010;26(4):250-253. https://doi.org/10.1097/iop.0b013e3181ba76f5
22. Paap M, Milman T, Ugradar S, et al. Examining the Role of Retrobulbar Hyaluronidase in Reversing Filler-Induced Blindness: A Systematic Review. *Ophthalmic Plast Reconstr Surg.* 2019. [Epub ahead of print] https://doi.org/10.1097/IOP.0000000000001568
23. Zhang LX, Lai LY, Zhou GW, et al. Evaluation of Intraarterial Thrombolysis in Treatment of Cosmetic Facial Filler-Related Ophthalmic Artery Occlusion. *Plast Reconstr Surg.* 2020;145(1):42-50. https://doi.org/10.1097/PRS.0000000000006313
24. Груша Я.О., Федоров А.А., Шептулин В.А. *Инъекционные имплантаты на основе геля гиалуроновой кислоты при патологии придаточного аппарата глаза.* М.: ГЭОТАР-Медиа; 2017.
Grusha YO, Fedorov AA, Sheptulin VA. *In'ektsionnye implantaty na osnove gelya gialuronovoi kisloty pri patologii pridatochnogo apparata glaza.* M.: GEOTAR-Media; 2017. (In Russ.).

Received 22.10.19
Accepted 13.11.19