Russian Journal of Clinical Dermatology and Venereology
2025, Vol. 24, No. 1, pp. 72–80
https://doi.org/10.17116/klinderma20252401172

Treatment of benign familial chronic pemphigus with omalizumab

© M.B. DROZHDINA[1], S.V. KOSHKIN[1], P.V. GORODNICHEV[2]

[1]Kirov State Medical University, Kirov, Russia;
[2]Nizhny Novgorod Branch of the State Scientific Center of Dermatovenereology and Cosmetology, Nizhny Novgorod, Russia

ABSTRACT
Benign familial chronic pemphigus is a rare genodermatosis that has a significant impact on the quality of life of patients, currently incurable. Lack of unified clinical guidelines, diversity of methods of local and systemic therapy that do not give a pronounced long-lasting effect, cause researchers' interest and necessity to find new therapeutic tactics for managing this disease. It is known that IgE-mediated pathological mechanisms promote degranulation of mast cells and basophils and stimulate Th2 immunity, that plays a leading role in creating protection against many diseases. It has been proven not so long ago that IgE autoantibodies are involved in autoimmune responses. Such autoimmune reactions include direct tissue damage, activation and migration of basophils to lymph nodes, and induction of type 1 interferon reactions, opening new possibilities for developing previously untried therapy methods. We present a series of clinical cases — 5 patients with benign familial chronic pemphigus of different localization, total IgE level above reference values (>100 mIU/ml), who positively responded to subcutaneous administration of omalizumab in a dosage of 300 mg on 0, 4, 8, 12, 16, 20, 24, 28, 32, 36, 42 weeks.
Objective — to demonstrate the effectiveness of a new method for benign familial chronic pemphigus treatment in a series of clinical cases.

Keywords: *benign familial chronic pemphigus, total immunoglobulin E, omalizumab, series of clinical cases.*

INFORMATION ABOUT THE AUTHOR:
Drozhdina M.B. — https://orcid.org/0000-0002-7689-8350
Koshkin S.V. — https://orcid.org/0000-0002-6220-8304
Gorodnichev P.V. — https://orcid.org/0000-0001-5989-7156
Corresponding author: Drozhdina M.B. — e-mail: drozhdina@yandex.ru

TO CITE THIS ARTICLE:
Drozhdina MB, Koshkin SV, Gorodnichev PV. Treatment of benign familial chronic pemphigus with omalizumab. *Russian Journal of Clinical Dermatology and Venereology*. 2025;24(1):72–80. (In Russ.). https://doi.org/10.17116/klinderma20252401172

List of abbreviations.
BP — bullous pemphigoid
PV — pemphigus vulgaris
BFP — benign familial pemphigus
BD — bullous dermatoses
DLQI — dermatological life quality index
IgE — immunoglobulin E
PDAI — index of severity degree and lesion area in pemphigus
Th1, Th2 — type 1 and 2 helper T lymphocytes

Introduction

Lack of uniform understanding of the mechanisms of benign familial pemphigus (BFP) pathogenesis affects the disunity of therapeutic tactics for managing this disease. At the present time, BFP treatment includes systemic and topical antibiotics, corticosteroids, cyclosporin, methotrexate and dapsone for patients with torpid to performed therapy cases [1-4]. No common clinical guidelines for management of patients with BFP are available.

IgE-mediated pathological mechanisms are known to promote degranulation of mast cells and basophils and stimulate Th2 immunity, that plays a leading role in creating protection against many diseases. Not so long ago it has been proven that IgE auto-antibodies participate in autoimmune responses. Such autoimmune responses include direct tissue damage, basophil activation and migration to the lymph nodes and induction of type 1 interferon reactions [5, 6].

On the principle that multiple pathological mechanisms form the basis of BFP, it is not always possible to find the main factor causing the disease. We found significantly high total serum IgE levels, correlating with the the pathological process severity in examination of 24 patients with BFP [4]. Treatment with omalizumab, a recombinant humanized monoclonal antibody targeted at FcεRI IgE, can be a promising approach to this disease control. It is reported about the efficacy of omalizumab in bullous pemphigoid associated with the presence of autoreactive IgE antibodies. Hypothesis that an allergen may not be required for some IgE-mediated allergic reactions has been recently considered (e.g., there are a conformation of the Fv domain on the mast cells or direct contact of the IgE-FcRI complex with each other), precise mechanisms of IgE level regulation are unclear. Transcription factors that activate or inhibit the IgE gene and cytokines of Th1 and Th2 lymphocytes play the most important role in these complex processes [2, 6, 7].

Omalizumab has demonstrated a good therapeutic effect in idiopathic urticaria and bronchial asthma, obstinate to standard treatment [8-10]. The drug has a favorable benefit-risk profile.

It is a recombinant humanized monoclonal antibody of IgG1 subclass that binds to IgE-specific epitopes within the C3 (FcεRI-binding) region of the IgE molecule, thus reducing the amount of free IgE, which is the triggering factor for the cascade of allergic reactions [11]. Notably, the precise mechanism of omalizumab action in patients with idiopathic spontaneous urticaria, bronchial asthma and BFP is unknown.

Objective — to demonstrate the efficacy of a new method of BFP treatment in a series of clinical cases.

Presentation of case series

The series of clinical observations involved 5 volunteers with Gougerot — Hailey — Hailey BFP during the disease exacerbation, moderate and severe course with a certain total serum IgE level of more than 100 mIU/mL. Pemphigus Disease Area Index (PDAI) amounted to 11—35. Age of patients was 37—60 years. No contraindications to the use of omalizumab have been revealed. All patients signed voluntary informed consent for omalizumab application.

Patients were injected with 300 mg of omalizumab subcutaneously during weeks 0, 4, 8, 12, 16, 20, 24, 28, 32, 36, 42.

We present 2 clinical cases from this series of observations.

Patient *N.*, 59 years old. Complaints of painful, itchy rash on the axillary cavities' skin, in the inguinofemoral and inguinoscrotal folds, perianal area. Rash is accompanied by strong unpleasant odor. Medical history: patient suffers from BFP within a period of 35 years with continuously relapsing course and severe exacerbations in summer time. He repeatedly received courses of systemic antibiotic therapy (doxycycline, ceftriaxone) with temporary improvement and relapse 1 month after the therapy completion. Subject initiated medication of methotrexate at a dose of 10 mg/week, allergic reaction with signs of urticaria and furuncles in the buttocks area occurred after the second injection. The drug was discontinued, the patient applied topical therapy using akriderm GK ointment with minor improvement. He has noticed significant deterioration during the last year, topical therapy has ceased to be effective.

Polymorphism of the rash is defined on the skin of the above mentioned anatomical areas: pronounced hyperemia, multiple papular elements, merging into plaques with a diameter up to 10 cm, infiltration, fissures, oozing lesion. Positive «brain convolutions» symptom. The examination was performed, severity of the pathological process was determined, PDAI — 16 (moderate course), dermatological life quality index (DLQI) — 12.

Results of physical, laboratory and instrumental examinations

The total IgE level was 254,2 mIU/mL before therapy initiation. No clinically significant changes have been found in the complete blood count, common urine analysis and biochemical blood test. Results of histological study and clinical manifestations of the process before the initiation and dynamics in the treatment process are presented in **the fig. 1—4**.

Differential diagnosis

Differential diagnosis of BFP is usually performed with Darier disease, mycoses of the skin folds and pemphigus vegetans. The histological study has revealed pathognomic signs of BFP (suprabasal gaps and acantholytic cells, lining the walls of clefts and lying freely in them — «half-ruined brick wall»).

Treatment

Treatment was done after signing the informed voluntary consent by the proposed method: subcutaneous administration of omalizumab at a dose of 300 to the patient during weeks 0, 4, 8, 12, 16, 20, 24, 28, 32, 36, 42. Course consisted of 11 injections.

Outcome and results of follow-up

There has been a significant improvement in clinical picture during the treatment on the 4th week of monotherapy with omalizumab: all fissures were epithelialized, oozing lesion phenomena resolved, PDAI decreased to 6, DLQI decreased to 4 **(see fig. 1).** PDAI and DLQI amounted to 3 and 2, respectively, on the 8th week of therapy, PDAI 1 and DLQI 0 — on the 12th. Persistent effect without exacerbation at the 32nd week of omalizumab monotherapy, PDAI 1 (secondary hyperpigmentation in the perineal region and the inguinoscrotal folds preserved), the DLQI 0 **(see fig. 2, 3).**

The total IgE level was measured in patient during the treatment. The indicator amounted to 302,8 mIU/mL at the 4th week (before omalizumab injection), 387,2 mIU/mL — at the 8th week, 403,1 mIU/mL — at the 12th week, 408,4 mIU/mL — at the 42nd week. There were no relapses of the disease during the follow-up for 4 months after the completion of treatment with omalizumab **(see fig. 4).** The patient applied mometasone furoate ointment, econazole, gentamicin, panthenol (Tetraderm) to the skin folds' area every other day as a supportive treatment after the completion of omalizumab therapy.

Patient *K.*, 60 years old. Complaints of painful, moist rash on the skin of the axillary cavities, in the in-

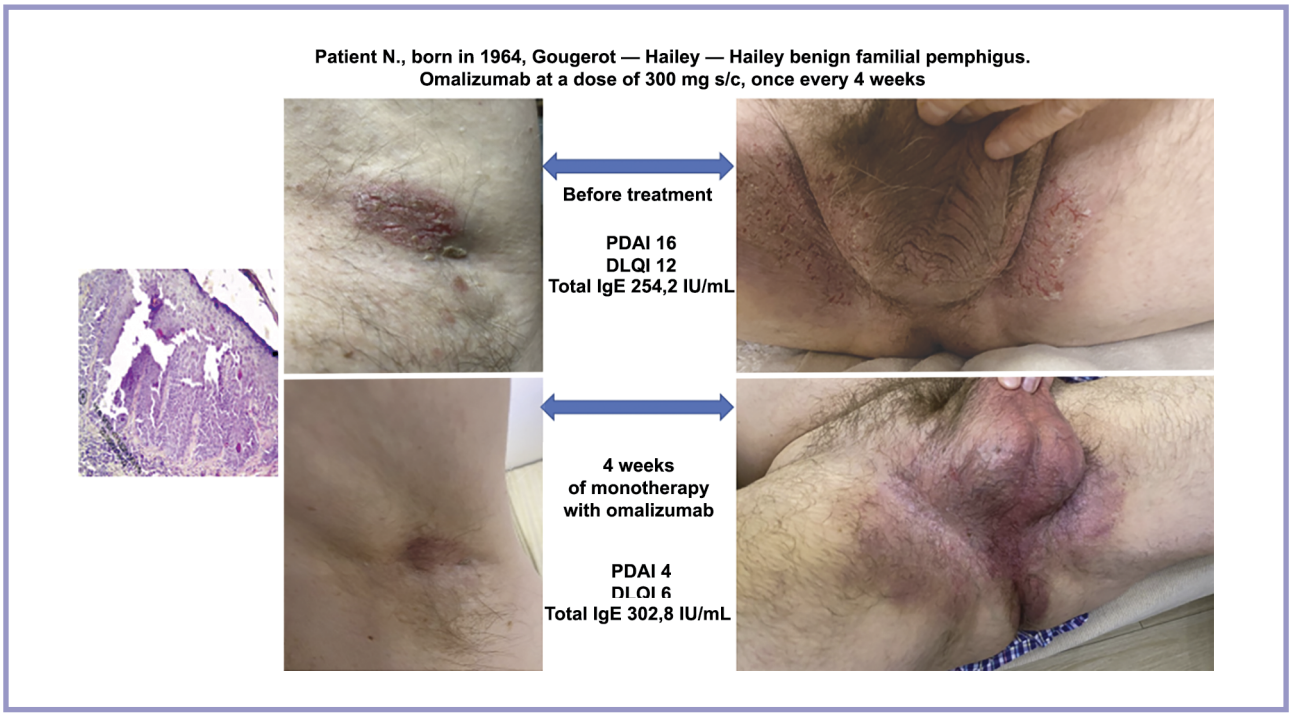

Fig. 1. **Patient *N.*, 59 years old. Histological picture and clinical manifestations before the initiation and during the treatment with omalizumab.**

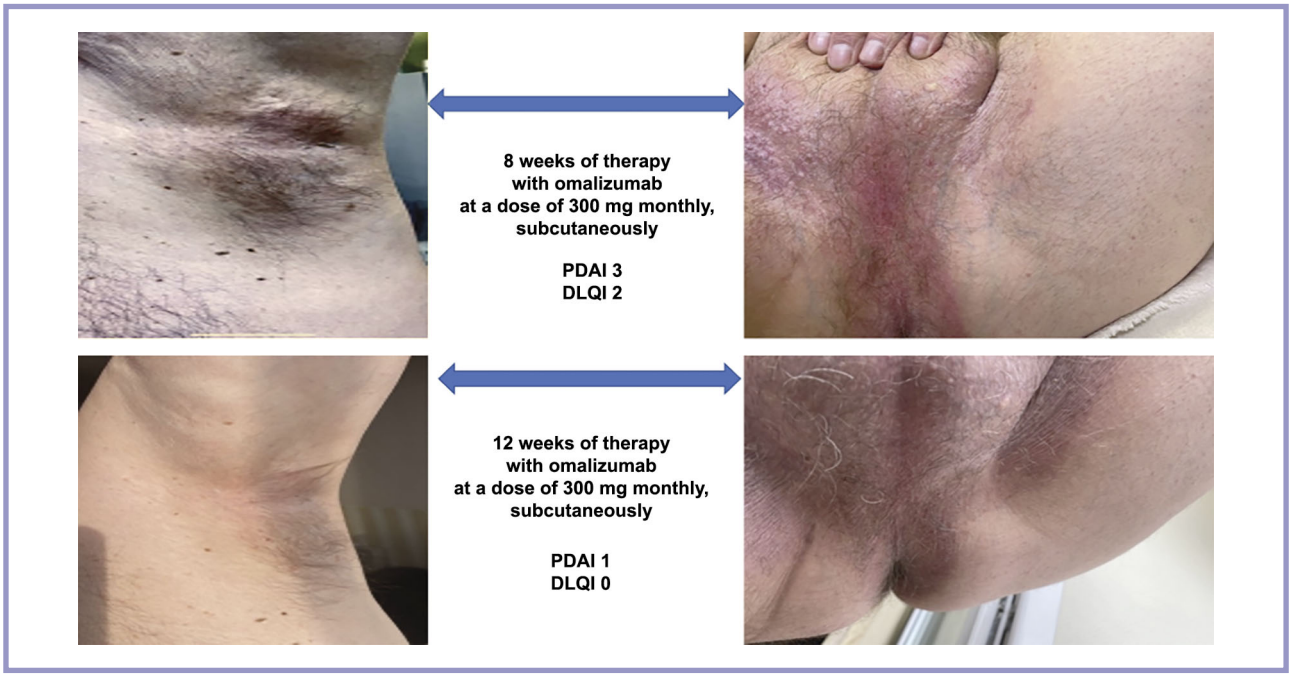

Fig. 2. **Same patient, change in clinical picture of BFCP during the treatment.**

framammary areas and in the inguinofemoral folds. The rash is accompanied by an unpleasant odor. Medical history: patient suffers from BFP for 37 years with frequent relapses associated with colds, physical exertion, stress. She received systemic therapy with antimicrobial drugs (doxycycline, metronidazole), dapsone, and plasma separation was performed with temporary improvement and relapse a few weeks after the therapy completion. She applied betamethazone + gentamicin + clotrimazole (Triderm) cream topically with short-term improvement. For the past few years — permanent oozing lesion, painfulness in the rash areas. The local status on skin cover of the above mentioned anatomical areas is represented as foci of pronounced hyperemia, moist papules, merg-



Fig. 3. **Same patient, 32 weeks of therapy with omalizumab.**



Fig. 4. **Same patient, 4 months after the end of therapy with omalizumab.**

ing into plaques with a diameter up to 10 cm. Moderate infiltration, multiple fissures, covered with white-gray plaque with an unpleasant odor, exudation are in the foci. Secondary hyperpigmentation on the periphery of the foci. «Brain convolutions» symptom is positive. The examination was performed, severity of the pathological process was determined: PDAI was 33 (severe course), and DLQI — 21. The total IgE level before treatment was 364,4 mIU/ml. There were no clinically significant changes in clinical blood and urine analyses, biochemical blood test.

Treatment was done by the proposed method after signing the informed voluntary consent: subcutaneous administration of 300 mg of omalizumab during weeks 0, 4, 8, 12, 16, 20, 24, 28, 32, 36. Course of 10 injections. A significant improvement in clinical picture has been observed on the 4th week of treatment with omalizumab monotherapy: pain and exudation disap-

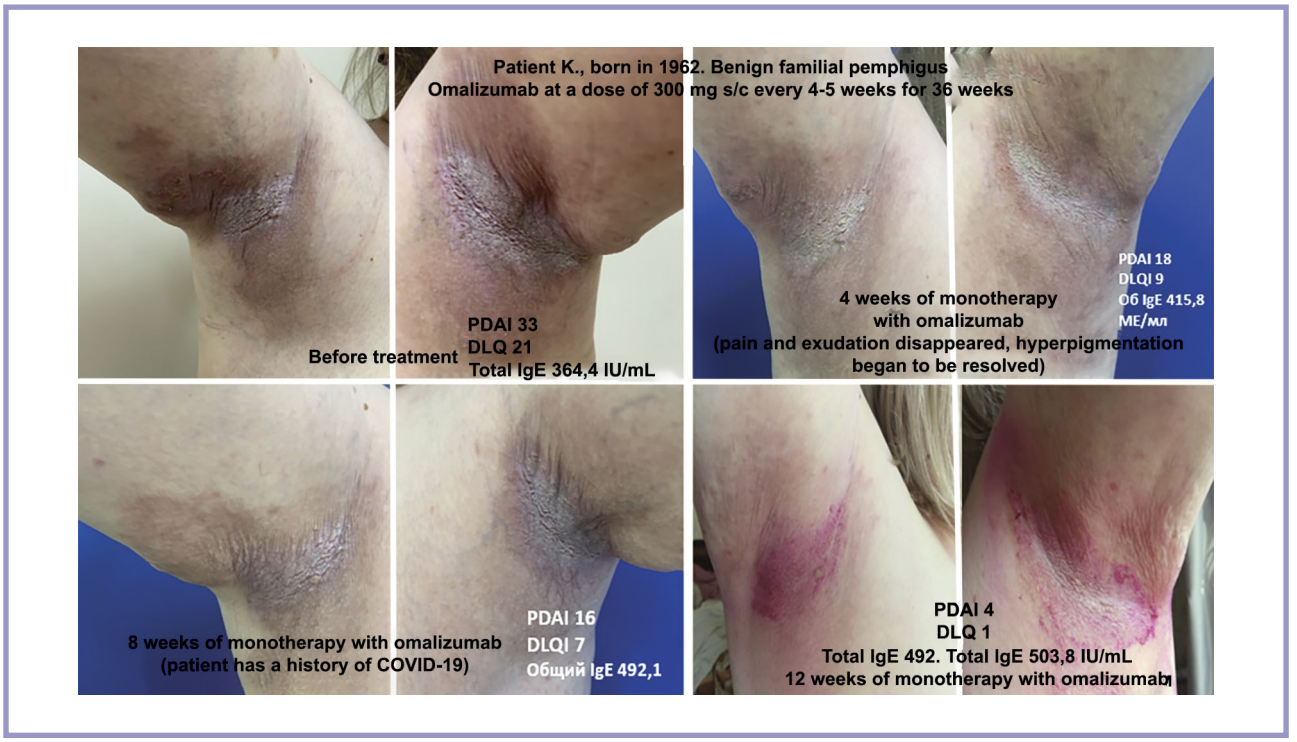

Fig. 5. **Patient *K.*, 60 years old. Clinical picture of BFCP in the axillary areas before and after 4 weeks of treatment with omalizumab.**

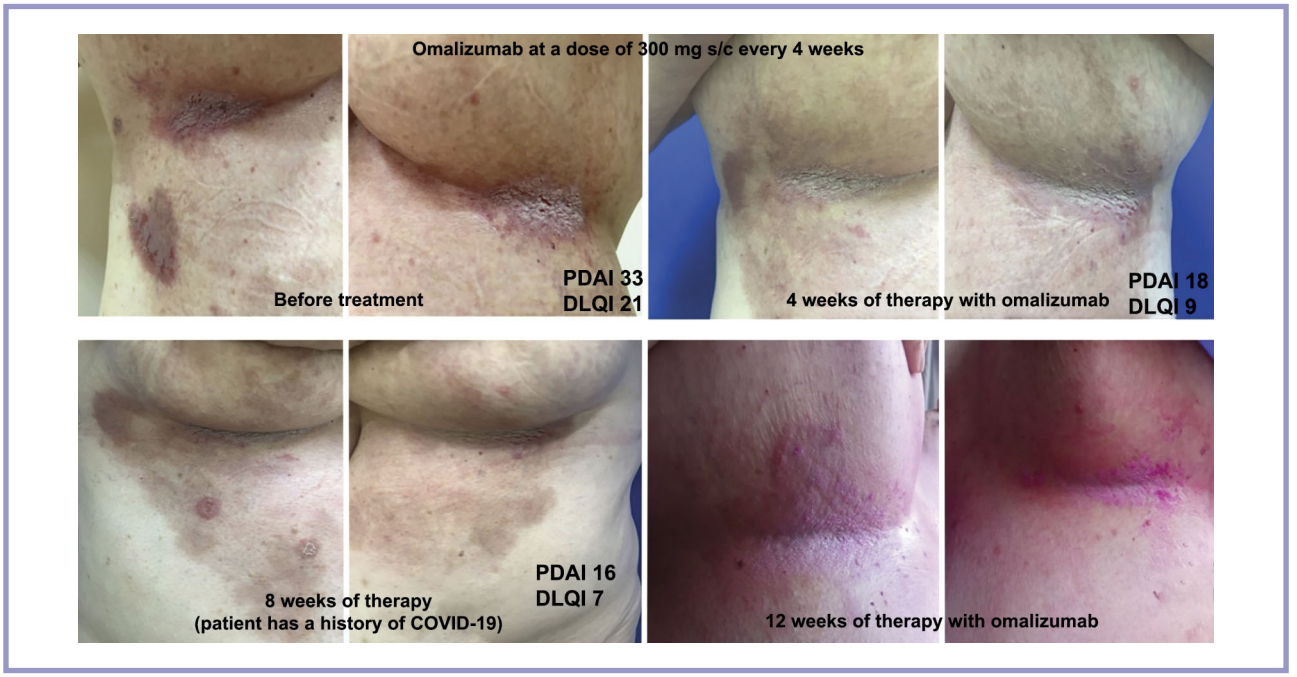

Fig. 6. **Same patient, dynamics of the process in the inframammary areas.**

peared, hyperpigmentation began to be resolved, PDAI decreased to 18 and DLQI — to 9. The resolution of the skin process was suspended at the 8th week of therapy: PDAI amounted to 16 and DLQI — 7, that was likely to be associated with the history of COVID-19 in patient in this time. The process was almost completely resolved at the 12th week: fissures were epithelialized, exudation stopped, plaques were reduced, secondary hyperpigmentation was completely eliminated. Singular crusts and change in skin relief in the area of the axillary cavities and under the mammary glands remained. PDAI — 4, DLQI — 1. The total IgE level was measured in patient during the treatment: the indicator amounted to 415,8 mIU/mL at the 4th week (before omalizumab in-



Fig. 7. **Same patient, lesion of the genital area.**



Fig. 8. **Same patient, exacerbation of the process on the 32nd week of monotherapy with omalizumab.**

jection), 492,1 mIU/mL — at the 8th week, 503,8 mIU/mL — at the 12th week, 548,4 mIU/mL — at the 42nd week. The therapeutic effect of omalizumab application continued up to the 32nd week of therapy. A relapse of the disease occurred at the 32nd week: slight oozing lesion, singular fissures, «brain convolutions» symptom in the axillary, inframammary and inguinofemoral folds, PDAI was 10 and DLQI — 6. The clinical picture remained unchanged at the 36th week. It was decided to withdraw omalizumab and switch the patient to application of a topical monotherapy with a combined drug containing ofloxacin, methyluracil, lidocaine (Oflomelid) 2 times a day. Patient's follow-up for 5 months after the completion of therapy with omalizumab until the



Fig. 9. **Same patient 5 months after the end of therapy with omalizumab.**

52nd week showed a stable result without significant exacerbations of the process. PDAI amounted to 7 and DLQI — 4 on the 52nd week. The disease's dynamics during the treatment is presented in **the fig. 5—9**.

Discussion

Omalizumab increases the total IgE level, while reducing the free IgE level by more than 95%. The increase in total IgE level in general can be explained by a prolongation of half-life of IgE, having half-life of 2—3 days, due to binding of the IgG1 structure, which has a half-life of 26 days, with omalizumab. It is known that the increase in total IgE level lasts more than one year after treatment cessation [3].

The therapy with described method was performed in 5 patients with BFP (3 men and 2 women) aged 42,3±6,08 years. Duration of the disease was 252,0±26,0 months. The diagnosis was clinically verified and histologically confirmed. All patients were included in the study during the pathological process exacerbation, clinical manifestations were observed in at least 3 anatomical areas, severity of the pathological process was determined by PDAI. The IgE level in all patients at inclusion in the study ranged from 364,4 to 583,4 mIU/mL. A moderate degree of the pathological process has been identified in 3 patients (PDAI up to 24), severe — in 2 patients (PDAI 27 and 33). The mean PDAI value before treatment initiation was 23,05±2,37, DLQI — 16,02±3,28 (the disease has a very strong impact on the patient's life). All patients showed significant improvement after 12 weeks of treatment with omalizumab, the mean PDAI value was 2,34±0,42, DLQI — 1,33±0,21 at the 12th week of therapy. A persistent effect of treatment maintained up to 42 weeks of therapy in 4 patients, with slight exacerbation during 4 months of follow-up after the therapy completion. The mean PDAI value 4 months after the end of therapy amounted to 5,02±0,81, DLQI — 2,11±0,43. An exacerbation has been noted in one patient at the 32nd week of treatment with omalizumab: PDAI — 10, DLQI — 6. Omalizumab was withdrawn, and a topical combined therapy with a drug containing ofloxacin, methyluracil, lidocaine 2 times per day for 5 months was prescribed. PDAI amounted to 7, DLQI — 4 according to the evaluation results 5 months after the treatment completion in this patient.

Conclusion

The presented clinical cases demonstrate the possibility of using omalizumab for BFP treatment in severe continuously relapsing course of the disease, torpid to previous conventional therapy with systemic antibiotics and glucocorticosteroids, that allows to potentially count on long-term remission and fundamentally improve the patients' life quality. Detailed randomized clinical trials are required to obtain more convincing and unambiguous conclusions.

Authors' participation:
All authors are responsible for the content and integrity of the entire article.

Literature analysis, collection and processing of material, diagnostic and treatment, research, text writing — Drozhdina M.B.
Concept and design of the article, diagnostic and treatment, editing, approval of the final version of the article — Koshkin S.V.

The concept and design of the article, the examination of patients and the appointment of therapy, text editing, approval of the final version of the article — Gorodnichev P.V.

The authors declare no conflict of interest.

REFERENCES

1. Konstantinou MP, Krasagakis K. *Benign Familial Pemphigus (Hailey-Hailey Disease)*. 2023 Aug 14. In: StatPearls [Internet]. Treasure Island (FL): StatPearls Publishing; 2024 Jan. PMID: 36256785.
2. Drozhdina MB, Koshkin SV. View of the clinic, diagnosis and treatment of familial benign pemphigus (Hailey — Hailey disease). Literature review. *Vestnik Dermatologii i Venerologii*. 2018;94(4):7-14. (In Russ.). https://doi.org/10.25208/0042-4609-2018-94-4-7-14
3. Drozhdina MB, Koshkin SV. View of the etiopathogenesis, clinic features, diagnosis and treatment of familial bening pemphigus (Hailey-Hailey disease). Description of rare clinical case. *Medical Newsletter of Vyatka*. 2018; 59(3):79-84. (In Russ.). https://doi.org/10.25208/0042-4609-2018-94-4-7-14
4. Drozhdina MB, Koshkin SV. The importance of determining the level of serum immunoglobulin E in bullous dermatoses. *Vyatka Medical Bulletin*. 2024;81(1):14-18. (In Russ.). https://doi.org/10.24412/2220-7880-2024-1-14-18
5. Finkelman F. Identification of IgE as the Allergy Associated Ig Isotype. *J Immunol*. 2017;198:3-4. https://doi.org/10.4049/jimmunol.1601893
6. Macharadze DSh Current clinical aspects of assessing the levels of general and specific IgE. *Pediatriya im. GN Speranskogo*. 2017;96(2):121-127. (In Russ.).
7. Bundhoo A, Paveglio S, Rafti E, et al. Evidence that FcRn mediates the transplacental passage of maternal IgE in the form of IgG anti-IgE/IgE immune complexes. *Clin. Exp. Allergy*. 2015;45:1085-1098. https://doi.org/10.1111/cea.12508
8. Pereverzina NO, Kruglova LS, Musaev IE. Present and future in the treatment of chronic spontaneous urticaria. *Russian Journal of Clinical Dermatology and Venereology*. 2020;19(5):604-612. (In Russ.). https://doi.org/10.17116/klinderma202019051604
9. Kruglova LS. Chronic spontaneous urticaria: news about problem and treatment (literature review). *Medical alphabet*. 2019;2(26):15-20. (In Russ.). https://doi.org/10.33667/2078-5631-2019-2-26(401)-15-20
10. Metz M, Vadasz Z, Kocatürk E, Giménez-Arnau AM. Omalizumab Updosing in Chronic Spontaneous Urticaria: an Overview of Real-World Evidence. *Clin Rev Allergy Immunol*. 2020 Aug;59(1):38-45. https://doi.org/10.1007/s12016-020-08794-6
11. Busse W, Corren J, Lanier BQ, McAlary M, Fowler-Taylor A, Cioppa GD, van As A, Gupta N. Omalizumab, anti-IgE recombinant humanized monoclonal antibody, for the treatment of severe allergic asthma. *J Allergy Clin Immunol*. 2001 Aug;108(2):184-190. https://doi.org/10.1067/mai.2001.117880

Received 09.10.2024
Accepted 16.11.2024