Russian Journal of Clinical Dermatology and Venereology
2024, Vol. 23, No. 3, pp. 275-282
https://doi.org/10.17116/klinderma202423031275

Experimental evaluation of allogeneic biomaterial application after cold skin injury in rats

© L.A. MUSINA, A.I. LEBEDEVA, O.R. SHANGINA, E.M. GAREEV

Bashkir State Medical University, Ufa, Russia

ABSTRACT

Background. The positive effect of dispersed biomaterial on skin reparative processes after thermal and chemical burns has been established in test on experimental animals. The influence of allogeneic biomaterial (AB) on skin healing after cold skin injury has not been investigated yet.

Objective. To identify the influence of AB on skin healing processes in experimental rats after cold injury simulation.

Material and methods. The experiment included 36 non-linear male white rats (body weight 200—250 gr). Cryolysis of rats' back skin was simulated by liquid ozone (–195,75 °C) for 1 min. Spontaneous injury healing was investigated in control group; dispersed AB in normal saline solution (by 1 ml) was injected subcutaneously into damaged area in the 1st experimental group on 3rd day, and in the 2nd experimental group in 14 days after cold exposure. Skin fragments from damaged area were taken for examination on 7th, 14th, 21st, 30th days after biomaterial injection, in the control group in the same time after cryolysis. Histological examinations were conducted according to the generally accepted standard methods. The expression of transforming growth factor (TGF-b1) cytokine was determined immunohistochemically in tissues.

Results. The subcutaneous AB injection to rats after 3 days into area of cold injury accelerates epithelization and prevents tissues' scarring. There are marked transformation of formed scar in its area into a dense fibrous connective tissue with increased number of unidirectional fascicles of collagen fibers compared to normal, but there are no signs of inflammatory reactions or gross tissues' scarring.

Conclusion. Early injury epithelization was noted on rats' skin with simulated cold injury after subcutaneous AB injection. AB prevents gross tissues' scarring and contributes the formation of connective tissue regeneratus under well regenerating epithelium, that is very similar by structure with dermis.

Keywords: *allogeneic biomaterial, cryolysis, skin, scarring, reparative regeneration.*

INFORMATION ABOUT THE AUTHORS:
Musina L.A. — https://orcid.org/0000-0003-1237-9284
Lebedeva A.I. — https://orcid.org/0000-0002-9170-2600
Shangina O.R. — https://orcid.org/0000-0003-1686-1254
Gareev E.M. — https://orcid.org/0000-0002-6561-0892
Corresponding author: Musina L.A. — e-mail: morphoplant@mail.ru

TO CITE THIS ARTICLE:
Musina LA, Lebedeva AI, Shangina OR, Gareev EM. Experimental evaluation of allogeneic biomaterial application after cold skin injury in rats. *Russian Journal of Clinical Dermatology and Venereology*. 2024;23(3):275–282. (In Russ.). https://doi.org/10.17116/klinderma202423031275

Introduction

Biological materials for regenerative surgery are donor, mainly connective tissues, which are subjected to special physico-chemical processing with elimination of cell elements from them. This is done in order to reduce the antigenicity of tissues and to preserve separate bioplastic and physical-mechanical properties [1]. Implantation of such biomaterials ensures selective growth of tissues in such zone without scarring or their encapsulation, and also contributes to the involution of some degenerative-dystrophic and post-inflammatory fibrotic changes in tissues [2—5]. The positive effect of such allogenic biomaterials (AB) on reparative processes in skin after simulation of thermal and chemical burns has already been established in experiments on animals [6, 7]. At the same time, AB inhibited the processes of coarse skin scarring and contributed to the formation of regenerate very similar in structure to the dermis of the skin under a well-regenerating epithelium. Cold skin injury is known to cause severe damage to all skin layers, which is manifested by necrotic changes of epidermis, dermis and even hypodermis [8—10]. The effect of AB after cold skin injury has not yet been investigated.

The objective is to identify the impact of AB on the skin recovery processes of experimental rats after simulation of cold injury.

Material and methods

The experiment involved 36 non-linear male white rats aged 6 months (200—250 g body mass). We complied with the basic requirements set out in the Rules of laboratory practice (Order of the Ministry of Health and Social Development of the Russian Federation of August 23, 2010 No. 708n «On approval of the laboratory practice rules»). Ethical principles for laboratory animals handling were observed in accordance with the European convention for the protection of Vertebral Animals used for experimental and other scientific Purposes. cets no. 123. Cryodestruction of the glabrous back skin of rats was simulated by means of pliers with smooth surface within 1 min, using ether anaesthesia. The instrument was previously placed in liquid nitrogen (–195,75 °C). A rat's

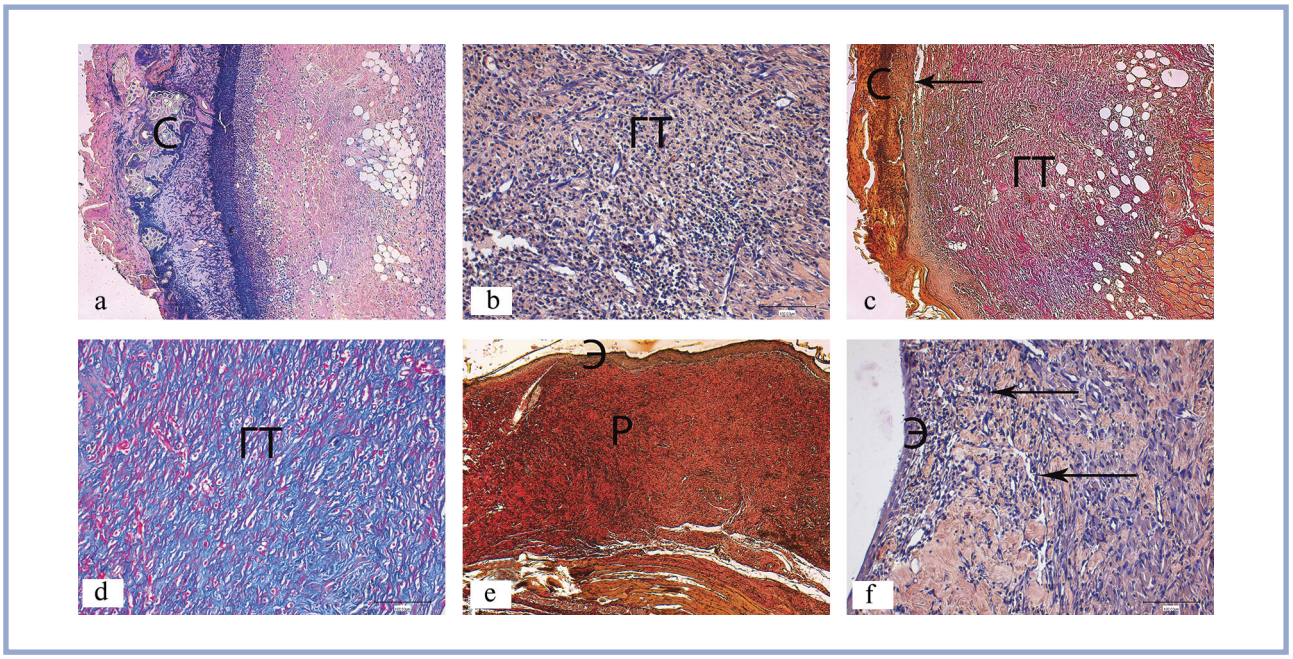

Fig. 1. **Morphological skin alterations in rats of control group after cryolysis.**
a — 7th day. Necrosis of all skin layers involving subcutaneous tissue and underlying muscle tissue, diffuse-focal leukocytes infiltration (hematoxylin and eosin staining, zoom ×100); b — 7th day. Granulation tissue with round-cell infiltration (hematoxylin and eosin staining, zoom ×200); c — 14th day. Absence of epithelial layer (arrow) under crust (C) (Van Gieson staining, zoom ×100); d — 21st day. Granulation tissue (Mallory staining. Zoom ×200); e — 30th day. Avascular dense scar tissue in cryolysis area (Van Gieson staining. Zoom ×40); f — 30th day. Cellular infiltrates (arrow) in the connective tissue regeneratus (hematoxylin and eosin staining, zoom ×200); С — crust on the injury; Э — epithelial layer; ГТ — granulation tissue; Р — scar tissue.

skin area of 0,5 cm^2 was caught by the «jaws» of the tool. The rats were divided into 3 groups after simulating cold injury. A process of spontaneous wound healing was observed in the control group. Dispersed AB, manufactured from rats' tendons using the alloplant technology (MA No. fsr 2011/12012 of February 3, 2015) was subcutaneously injected in the injury area of rats of the 1st experimental group (on the 3rd day after cold exposure). AB in the amount of 5 mg was diluted in 2 ml of physiological saline solution and injected to the animals by 1 ml. In the 2nd experimental group, AB was injected in the same way and at the same dosage 14 days after skin cryodestruction. Skin fragments in the cryodestruction zone were taken on the 7th, 14th, 21st, 30th day after the AB administration, in the control group — in the same timeframe after cryodestruction. The tissues were fixed in 10% neutral buffered formalin and embedded into paraffin. Histological sections were produced on the Leica microtome (Germany). The sections were stained with hematoxylin and eosin, as well as picrofuchsin using the Van Gieson and Mallory methods. Immunohistochemical studies were performed. TGF-b1 (transforming growth factor) cytokine expression was determined according to manufacturer's protocol. Mouse monoclonal antibodies (Santa Cruz Biotechnology) and a universal secondary detection system were used to visualize the identified complex.

The reaction was carried out in the Leica BOND MAX IHC Slide Stainer (Leica, Germany). Further coloration of the sections was carried out with a hematoxylin solution and then they were mounted in a balm. The cells expressing cytokine were counted by the use of Leica DMD-108 microscope (Germany) at zoom x400 (a total of 20 fields of vision in each group). An overall estimation of the cell (expressing the studied cytokine) count dependence on the time after the cold injury simulation was made with the use of the Kruskal-Wallis test, and the comparison of independent samples — using the Mann-Whitney test [11, 12]. Accordingly, medians (Me), quartiles (Q1 and Q3) were used to describe the results, and, if necessary, the boundaries of variation (min—max). The database and all calculations were made using the Statistica 10 software package [13].

Results and discussion

An extensive focus of necrosis of all skin layers, subcutaneous tissue, down to the subjacent muscle tissue with diffuse-focal leukocytic infiltration was determined in the control group rats on the 7th day after the cryogenic exposure in the affected zone **(fig. 1, a).** The lumens of blood vessels in the deep skin layers were dilated and filled with the formed elements of blood. Small areas of loose vascularized granulation tissue formation with round cell infiltration, mainly by lymphocytes, were found in the adjacent areas of necrosis, which is the evidence of pronounced inflammatory reaction **(see fig. 1, b).** Epithelium was not restored after 14 days, and granulation tissue from loose vascularized tissue, infiltrated by inflammatory cells was determined at the place of dermis **(see fig. 1, c).**

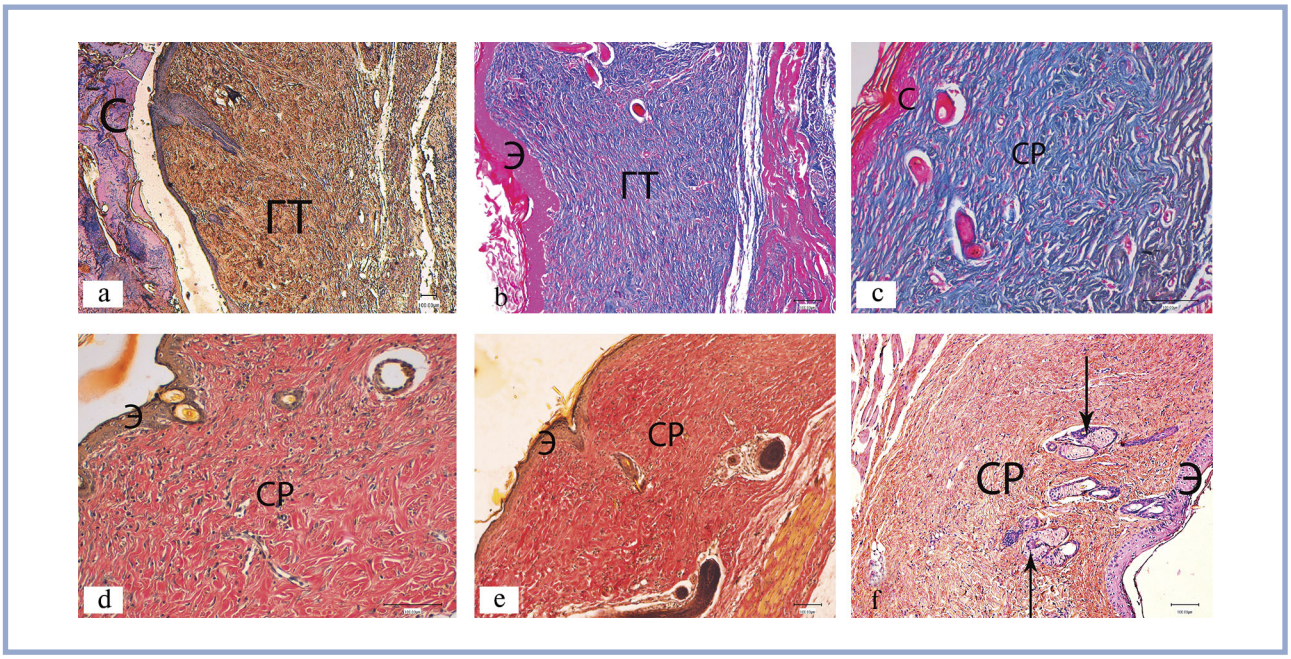

Fig. 2. **Morphological skin alterations of rats of the 1st experimental group (AB application in 3 days after cryolysis).**
a — 7th day after AB injection. Crust desquamation and formation of thin epithelial layer (arrow) on granulation tissue (hematoxylin and eosin staining, zoom ×40); b — 7th day after AB injection. Granulation tissue formation (Mallory staining, zoom ×100); c — 14th day. Forming connective tissue regeneratus under epithelium (Mallory staining, zoom ×200); d — 21st day. (Van Gieson staining, zoom ×200); e — 30th day. Connective tissue regenerates on the cryolysis area (Van Gieson staining, zoom ×40); f — 30th day. Absence of inflammatory infiltrates, regeneration of hair follicles and sebaceous glands (arrow) in regeneratus (hematoxylin and eosin staining, zoom ×100); С — crust on the injury; Э — epithelial layer; ГТ — granulation tissue; СР — connective tissue regeneratus.

The crust fell off from the wound on the 21st day, but the new epithelial layer was thin and uneven in thickness with dystrophic changes of cells. The granulation tissue from thin collagen fibers, fibroblasts, lymphocytes, macrophages and neovasculature with thin walls continued to form under it **(see fig. 1, d).** The pronounced proliferation of fibroblastic cells, which are known to be the source of collagen synthesis, attracted the attention. Uneven in thickness epithelial layer, in some places thickened, and in some places, on the contrary, very thin, was determined on the 30th day on the wound. The dermis without differentiation on the papillary and reticular layers was represented by the non-vascular dense tissue in the form of fibrous scar with inordinately packed coarse bundles of collagen fibers **(see fig. 1, e).** Normally, the dermal skin layer is usually represented by interwoven between themselves bundles of distinct collagen fibers, oriented in three projections and containing between themselves blood vessels. There were no dermal appendages in the form of the sebaceous and sweat glands, as well as hair follicles in the connective-tissue regenerate. Loci of immature granulation tissue with pronounced inflammatory infiltration indicating the chronification of process continued to be detected among the coarse thick collagen fibers **(see fig. 1, f).**

Although not a large but relatively even band of new epithelial layer was revealed on the 7th day under the falling off crust on the wound's entire surface in rats of the 1st experimental group (AB injection on the 3rd day after cryodestruction) **(fig. 2, a).** The area of granulation tissue was defined under it. This zone consisted of newly formed very thin collagen fibers, between which thin-walled capillary-type vessels and fibroblasts were determined **(see fig. 2, b).** The fibroblastic reaction in the emerging tissue was moderate. The swelling disappeared and the blood vessels slightly narrowed in the deeper layers of the dermal matrix. The connective-tissue regenerate became more dense on the 14th day after the AB injection, there were signs of its remodeling onset or «maturation» of the tissue with the formation of thicker formed fibrous elements **(see fig. 2, c).** Many vessels of granulation tissue have been reduced. The affected area was covered with a smooth epithelial layer on the 21st day after the AB injection. The connective-tissue regenerate was defined below it, consisting of dense bundles of thin collagen fibers, among which a few small capillaries were identified **(see fig. 2, d).** The majority of dermis was represented by fibrous connective tissue 30 days after the AB injection. Spindle fibroblasts were determined between fuchsinophilous bundles of collagen fibers **(see fig. 2, e).** The structure in the collagen fibers' bundles of regenerate in many areas was similar to that of dermis in healthy skin areas. Signs of inflammatory reactions at the site of cold injury simulation and coarse scarring of tissues were not revealed **(see fig. 2, f).** At the same time, signs of skin derivatives' regeneration in the form of a proliferation from the periphery to the connective-tissue regenerate of sebaceous glands and hair follicles were noted.

In the 2nd experimental group, AB was applied 14 days after the skin cryodestruction, thus the crust had not yet been desquamated and covered the wound. But it

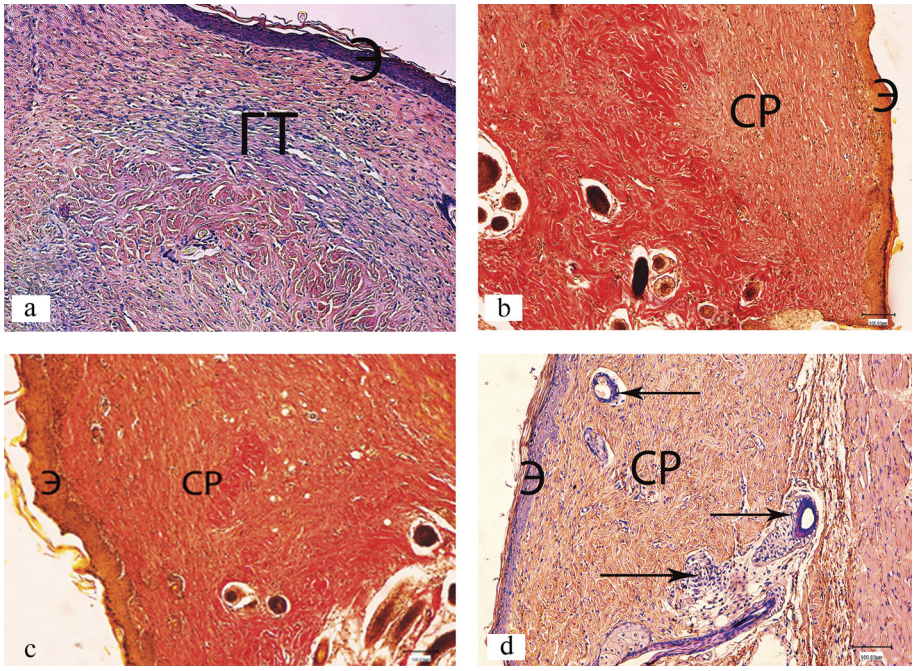

Fig. 3. **Morphological skin alterations in rats of the 2nd experimental group (AB application in 14 days after cold injury).**
a — 7th day after AB injection. Absence of crust and formation of thin epithelial layer on the granulation tissue (hematoxylin and eosin staining, zoom ×100); b — 14th day after AB injection. Nonhomogeneous structure of connective tissue regeneratus (Van Gieson staining, zoom ×100); c — 21st day. Forming dense connective tissue regeneratus under restored epithelium (Van Gieson staining, zoom ×100); d — 30th day. Formed connective tissue regeneratus covered by epithelium. Regeneration of hair follicles (arrow) and sebaceous glands, skin (hematoxylin and eosin staining, zoom ×100). Э — epithelial layer; ГТ — granulation tissue; CP — connective tissue regeneratus.

fell off 7 days after AB injection, the epithelial layer was present on the wound, but was thin and uneven in thickness **(fig. 3, a).** Areas of granulation tissue with thin collagen fibers and a small number of vessels, as well as already formed more dense areas of scar-like structure were defined under it. The plexuses of of collagen fibers' bundles in the connective-tissue regenerate differed somewhat from those of the dermis in the unaffected skin areas, they were more unidirectional, but there was no evidence of inflammatory reactions in the tissues or coarse scarring. Signs of regeneration of certain hair follicles were identified locally along the regenerate's edges. The newly formed connective tissue under the epithelium also had a heterogeneous structure 14 days after the AB injection **(see fig. 3, b).** Areas with a fine-fibrous structure alternated with small foci of tissue, which consisted of relatively thick formed bundles of collagen fibers. The tissue under the epithelium became more «mature» and homogeneous in structure by the 21st day **(see fig. 3, c).** The formed connective-tissue regenerate under a smooth layer of epithelium was represented by a formed fibrous connective tissue and consisted of densely structured bundles of convoluted collagen fibers and numerous fibroblasts between them 30 days after the AB injection **(see fig. 3, d).**

The obtained results of histological studies are consistent with the data of immunohistochemical studies on identification of TGF-β anti-inflammatory cytokine in tissues. According to modern concepts, TGF-β is a profibrotic cytokine that plays a leading role in the pathogenesis of cicatricial transformations in tissues [5, 6, 14, 15]. This growth factor, which has a number of ambiguous reparative and immunosuppressive effects, is thought to be directly correlated with the expression of FGF-1 (fibroblast growth factor 1), contributing to enhanced proliferation of fibroblastic cells — the main sources of collagen synthesis during the formation of collagen fibers.

The number of cells expressing TGF-β cytokine was quiet dependent on the time elapsed after simulating cold injury in our study. This dependency is manifested in a subsequent decrease in the number of such cells, that is much more pronounced in both groups compared to the control group **(fig. 4).** The values are fairly close and are not statistically significantly different up to 1 month in the 1st and 2nd experimental groups at all stages of observation: on the 7th day Me is 41 (32,5, 3 57) cells in the 1st group and 37 (30, 57) cells in the 2nd group (p>0,67), respectively, on the 14th day — 29 (24,5, 38) cells in the 1st group and 33,5 (24,5, 47,5) cells in the 2nd group (p>0,30), on the 21st day — 22 (17, 26) cells in the 1st group and 24,5 (19, 31) cells in the 2nd group (p>0,07). But on the 30th day the median value of number of TGF-β expressing protein cells in the 1st group became statistically significantly (p<0,002) lower than in the 2nd group — 8,5 (7, 11) cells against 12 (9, 17) cells. In the

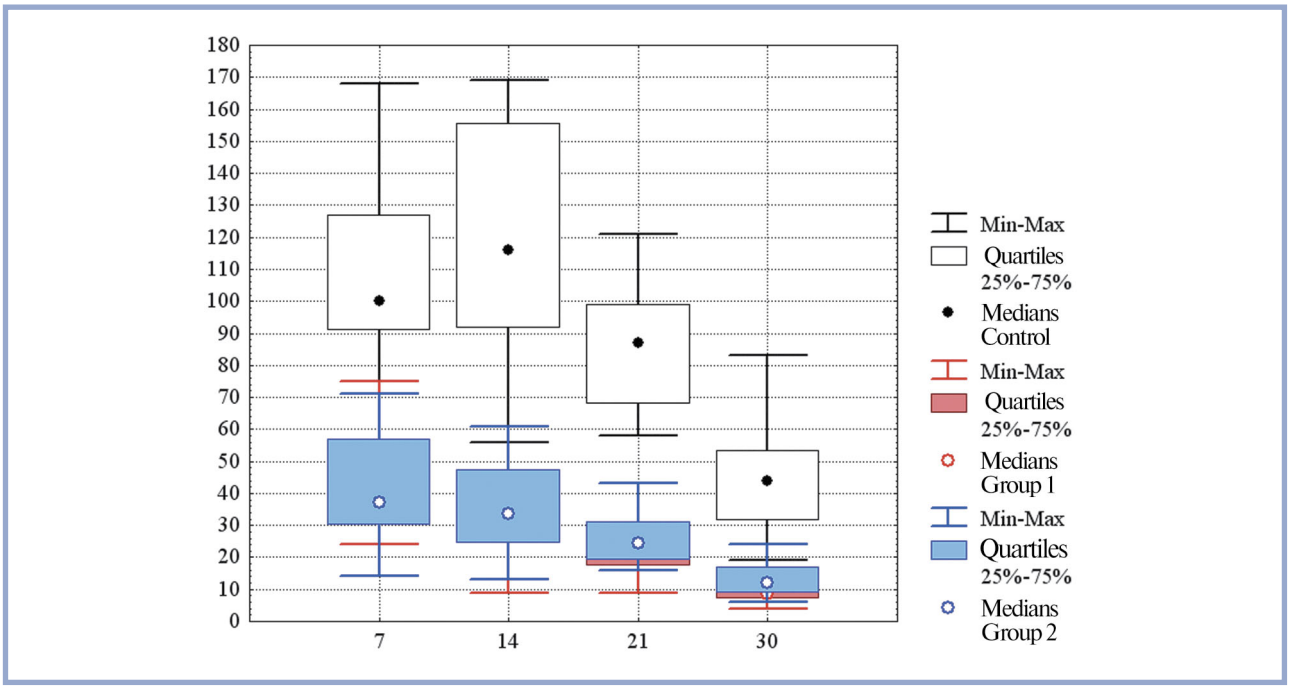

Fig. 4. **Number of cells expressing TGF-β cytokine in control and two experimental groups (the 1st group and the 2nd group) at different times after cold injury stimulation and AB application.**
The observation period on the abscis axis — days after cold skin injury (in control group) and days after injury and AB injection in experimental groups (in the 1st group — in 3 days after injury; in the 2nd — in 14 days after injury). The ordinate axis indicates the average number of cells expressing TGF-β cytokine in microscope field.

same period, the number of cells of this type in the control group remains multiply higher — 44 (31,5, 57,5) cells, as well as at the beginning of observations on the 7th day — 100 (81, 127) cells. Consequently, the number of cells expressing TGF-β cytokine in the control group remains significantly higher throughout the observations than in the experimental groups after the AB injection, where their number is reduced quite radically, and in the 1st experimental group with a distinctively higher intensity. It should also be noted that in both experimental groups, the intra-group variability in the number of such cells decreases dramatically as the distance from the moment of cold injury. If on the 7th day the range of this parameter in the 1st and 2nd groups was 24—75 cells and 14—71 cells, respectively, then after 1 month — 4—13 cells and 6—24 cells.

It has been established that the level of expressed TGF-β protein usually correlates directly with inflammation severity [16]. We revealed high levels of this cytokine in control animals, which is also one of the main causes of intensive fibroblastic cell proliferation in granulation tissue formation, which leads to the fibrosis of the connective-tissue regenerate in the remodeling stage. In this case, we observed a rather long retention of the crust and late epithelialization of the injured skin area, which is also not conducive to full recovery of the skin stroma. It can be assumed that one of the determinative factors for the AB benefit on the healing of skin wound after cold injury and inhibition of coarse scarring processes is the lower level of TGF-β1 anti-inflammatory cytokine expression by cells.

The degree of inflammatory processes' manifestation was weaker in connection with the relatively low expression of anti-inflammatory protein in animals of experimental groups when using AB in contrast to animals of control group at all periods of experience. The level of expression of TGF-β1 in the 1st experimental group on the 7th day was 41 (32,5, 57) cells and in the 2nd experimental group — 37 (30, 57) cells. The values were 2,5—3 times lower than in the animal of control group in this timeframe (p<0,001). Desquamation of the crust on the created wound was identified on the 7th day after the AB injection in animals of the 1st experimental group, this was due to accelerated epithelialization of the wound. Just as in the case of AB application for skin burns, its subcutaneous injection to animals in the area of cold imjury neutralizes the manifestation intensity of signs of inflammatory processes, which is manifested by moderately pronounced fibroblastic reaction [6, 7]. As a result, the formation of more adequate in the structure connective-tissue regenerate of the dermal matrix under the restored epithelial layer in experimental group of animals in contrast to the control group, where the accelerated coarse scarring of granulation tissue occurs [16].

Conclusion

Reparation of epithelium and skin dermis of rats in the control group after cold trauma with high expression of TGF-β cytokine fibrosis factor is accompanied by a pronounced inflammatory reaction with intensive fibroblasts' proliferation leading to the formation of an imper-

fect fibrous scar covered with an uneven epithelial layer. The use of dispersed AB after 3 days in cold injury area neutralizes manifestations of pronounced inflammatory processes, accelerates epithelialization and early formation of granular tissue, causes a moderate fibroblastic reaction due to the lower expression of TGF-b1 level by cells that contributes to the formation of properly ordered collagen fibres in the dermis. The healing of the affected area ends with the formation of an adequate connective-tissue regenerate under the completely restored epithelium and with signs of skin derivatives regeneration. There is a pronounced transformation in most parts of already forming cryogenic scar into a dense fibrous connective tissue with more unidirectional bundles of collagen fibers than in the skin dermis in 14 days after the AB injection, but signs of inflammatory reaction in tissue or coarse scarring are not noted. The results obtained in the experiment on animals, probably, can be extrapolated to the processes of cryogenic exposure on the human body.

Financing. The work was performed within the framework of State Task No. 056-00124-21-00, approved on 12/23/2020.

Authors' contributions:
The concept and design of the study: Musina L.A., Lebedeva A.I., Shangina O.R.
Collecting and interpreting the data: Musina L.A., Lebedeva A.I., Shangina O.R., Gareev E.M.
Statistical analysis: Gareev E.M.
Drafting the manuscript: Musina L.A.
Revising the manuscript: Lebedeva A.I., Shangina O.R.

The authors declare no conflict of interest.

REFERENCES

1. *Alloplant Регенеративная медицина*. Под ред. Мулдашева Э.Р. Уфа. 2014. *Alloplant Regenerative medicine*. Pod red. Muldasheva E.R. Ufa. 2014. (In Russ.).
2. Nuraeva AB. The use of «Alloplant» technologies in cases of unilateral postburn cicatricial inversion of the upper and lower eyelids. *Prakticheskaja medicina*. 2016;6:122-125. (In Russ.).
3. Nuraeva AB, Musina LA. Structural changes of Alloplant biomaterials in the plastic of post-burn defects of the eyelids *Prakticheskaja medicina*. 2016; 6:126-129. (In Russ.).
4. Nuraeva AB, Musina LA. Morphological analysis of biopsies of patients after plastic surgery of post-traumatic eyelid defects using Alloplant biomaterial. *Prakticheskaja medicina*. 2017;9(2):142-145. (In Russ.).
5. Musina LA, Shakirov RF, Galimova VU, Shangina OR, Lebedeva AI, Kadirov RZ. Biomaterial Alloplant as an inhibitor of scarring of the damaged cornea (Immunohistochemical examination) *Prakticheskaja* medicina. 2017; 17(1):112-116. (In Russ.).
6. Nuraeva AB, Musina LA, Gareev E.M. Biomaterials Alloplant — inhibitors of skin scarring after burns (Experimental morphological study). *Oftalmologicheskye vedomosti*. 2017;10(2):22-28. (In Russ.).
7. Nuraeva AB, Musina LA, Lebedeva AI, Vafiev AC. *The use of biomaterial «Alloplant» to restore the skin after a chemical burn (Experimental morphological study)*. V kn.: Aktualnye voprosi tkanevoyi i kletochnoy transplantologii. Sbornik tezisov VII Vserossiyskogo simpoziuma s megdunarodnim uchastyem. 2017:151-154. (In Russ.).
8. Shapovalov KG, Sizonenko VA. Cold injury as a cause of persistent changes in the state of the microcirculatory bed. *Pirogov Russian Journal of Surgery*. 2009;2:28-32. (In Russ.).
9. Mikhaylichenko MI Shapovalov KG. Microcirculatory disorders in the pathogenesis of local cold injury. *Regionarnoe krovoobracgenie i mikrocirkulaciya*. 2019;2:4-11. (In Russ.). https://doi.org/10.24884/1682-6655-2019-18-2-4-11
10. Lebedeva AI. Allogeneic spongy biomaterial is an inhibitor of fibrosis of damaged skeletal muscle tissue. *Rossijskij bioterapevticheskij zhurnal*. 2014; 13(4):37-44. (In Russ.).
11. Kholender M, Vulf D. *Nonparametric methods of statistics*. M.: Finansi i statistica; 1983. (In Russ.).
12. Banergi A. *Medical statistics in plain language*: introductory course. M.: Prakticheskaja medicina; 2007. (In Russ.).
13. Boev VM, Borshuk EL, Ekimov AK, Begun DN. *Guidelines for ensuring the solution of biomedical problems using the Statistica 10 program*. Orenburg: JSC «IPK «Uyjniy Ural»; 2014. (In Russ.).
14. Meng XM, Nikolic-Paterson DJ, Lan HY. TGF-β: the master regulator of fibrosis. *Nat Rev Nephrol*. 2016;12(6):325-338. https://doi.org/10.1038/nrneph.2016.48
15. Hu HH, Chen DQ, Wang YN, Feng YL, Cao G, Vaziri ND, Zhao YY. New insights into TGF-β/Smad signaling in tissue fibrosis. *Chem Biol Interact*. 2018;292:76-83. https://doi.org/10.1016/j.cbi.2018.07.008
16. Muslimov SA, Musina LA, Lebedeva AI, Shanina OR. Morphological bases of Alloplant biomaterials application for tissue regeneration. *Morphologia*. 2008;2:92-93. (In Russ.).

Received 11.08.2023
Revision received 18.10.2023
Accepted 13.03.2024