Russian Journal of Clinical Dermatology and Venereology =
Klinicheskaya dermatologiya i venerologiya 2021, Vol. 20, No. 2, pp. 50-58
https://doi.org/10.17116/klinderma20212002150

Nevus Spitz: a review of the literature and clinical cases from practice

© Y.Y. SERGEEV[1, 2], V.V. MORDOVTSEVA[1, 3], O.B. TAMRAZOVA[4], V.Y. SERGEEV[1, 2], V.G. NIKITAEV[5], A.N. PRONICHEV[5]

[1]Society for Dermatoscopy and Optical Diagnosis of Skin, Moscow, Russia;
[2]Central State Medical Academy of Department of Presidential Affairs, Moscow, Russia;
[3]Moscow State University of Food Production, Moscow, Russia;
[4]Peoples' Friendship University of Russia, Moscow, Russia;
[5]National Research Nuclear University MEPhI (Moscow Engineering Physics Institute), Moscow, Russia

ABSTRACT

Nevus Spitz (juvenile melanoma) is a rare type of melanocytic nevi that mimics skin melanoma by clinical and histological manifestations. The article discusses the issues of diagnostics and tactics of management of spitcoid formations, an analysis of 27 cases from our own practice. The detection rate of Spitz nevus with mixed dermatological admission was 1.8%. The age of the majority of patients did not exceed 18 years; the average was 14.7±14.5 years. The most common site for Spitz's nevus was the skin of the extremities. Dermatoscopic examination revealed a globular model of the structure in 40.8% of cases, a vascular model — in 22.2%, homogeneous and radial radiance — in 18.5% each. Existing dermatoscopic algorithms for evaluating melanocytic formations including computer analysis using an artificial neural network turned out to be ineffective in determining the correct treatment tactics. The results of the combined use of the ABCD dermatoscopic rule and the Moleanalyzer Pro algorithm coincided with the doctor's recommendation in 38.5% of cases. Only 50% of patients appeared for a follow-up examination for dynamic observation of the Spitz nevus. The cases in which surgical treatment was recommended were statistically different in the patient's age and the size of the formation from these indicators in the patients of the observation group ($p<0.05$).

Keywords: *nevus Spitz, juvenile melanoma, atypical nevus Spitz, dermatoscopy, artificial intelligence.*

INFORMATION ABOUT THE AUTHORS:
Sergeev Y.Y. — https://orcid.org/0000-0002-4193-1579
Mordovtseva V.V. — https://orcid.org/0000-0002-6396-2720
Tamrazova O.B. — https://orcid.org/0000-0003-3261-6718
Sergeev V.Y. — https://orcid.org/0000-0001-8487-137X
Nikitaev V.G. — https://orcid.org/0000-0002-4349-3023
Pronichev A.N. — https://orcid.org/0000-0003-0443-8504
Corresponding author: Sergeev Y.Y. — e-mail: tosergeev@gmail.com

TO CITE THIS ARTICLE:
Sergeev YY, Mordovtseva VV, Tamrazova OB, Sergeev VY, Nikitaev VG, Pronichev AN. Nevus Spitz: a review of the literature and clinical cases from practice. Russian Journal of Clinical Dermatology and Venereology = Klinicheskaya dermatologiya i venerologiya. 2021;20(2):50–58. (In Russ.). https://doi.org/10.17116/klinderma20212002150

Nevus Spitz is a rare type of melanocytic nevi with special clinical and histological manifestations that can occur in childhood. The first report describing a rapidly developing melanocytic tumor on the nose of an 8-month-old boy was published by famous French dermatologists J. Darier and A. Civatte at the beginning of the 20th century. The authors noted an unusual histological picture similar to skin melanoma and were unable to unambiguously assess the possible malignant potential of the tumor [1]. In subsequent publications the benign course of such formations in children is shown and the term «juvenile (pre-pubertal) melanoma» is proposed which differs from a «normal» tumor with a favorable prognosis [2]. A significant contribution to the description of this nosology and differential diagnosis with melanoma was made by the pathologist S. Spitz; so, in her memory the nevus got its name [3]. Soon, separate reports began to appear about the development of metastatic lesions and death in patients of different ages with Spitz nevus. Cases of such formations with variable histological manifestations and more pronounced structural or cytological atypia have been described [4]. This led to the additional identification of such nosology like «atypical Spitz nevus» and «melanoma with features of the Spitz nevus» [5]. The study of formations' group with spitzoid characteristics is of great interest today since establishing an accurate diagnosis is a difficult task and diagnostic errors lead to the choice of the wrong treatment tactics and a worsening the prognosis for the patient's life.

A clinically typical Spitz nevus is represented by an asymptomatic single flat or hemispherical formation with clear boundaries [6]. By the nature of staining a «classic» non-pigmented pink nevus **(Fig. 1)** and pigmented varieties are distinguished. The possible color range varies from light brown to black and in some cases the Spitz nevus may be colored unevenly **(Fig. 2)** [7]. A number of authors distinguish intensely stained black formations into a separate nosology similar in clinical and histological charac-



Fig. 1. **A non-pigmented variety of Spitz nevus with symptoms of clinical atypia — the surface of the formation is ulcerated.**



Fig. 2. **A pigmented variety of Spitz nevus with an uneven coloration and slight hyperkeratosis on the surface.**

teristics — Reed's nevus **(Fig. 3)** [8]. Its typical localization is the skin of the face, neck and extremities, although it can be located on other areas of the skin [9]. The surface of the formation is smooth in most cases; less often it's hyperkeratotic or warty. Distinctive features of this nevus are rapid growth within 2 — 3 months and a small size that rarely exceeding 6-8 mm. Nevus Spitz can appear at any age however in 32.8 — 75% of cases it occurs in the age of 20 years [10, 11]. In rare cases the Spitz nevus manifests itself as multiple formations or develops within the congenital melanocytic nevus [12, 13].

For a more accurate clinical assessment of melanocytic formations and differential diagnostics with skin melanoma, a non-invasive diagnostic method is used – dermatoscopy [14]. Known variants of the dermatoscopic picture of the Spitz nevus are presented in **Table 1** and **Fig. 4-7**. Most often, there is radial radiance, globular and vascular models of the structure [15]. It is important to emphasize the possible presence in the Spitz nevus of shades of gray and blue that are unusual for melanocytic nevi. The complexity of dermatoscopic diagnostics is due to the described cases of skin melanoma with spitzoid manifestations that mimic the pigmented and non-pigmented variety of Spitz nevus [16, 17].

Clinical and dermatoscopic signs of Spitz nevus atypia include the nodal morphological element of the formation or its large size (more than 1 cm), the presence of ulceration, an atypical dermatoscopic model of the structure, pronounced vascular polymorphism, blue-white staining and a negative network [18].

On histological examination the classic Spitz nevus has a hemispherical silhouette and is most often a borderline (intra-epidermal) or mixed (epidermal-dermal) formation. In the thickened epidermis the neo-melanocytes are large, elongated or epithelioid in shape, form vertically oriented nests and separated from keratinocytes by light gaps — retraction artifacts **(Fig. 8)**. Melanocyte nuclei can be moderately polymorphic with prominent centrally located eosinophilic nucleoli. The dermal component can be represented by small clusters of epithelioid



Fig. 3. **Reed's nevus with intense and uneven coloration.**
The wrong form of the formation is noted.



Fig. 4. **Vascular model of the Spitz nevus structure.**
There is a uniform distribution of rounded telangiectasias in the form of dots and glomeruli throughout the entire area of formation.



Fig. 5. **A homogeneous (structureless) model of the structure of Reed's nevus, shown in Fig. 3.**
On the periphery of the formation the pattern of the pigment network is noted.

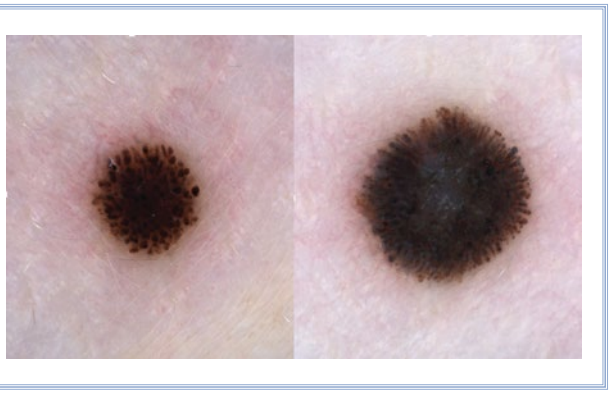

Fig. 6. **Gradual transformation of the globular structure model into radial radiance with the formation of a blue-white coloration in the central part of the formation.**
Follow-up period is 21 months.

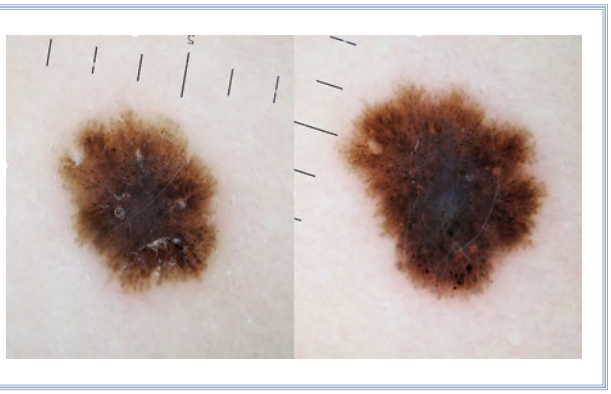

Fig. 7. **Active growth of the Spitz nevus with a structure model according to the type of radial radiation accompanied by a change in the shape and coloration of the pathological site; the formation of a blue-white coloration in the central part.**
Follow-up period is 3.5 months.

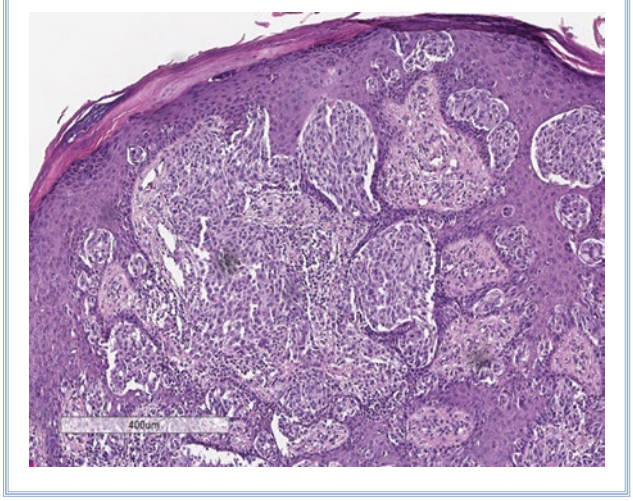

Fig. 8. **Typical histological picture of Spitz nevus. The presence of nesting clusters of large melanocytes, separated from the surrounding tissue by retraction artifacts, is noted.**
Hyperplasia of the epidermis and pagetoid growth are noteworthy.

cells located between collagen fibers or bundles and cords of fusiform cells. It's typical the detection of nevus nests in the epithelium of the skin appendages, peri-neural growth of the formation and the phenomenon of maturation manifested by a decrease in the size of cells and their nuclei in the dermal component from the outside to the inside. It's possible to detect the eosinophilic hyaline bodies of Kamino which are the material of basement membranes, pagetoid growth of individual cells or entire nests and mitotic activity in the epidermal and superficial dermal components of the Spitz nevus [19, 20]. Depending on the characteristics of the formation growth and the reaction of the stroma the variants of the Spitz nevus are additionally distinguished; it's given in **Table 2**. The histological signs of atypia where differential diagnosis with melanoma is required including the large size of the formation, pronounced polymorphism of the nuclei and nucleoli, lack of maturation, solid structure of the dermal component, ulceration, multiple deep and atypical mitoses [21].

In immune-histochemical study the markers cyclin D1, p53, HMB-45 are expressed in Spitz nevi with unequal frequency and usually zonal. The Ki-67 proliferation index should not exceed 15%; nuclear and cytoplasmic expression of the p16 protein in the dermal component is usually noted [22]. At the molecular genetic level the mutations of the HRAS oncogene are most often detected in Spitz nevi and BRAF or NRAS mutations but extremely rarely [23]. In a number of atypical Spitz nevi an additional detection of BAP1 gene mutations or translocation (fusion) of genes of various kinases is possible [24]. For differential diagnosis with skin melanoma in complex cases the method of fluorescence in situ hybridization (FISH) with myb1, CCND1, RREB1 probes and chromosome 6 centromere is recommended [25]. Increased copy numbers of 6p25 and 11q13 as well as homo-

Table 1. **Dermatoscopic variants of the Spitz nevus structure**

Model	Description
Radial radiance	The peripheral part of the entire formation is represented by elongated linear structures with a slight thickening at the free end (pseudopodia). In the central part, a structure-less coloration of black or gray-blue is noted.
Vascular	A uniform distribution of small-caliber telangiectasias (in the form of dots, hairpins or glomeruli) and intersecting white lines (negative network) is noted over the area of the entire formation. They may be a slight brown globular pattern.
Globular	The area of the entire formation or its peripheral part is represented by rounded structures of brown and black color located at some distance from each other. It is possible to determine the negative network in the central part of the formation; also, individual telangiectasias.
Homogeneous (structure-less)	The area of the entire formation is represented by a diffuse staining of dark brown or black, and in the central part there may be shades of gray-blue. In rare cases along the periphery of the formation a pattern of thin intersecting lines (pigment network) is noted.
Reticular	The area of the entire formation is represented by a uniform pattern of the pigment network. A variant of this structure's model is the pattern of «superficial black pigment network» manifested by thickened and dark lines of the pigment network located against the background of a diffuse gray-blue coloration.
Atypical (multi-component)	Formation asymmetric in coloring and distribution of structures manifested by the simultaneous presence of 3 or more separate dermatoscopic structures or a combination of several structural models.

zygous loss of 9p21 are associated with a more aggressive course of atypical Spitz nevi [26].

The tactics of managing the spitzoid formations depends on the clinical manifestations of a particular pigmented lesion and the patient's age. A 2002 survey of 997 US dermatologists showed that the overwhelming majority of physicians (93%) recommend a diagnostic biopsy for Spitz nevus detection [27]. In a similar study the observation of a putative Spitz nevus in children of 7 years old was recommended by no more than 21% of doctors and at the age of 18 years — only 4% [28]. According to the results of a survey of 175 pediatric dermatologists the 49.3% of doctors would recommend dynamic observation of 3 years old children with a small non-pigmented nevus Spitz, 29.7% — for a pigmented nevus with a dermatoscopic model of the structure according to the type of radial radiation in 6-year-old children, only 13% — for a non-pigmented nevus with a diameter of 8 mm in a 16 years old person [29].

When dynamically observing Spitz's nevus it is necessary to remember about the continuing tendency to growth of the formations with a dermatoscopic model of the structure according to the type of radial radiation or with the presence of a peripheral globular component [30, 31]. After the completion of active growth the stabilization phase begins. Its feature is the replacement of the dermatoscopic model of the structure with a homogeneous or reticular one [32]. It has been shown that most formations gradually undergo spontaneous involution in the first two years from the beginning of observation [33]. Control examinations with photo documentation are carried out every 3-6 months depending on the determined dynamics.

All formations with clinical or dermatoscopic signs of atypia, atypical location (in the scalp, genitals, acral areas) as well as rare varieties of Spitz nevus (desmoplastic, verrucous, etc.) are the subject to complete surgical removal [34]. The identification of atypical signs in dynamic observation of a spitcoid formation or a long-term preservation of a tendency towards peripheral growth is considered as negative dynamics and an indication for a diagnostic biopsy. An additional indication for surgical treatment may be the age over 12 years. Despite the low (2 — 4.3%) detection rate of melanoma among spitzoid formations in children the probability of detecting a malignant tumor in patients over 12 years old is estimated at 9.2 — 13.3% [35, 36]. The optimal amount of surgical treatment is the removal of the formation and underlying tissues with an indent of 3—5 mm from the visible edge of the tumor. It has been shown that when removing with a smaller indent the development of relapse is noted in 20% of cases at least. [37].

In order to compare the literature data with the peculiarities of the clinical picture at the present stage we carried out a retrospective analysis of Spitz nevi cases in our practice for 2018–2019. In a general dermatolog-

Table 2. **Rare histological variants of the Spitz nevus structure**

Histological variant	Structural features	Diseases for differential diagnostic
Desmoplastic	Severe fibroplasia of the stroma, the nevus is located intra-dermally and is represented mainly by spindle cell melanocytes	Desmoplastic melanoma
Halo Nevus Spitz	Diffuse inflammatory response where nevus cells may be poorly distinguishable	Melanoma with pronounced regression
Pagetoid	The nevus is usually located superficially, characterized by pronounced pagetoid growth; more common in children	Superficial spreading melanoma
Plexiform	It's presented mainly by spindle cell melanocytes; cells in the derma are collected in bundles	Plexiform spindle cell nevus; plexiform melanoma

ical consultancy the frequency of Spitz nevus detection with a predominance of pigmented formations was 1.8% which coincides with the literature data on the relative rarity of this nosology [38]. During the observation period 27 patients were identified. Among them there were women — 63%, patients under 18 years old — 66.7%, from 18 to 35 — 22.2%, from 35 to 52 — 11.1%. The average age was 14.7 ± 14.5 years, the median was 7. The predominant localization was the skin of the extremities (74.1%); significantly less often Spitz nevi were located on the skin of the trunk (18.5%) and face (7.4%). Dermatoscopic models of the structure were distributed as follows: globular 40.8%, vascular 22.2%, homogeneous and radial radiance — 18.5% each. Detailed clinical and epidemiological characteristics of the identified formations are given in **Table 3**.

The «Observation» group included 14 patients; 7 (50%) of them came for a second consultation. A change in the dermatoscopic model of the structure was observed in 4 out of 5 growing lesions which served as an indication for the removal of Spitz nevi in 2 children and 1 adult patient (see **Fig. 6)**. In 2 cases a change in the staining of the formations to a lighter shade was noted that made

Table 3. **Clinical and dermatoscopic characteristics of Spitz nevi from personal practice**

Case, No.	Age, years	Gender	Localization	Rash element	Surface of formation	Size, mm	Nature of staining, color	Dermatoscopy, structure of the model	Tactics
1	7	F	Wrist backside	Papule	Smooth	2.3×2	Uniform dark brown	Radial radiance	Observation
2	44	F	Body	Plaque	Smooth	6.6×5.1	Uniform black	Homogeneous	Removal
3	52	F	Shin	Papule	With hyperkeratosis	5.5×5.1	Uniform pink	Vascular	Removal
4	3	F	Face	Papule	Smooth	2.3×2.1	Uniform dark brown	Radial radiance	Observation
5	6	F	Body	Papule	Smooth	2.9×2.1	Uniform black	Radial radiance	Observation
6	2	F	Shoulder	Multiple papules (11)	Smooth	1.5×4	Uniform pink and light brown	Globular	Observation
7	7	M	Body	Papule	Smooth	4.8×3.9	Pronounced in the center, light brown	Globular	Observation
8	3	M	Knee area	Papule	Smooth	3.9×3.2	Uniform light brown	Globular	Observation
9	10	M	Forearm	Papule	Smooth	3×3	Uniform black	Globular	Observation
10	25	F	Shin	Papule	Smooth	3.5×2.8	Uniform pinkish-brown	Globular	Observation
11	6	F	Shoulder	Stain	Smooth	5.4×4	Pronounced in the center, dark brown	Homogeneous	Removal
12	20	F	Knee area	Papule	Smooth	5×3.9	Pronounced in the center, pinkish-brown	Vascular	Observation
13	24	F	Hip	Plaque	With hyperkeratosis	7.3×6.3	Non uniform brown	Vascular	Removal
14	34	F	Shin	Node	Smooth	6×5	Uniform pink	Vascular	Removal
15	3	F	Shin	Stain	Smooth	3×1.5	Non uniform brown	Globular	Removal
16	4	F	Body	Plaque	Smooth	8.1×5.2	Non uniform black and brown	Homogeneous	Removal
17	3	M	Shoulder	Papule	Smooth	4.4×3.3	Uniform dark brown	Radial radiance	Removal
18	17	F	Shin	Plaque	With ulceration	7.7×7	Uniform pink	Vascular	Removal
19	6	M	Hip	Papule	Smooth	2.2×2.1	Uniform black	Homogeneous	Observation
20	10	M	Body	Papule	Smooth	4×3.4	Uniform black	Globular	Removal
21	2	M	Face	Papule	Smooth	3×2.7	Uniform brown	Homogeneous	Observation
22	40	F	Hip	Plaque	With hyperkeratosis	7.4×5	Uniform pinkish-brown	Globular	Removal
23	29	F	Knee area	Papule	Smooth	4.1×3.4	Uniform pink	Vascular	Removal
24	3	M	Buttock	Papule	Smooth	3×2.2	Uniform black	Radial radiance	Observation
25	5	F	Wrist backside	Papule	Smooth	3.1×2.3	Non uniform dark brown	Globular	Observation
26	7	M	Buttock	Papule	Smooth	2.3×2.3	Uniform pinkish-brown	Globular	Observation
27	26	F	Knee area	Papule	Smooth	3.7×2.6	Non uniform brown	Globular	Removal

Table 4. **Comparative characteristics of clinical and dermatoscopic manifestations of Spitz nevi, recommended for observation and removal at the initial consultation**

Comparison criteria	Spitz nevi, observation (n=14)	Spitz nevi, removal (n=13)
Mean age, years*	7.6±6.8	22.5±16.8
Mean max size, mm*	3.2±0.9	5.6±1.7
Distribution of dermatoscopic models:		
Vascular, %	7.1	38.4
Globular, %	50	30.8
Radial radiance, %	28.6	7.7
Homogenous, %	14.3	23.1
Mean value of dermatoscopic algorithm ABCD	3.2±0.9	3.2±1.7
Coincidence of selected tactics and results of dermatoscopic algorithm ABCD	13 (92.9%) cases (value <4.8 scores)	3 (23.1%) cases (value ⩾4.8 scores)
Coincidence of selected tactics and results of oleanalyzer Pro analysis	10 (71.4%) cases (value ⩽0.2 scores)	3 (23.1%) cases (value ⩾0.5 scores)

Note. * — Differences are statistically significant at $p<0.05$ when comparing the mean values by Student's test (t-test).

it possible to speak of the beginning of a gradual involution of the Spitz nevus.

The «Removal» group includes 13 patients. In 7 (53.8%) cases the reason for removal immediately after the diagnosis was the older patients age, in 3 (23.1%) cases the parents were worried about the active growth of formations in children, in 2 (15.4%) cases the clinical dermatoscopic atypia were noted and in 1 (7.7%) case biopsy was recommended due to a family history of skin melanoma. Comparative characteristics of those taken under observation and removed formations are given in **Table 4**.

Of particular interest are the results of comparing the selected management tactics with the results of existing algorithms for assessing the dermatoscopic picture [39]. The mean values of the dermatoscopic rule ABCD [40] did not have statistically significant differences in the comparison groups and only 3 (23.1%) lesions from the «Removal» group received a score ⩾4.8 that allowed considering these lesions presumably malignant.

Taking into account the emergence of reports about the possible use of artificial intelligence for evaluating dermatoscopic images [41, 42] we additionally analyzed the images of Spitz nevi using the Moleanalyzer Pro artificial neural network in the Handyscope 3 application (Fotofinder Systems GmbH, Germany). The lesion was assessed as presumably malignant with a neural network-calculated value of ⩾0.5. In the «Removal» group the algorithm also designated 3 (23.1%) formations as malignant, in one case it coincided with the ABCD rule and in 2 cases it marked other formations. Thus, when using the two algorithms together it turned out to be possible to determine the correct tactics for managing the Spitz nevus only in 38.5% of cases.

None of Spitz's non-pigmented nevi including atypical ones have prompted algorithms to speculate about skin melanoma. Taking into account the data on cases of spitzoid melanomas with false negative values of the ABCD rule [43] and the new data obtained, it can be concluded that the considered algorithms do not allow choosing the correct management tactics for patients with Spitz nevi in accordance with modern scientific concepts.

Thus, the Spitz nevus is a complex formation both for establishing a clinical diagnosis and for determining the correct treatment tactics. It must be remembered that the existing methods of clinical diagnostics do not allow an unambiguous differential diagnosis of these formations with skin melanoma. Before deciding to monitor Spitz's nevus it is necessary to discuss with the patient's parents the possibility of frequent visits and the expected changes in education. The peculiarity of dynamic observation of Spitz's nevi is due to the fact that during the initial examination the doctor cannot predict how quickly or how much the manifestations of the formation will change and whether there will be indications for surgical treatment. Our experience shows that the phenomena of clinical dermatoscopic atypia can develop in 3.5-21 months of observation (see **Fig. 6, 7**) and about 50% of patients do not appear for a follow-up examination. This may explain the frequent recommendations for the removal of the Spitz nevus since clinical diagnosis established.

Conclusion

Strict adherence to the existing protocols for the management of spitzoids and the use of modern molecular genetic studies can significantly facilitate the establishment of the final diagnosis. The task of developing new algorithms for the automated diagnosis of special groups of melanocytic neoplasms including those based on artificial neural networks remains urgent.

This work was supported by the Russian Science Foundation; project No. 19-11-00176.

The authors declare no conflict of interest.

REFERENCES

1. Darier J, Civatte A. Naevus ou naevo-carcinoma chez un nourisson. *Bulletin de la Societe Francaise de Dermatologie et de Syphiligraphie.* 1910;21: 61-63.
2. Spatz A, Barnhill RL. The Spitz tumor 50 years later: revisiting a landmark contribution and unresolved controversy. *Journal of the American Academy of Dermatology*. 1999;40(2 Pt 1):223-228. https://doi.org/10.1016/s0190-9622(99)70192-1
3. Spitz S. Melanomas of childhood. *The American Journal of Pathology.* 1948; 24(3):591-609.
4. Luo S, Sepehr A, Tsao H. Spitz nevi and other spitzoid lesions: part I. Background and diagnoses. *Journal of the American Academy of Dermatology*. 2011;65(6):1073-1084. https://doi.org/10.1016/j.jaad.2011.04.040
5. Elder DE, Massi D, Scolyer RA, Wilemze E. *WHO Classification of Skin Tumors*. 4th edition. LYON, IARC; 2018.
6. Miteva M, Lazova R. Spitz nevus and atypical spitzoid neoplasm. *Seminars in Cutaneous Medicine and Surgery*. 2010;29(3):165-173. https://doi.org/10.1016/j.sder.2010.06.003
7. Situm M, Bolanca Z, Buljan M, Tomas D, Ivancić M. Nevus Spitz — everlasting diagnostic difficulties — the review. *Collegium Antropologicum*. 2008; 32(suppl 2):171-176.
8. Ferrara G, Argenziano G, Soyer HP, Chimenti S, Di Blasi A, Pellacani G, Peris K, Piccolo D, Rubegni P, Seidenari S, Staibano S, Zalaudek I, De Rosa G. The spectrum of Spitz nevi: a clinicopathologic study of 83 cases. *Archives of Dermatology*. 2005;141(11):1381-1387. https://doi.org/10.1001/archderm.141.11.1381
9. Requena C, Requena L, Kutzner H, Sánchez Yus E. Spitz nevus: a clinicopathological study of 349 cases. *American Journal of Dermatopathology*. 2009; 31(2):107-116. https://doi.org/10.1097/DAD.0b013e3181934218
10. Cesinaro AM, Foroni M, Sighinolfi P, Migaldi M, Trentini GP. Spitz nevus is relatively frequent in adults: a clinico-pathologic study of 247 cases related to patient's age. *American Journal of Dermatopathology*. 2005;27(6): 469-475. https://doi.org/10.1097/01.dad.0000185249.21805.d3
11. Dika E, Ravaioli GM, Fanti PA, Neri I, Patrizi A. Spitz nevi and other spitzoid neoplasms in children: overview of incidence data and diagnostic criteria. *Pediatric Dermatology*. 2017;34(1):25-32. https://doi.org/10.1111/pde.13025
12. Zayour M, Bolognia JL, Lazova R. Multiple Spitz nevi: a clinicopathologic study of 9 patients. *Journal of the American Academy of Dermatology*. 2012; 67(3):451-458. https://doi.org/10.1016/j.jaad.2011.11.94
13. Schaffer JV, Orlow SJ, Lazova R, Bolognia JL. Speckled lentiginous nevus: within the spectrum of congenital melanocytic nevi. *Archives of Dermatology*. 2001;137(2):172-178.
14. Argenziano G, Soyer HP. Dermoscopy of pigmented skin lesions — a valuable tool for early diagnosis of melanoma. *The Lancet. Oncology.* 2001;2(7): 443-449. https://doi.org/10.1016/s1470-2045(00)00422-8
15. Yoradjian A, Enokihara MM, Paschoal FM. Spitz nevus and Reed nevus. *Anais Brasileiros de Dermatologia*. 2012;87(3):349-357. https://doi.org/10.1590/s0365-05962012000300001
16. Zalaudek I, Kittler H, Hofmann-Wellenhof R, Kreusch J, Longo C, Malvehy J, Puig S, Moscarella E, Piana S, Massone C, Cota C, Ferrara G, Fleischer M, Argenziano G. «White» network in Spitz nevi and early melanomas lacking significant pigmentation. *Journal of the American Academy of Dermatology*. 2013;69(1):56-60. https://doi.org/10.1016/j.jaad.2012.12.974
17. Guida S, Pellacani G, Cesinaro AM, Moscarella E, Argenziano G, Farnetani F, Bonamonte D, Longo C. Spitz naevi and melanomas with similar dermoscopic patterns: can confocal microscopy differentiate? *The British Journal of Dermatology*. 2016;174(3):610-616. https://doi.org/10.1111/bjd.14286
18. Moscarella E, Lallas A, Kyrgidis A, Ferrara G, Longo C, Scalvenzi M, Staibano S, Carrera C, Díaz MA, Broganelli P, Tomasini C, Cavicchini S, Gianotti R, Puig S, Malvehy J, Zaballos P, Pellacani G, Argenziano G. Clinical and dermoscopic features of atypical Spitz tumors: A multicenter, retrospective, case-control study. *Journal of the American Academy of Dermatology*. 2015;73(5):777-784. https://doi.org/10.1016/j.jaad.2015.08.018
19. Tom WL, Hsu JW, Eichenfield LF, Friedlander SF. Pediatric «STUMP» lesions: evaluation and management of difficult atypical Spitzoid lesions in children. *Journal of the American Academy of Dermatology*. 2011;64(3):559-572. https://doi.org/10.1016/j.jaad.2009.12.063
20. Diaconeasa A, Boda D, Solovan C, Enescu DM, Vîlcea AM, Zurac S. Histopathologic features of Spitzoid lesions in different age groups. *Romanian Journal of Morphology and Embryology*. 2013;54(1):51-62.
21. Ferrara G, Gianotti R, Cavicchini S, Salviato T, Zalaudek I, Argenziano G. Spitz nevus, Spitz tumor, and spitzoid melanoma: a comprehensive clinicopathologic overview. *Dermatologic Clinics*. 2013;31(4):589-598. https://doi.org/10.1016/j.det.2013.06.012
22. Lyon VB. The spitz nevus: review and update. *Clinics in Plastic Surgery*. 2010;37(1):21-33. https://doi.org/10.1016/j.cps.2009.08.003
23. Da Forno PD, Pringle JH, Fletcher A, Bamford M, Su L, Potter L, Saldanha G. BRAF, NRAS and HRAS mutations in spitzoid tumours and their possible pathogenetic significance. *The British Journal of Dermatology.* 2009; 161(2):364-372. https://doi.org/10.1111/j.1365-2133.2009.09181.x
24. Busam KJ, Kutzner H, Cerroni L, Wiesner T. Clinical and pathologic findings of Spitz nevi and atypical Spitz tumors with ALK fusions. *The American Journal of Surgical Pathology*. 2014;38(7):925-933. https://doi.org/10.1097/PAS.0000000000000187
25. Gerami P, Jewell SS, Morrison LE, Blondin B, Schulz J, Ruffalo T, Matushek P. 4th, Legator M, Jacobson K, Dalton SR, Charzan S, Kolaitis NA, Guitart J, Lertsbarapa T, Boone S, LeBoit PE, Bastian BC. Fluorescence *in situ* hybridization (FISH) as an ancillary diagnostic tool in the diagnosis of melanoma. *The American Journal of Surgical Pathology*. 2009;33(8):1146-1156. https://doi.org/10.1097/PAS.0b013e3181a1ef36
26. Wiesner T, Kutzner H, Cerroni L, Mihm MC Jr, Busam KJ, Murali R. Genomic aberrations in spitzoid melanocytic tumours and their implications for diagnosis, prognosis and therapy. *Pathology*. 2016;48(2):113-131. https://doi.org/10.1016/j.pathol.2015.12.007
27. Gelbard SN, Tripp JM, Marghoob AA, Kopf AW, Koenig KL, Kim JY, Bart RS. Management of Spitz nevi: a survey of dermatologists in the United States. *Journal of the American Academy of Dermatology*. 2002;47(2):224-230. https://doi.org/10.1067/mjd.2002.121031
28. Metzger AT, Kane AA, Bayliss SJ. Differences in treatment of Spitz nevi and atypical Spitz tumors in pediatric patients among dermatologists and plastic surgeons. *JAMA Dermatology*. 2013;149(11):1348-1350. https://doi.org/10.1001/jamadermatol.2013.4947
29. Tlougan BE, Orlow SJ, Schaffer JV. Spitz nevi: beliefs, behaviors, and experiences of pediatric dermatologists. *JAMA Dermatology*. 2013;149(3):283-291. https://doi.org/10.1001/jamadermatol.2013.1124
30. Pizzichetta MA, Argenziano G, Grandi G, de Giacomi C, Trevisan G, Soyer HP. Morphologic changes of a pigmented Spitz nevus assessed by dermoscopy. *Journal of the American Academy of Dermatology*. 2002;47(1):137-139. https://doi.org/10.1067/mjd.2002.122193
31. Lallas A, Apalla Z, Ioannides D, Lazaridou E, Kyrgidis A, Broganelli P, Alfano R, Zalaudek I, Argenziano G. Update on dermoscopy of Spitz/Reed naevi and management guidelines by the International Dermoscopy Society. *The British Journal of Dermatology.* 2017;177(3):645-655. https://doi.org/10.1111/bjd.15339
32. Nino M, Brunetti B, Delfino S, Brunetti B, Panariello L, Russo D. Spitz nevus: follow-up study of 8 cases of childhood starburst type and proposal for management. *Dermatology*. 2009;218(1):48-51. https://doi.org/10.1159/000161120
33. Argenziano G, Agozzino M, Bonifazi E, Broganelli P, Brunetti B, Ferrara G, Fulgione E, Garrone A, Zalaudek I. Natural evolution of Spitz nevi. *Dermatology*. 2011;222(3):256-260. https://doi.org/10.1159/000326109
34. Broganelli P, Titli S, Lallas A, Alaibac M, Annetta A, Battarra V, Brunetti B, Castagno I, Cavicchini S, Ferrari A, Ghigliotti G, Landi C, Manganoni A, Moscarella E, Pellacani G, Pizzichetta MA, Rosina P, Rubegni P, Satta R, Scalvenzi M, Stanganelli I, Stinco G, Zalaudek I, Zampieri P, Argenziano G. Spitz/Reed nevi: proposal of management recommendations by the Dermoscopy Study Group of the Italian Society of Dermatology (SIDeMaST). *Giornale Italiano di Dermatologia e Venereologia*. 2014;149(5):601-606.
35. Lallas A, Moscarella E, Longo C, Kyrgidis A, de Mestier Y, Vale G, Guida S, Pellacani G, Argenziano G. Likelihood of finding melanoma when removing a Spitzoid-looking lesion in patients aged 12 years or older. *Journal of the American Academy of Dermatology*. 2015;72(1):47-53. https://doi.org/10.1016/j.jaad.2014.09.037

36. Costa C, Megna M, Cappello M, Napolitano M, Monfrecola G, Scalvenzi M. Melanoma frequency among symmetrical Spitzoid-looking lesions: a retrospective study. *Giornale Italiano di Dermatologia e Venereologia*. 2019; 154(1):26-31.
https://doi.org/10.23736/S0392-0488.17.05523-7

37. Murphy ME, Boyer JD, Stashower ME, Zitelli JA. The surgical management of Spitz nevi. *Dermatologic Surgery*. 2002;28(11):1065-1069.
https://doi.org/10.1046/j.1524-4725.2002.02067.x

38. Casso EM, Grin-Jorgensen CM, Grant-Kels JM. Spitz nevi. *Journal of the American Academy of Dermatology*. 1992;27(6 Pt 1):901-913.
https://doi.org/10.1016/0190-9622(92)70286-o

39. Argenziano G, Soyer HP, Chimenti S, Talamini R, Corona R, Sera F, Binder M, Cerroni L, De Rosa G, Ferrara G, Hofmann-Wellenhof R, Landthaler M, Menzies SW, Pehamberger H, Piccolo D, Rabinovitz HS, Schiffner R, Staibano S, Stolz W, Bartenjev I, Blum A, Braun R, Cabo H, Carli P, De Giorgi V, Fleming MG, Grichnik JM, Grin CM, Halpern AC, Johr R, Katz B, Kenet RO, Kittler H, Kreusch J, Malvehy J, Mazzocchetti G, Oliviero M, Ozdemir F, Peris K, Perotti R, Perusquia A, Pizzichetta MA, Puig S, Rao B, Rubegni P, Saida T, Scalvenzi M, Seidenari S, Stanganelli I, Tanaka M, Westerhoff K, Wolf IH, Braun-Falco O, Kerl H, Nishikawa T, Wolff K, Kopf AW. Dermoscopy of pigmented skin lesions: results of a consensus meeting via the Internet. *Journal of the American Academy of Dermatology*. 2003;48(5):679-693.
https://doi.org/10.1067/mjd.2003.281

40. Nachbar F, Stolz W, Merkle T, Cognetta AB, Vogt T, Landthaler M, Bilek P, Braun-Falco O, Plewig G. The ABCD rule of dermatoscopy. High prospective value in the diagnosis of doubtful melanocytic skin lesions. *Journal of the American Academy of Dermatology*. 1994;30(4):551-559.

41. Haenssle HA, Fink C, Schneiderbauer R, Toberer F, Buhl T, Blum A, Kalloo A, Hassen ABH, Thomas L, Enk A, Uhlmann L. Man against machine: diagnostic performance of a deep learning convolutional neural network for dermoscopic melanoma recognition in comparison to 58 dermatologists. *Annals of Oncology*. 2018;29(8):1836-1842.
https://doi.org/10.1093/annonc/mdy166

42. Haenssle HA, Fink C, Toberer F, Winkler J, Stolz W, Deinlein T, Hofmann-Wellenhof R, Lallas A, Emmert S, Buhl T, Zutt M, Blum A, Abassi MS, Thomas L, Tromme I, Tschandl P, Enk A, Rosenberger A. Man against machine reloaded: performance of a market-approved convolutional neural network in classifying a broad spectrum of skin lesions in comparison with 96 dermatologists working under less artificial conditions. *Annals of Oncology*. 2020;31(1):137-143.
https://doi.org/10.1016/j.annonc.2019.10.013

43. Sergeev YuYu, Mordovtseva VV. Experience in the diagnosis of skin melanoma smaller than 6 mm in diameter. *Russian Journal of Clinical Dermatology and Venereology = Klinichaskaya dermatologiya i venerologiya*. 2018;17(4): 97-105. (In Russ.).
https://doi.org/10.17116/klinderma20181704197

Received 16.04.2020
Accepted 25.01.2021