Хирургия. Журнал имени Н.И. Пирогова
2026, №8, с. 16–22
https://doi.org/10.17116/hirurgia202608116

Pirogov Russian Journal of Surgery
2026, No.8, pp. 16–22
https://doi.org/10.17116/hirurgia202608116

Surgical treatment for traumatic bowel injury

© Z.A. Bagatelia[1, 2], D.N. Grekov[1, 2], A.A. Karpov[1, 2], A.A. Kolotilshchikov[2], M.Z. Eminov[1, 2], A.V. Ankin[2], M.V. Petrishin[2]

[1]Botkin Hospital, Moscow, Russia;
[2]Russian Medical Academy of Continuous Professional Education, Moscow, Russia

Abstract

Objective. To study treatment outcomes in patients with traumatic bowel injury in peacetime.

Material and methods. A retrospective study involved 27 patients with traumatic bowel injury who underwent surgery at Botkin Hospital in 2016-2024. All patients were delivered to the shock room of the emergency department for initial examination. In 25 cases, we performed contrast-enhanced CT before surgery; 2 patients were sent to the operating theater immediately.

Results. Primary repair of small bowel was performed in 4 patients, small bowel resection — in 12 patients, colon resection — in 8 patients. Primary anastomosis was formed in 12 cases, ileostomy/colostomy — in 11 patients. Risk factors for primary anastomosis are unstable hemodynamics requiring inotropic support; massive transfusion therapy; fecal contamination of abdominal cavity; more than 6-hour preoperative period.

Conclusion. Available experience, damage control surgery and necessary reconstruction of bowel continuity inspired own treatment algorithm for this category of patients to reduce morbidity and mortality.

Keywords: *bowel injury, intestine trauma, colon trauma, damage control surgery.*

Information about the authors:
Bagateliya Z.A. — https://orcid.org/0000-0001-5699-3695
Grekov D.N. — https://orcid.org/0000-0001-8391-1210
Karpov A.A. — https://orcid.org/0000-0002-5142-1302
Kolotilshchikov A.A. — https://orcid.org/0000-0002-9294-4724
Eminov M.Z. — https://orcid.org/0000-0001-7848-2933
Ankin A.V. — https://orcid.org/0009-0009-5627-0345
Petrishin M.V. — https://orcid.org/0009-0009-9994-0871
Corresponding author: Kolotilshchikov A.A. — e-mail: kolotun2110@inbox.ru

To cite this article:
Bagatelia ZA, Grekov DN, Karpov AA, Kolotilshchikov AA, Eminov MZ, Ankin AV, Petrishin MV. Surgical treatment for traumatic bowel injury. *Pirogov Russian Journal of Surgery.* 2026;8:16–22. (In Russ.). https://doi.org/10.17116/hirurgia202608116

Тактика хирургического лечения при травматическом повреждении кишечника

© Зураб Антонович Багателия[1, 2], Дмитрий Николаевич Греков[1, 2], Алексей Андреевич Карпов[1, 2], Андрей Александрович Колотильщиков[2], Махир Зиядович Эминов[1, 2], Алексей Васильевич Анькин[2], Михаил Валерьевич Петришин[2]

[1]ГБУЗ «Московский многопрофильный научно-клинический центр им. С.П. Боткина Департамента здравоохранения города Москвы», Москва, Россия;
[2]ФГБОУ ДПО «Российская медицинская академия непрерывного профессионального образования» Минздрава России, Москва, Россия

Резюме

Цель исследования. Изучение результатов лечения пациентов с травматическим повреждением кишечника в условиях мирного времени.

Материал и методы. Проведено ретроспективное исследование, включающее 27 пациентов с травматическим повреждением кишечника, оперированных в ММНКЦ им. С.П. Боткина в период с 2016 по 2024 г. Все пациенты доставлены в шоковый зал отделения неотложной помощи, где проходили первичное обследование. В 25 случаях выполнена компьютерная томография (КТ) с внутривенным контрастированием, при которой выявлены необходимые изменения для подозрения или подтверждения диагноза. Во всех случаях хирургическое лечение выполнялось традиционным доступом (лапаротомией).

Результаты. Выполнено ушивание дефекта стенки тонкой кишки 4 пациентам, резекция тонкой кишки — 12, резекция толстой кишки — 8. Первичный межкишечный анастомоз сформирован в 12 случаях; 11 пациентам выполнена илео-/колостомия. Противопоказаниями к формированию первичного анастомоза служат нестабильная гемодинамика, требующая инотропной поддержки, массивная трансфузионная терапия, фекальная контаминация брюшной полости; сроки до операции более 6 ч.

Заключение. Накопленный небольшой опыт, применение стратегии контроля повреждения — DCS (damage control surgery) и необходимость в восстановлении непрерывности кишечной трубки послужили основой для формирования собственного алгоритма лечения пациентов данной категории, который направлен на снижение риска развития осложнений и летальности.

Ключевые слова: *повреждение кишечника, травма тонкой кишки, травма толстой кишки, damage control surgery.*

Информация об авторах:
Багателия З.А. — https://orcid.org/0000-0001-5699-3695
Греков Д.Н. — https://orcid.org/0000-0001-8391-1210
Карпов А.А. — https://orcid.org/0000-0002-5142-1302
Колотильщиков А.А. — https://orcid.org/0000-0002-9294-4724
Эминов М.З. — https://orcid.org/0000-0001-7848-2933
Анькин А.В. — https://orcid.org/0009-0009-5627-0345
Петришин М.В. — https://orcid.org/0009-0009-9994-0871
Автор, ответственный за переписку: Колотильщиков А.А. — e-mail: kolotun2110@inbox.ru

Как цитировать:
Багателия З.А., Греков Д.Н., Карпов А.А., Колотильщиков А.А., Эминов М.З., Анькин А.В., Петришин М.В. Тактика хирургического лечения при травматическом повреждении кишечника. *Хирургия. Журнал им. Н.И. Пирогова*. 2026;8:16–22. https://doi.org/10.17116/hirurgia202608116

Introduction

Abdominal trauma is one of the most common causes of death in traumatic injuries. It accounts for nearly 25% of all trauma cases and tends to increase over the years [1, 2]. Traumatic injuries of hollow organs and mesentery are relatively rare and account for approximately 1%. Intestinal trauma most often follows penetrating wounds and accounts for approximately 17% [3]. Mortality can reach 15% [2].

Delayed diagnosis increases mortality, primarily due to septic complications. A delay of more than 5 hours can lead to peritonitis and multiple organ failure. Furthermore, there is a close correlation between delayed diagnosis and longer hospital-stay due to severe clinical status [4].

Among hollow organ injuries, small intestinal injuries account for 30—38% (with predominant jejunum damage near duodenojejunal junction), colon injuries — 3—13%, stomach injuries — 2—3%, duodenum injuries — 1.2—10% [5].

Mechanisms of hollow organ injury distinguish between crushing caused by compression on skeletal bones, avulsion associated with tangential impact on mesenteric margin and rupture primary due to intraluminal gas. Damage types include rupture of serous or mucous membrane, hematoma of intestinal wall or mesentery, perforation or crushing of the organ [6].

Clinical data depend on injury type and its timing. Shock and various disorders of consciousness complicate diagnosis [7]. Intestinal trauma detection rate may be only 16% among patients with combined injuries accompanied by severe traumatic brain injury [8].

FAST (Focused Assessment with Sonography for Trauma) protocol in a patient with abdominal trauma is the primary diagnostic step. The most important objective is to answer two clinically significant questions: is there free fluid in abdominal, pleural and pericardial cavities (with analysis of volume) and is there a pneumothorax? Sensitivity of ultrasound for detecting hemoperitoneum, hemopericardium and hemothorax is 85—96%, specificity – over 98%.

According to international data, sensitivity of ultrasound in diagnosing traumatic injuries of small intestine and colon is low (only 40—63%) [9]. In this regard, computed tomography (CT) has become the most important diagnostic method with sensitivity 88% and specificity 72% [10]. There are direct and indirect CT signs of bowel injury. Direct signs include intestinal wall rupture, free gas in abdominal cavity and extraluminal contrast agent leakage. Indirect signs are more common and include fluid in abdominal cavity, thickening or dissection of intestinal wall [6, 7]. However, indirect signs can yield both false-positive and false-negative results. Therefore, CT should not be considered a definitive diagnostic method. To clarify the diagnosis, diagnostic laparoscopy is recommended if indicated [3].

Laparoscopy is a minimally invasive diagnostic and therapeutic method. In hands of an experienced surgeon, laparoscopic exploration of abdominal organs is comparable to exploratory laparotomy [11]. In a meta-analysis of 3,362 laparoscopies for abdominal trauma, clinically significant injuries were missed only twice [12]. Laparoscopy is considered useful in hemodynamically stable patients. Peritonitis and/or unstable clinical status are indications for laparotomy [3]. However, there are currently no significant data indicating superiority of diagnostic laparoscopy, and further discussion is needed [13].

Thus, difficult diagnosis of traumatic bowel injury in patients with abdominal trauma and ambiguous treatment strategies inspired this study.

Material and methods

There were 648 patients with traumatic abdominal injuries between 2016 and 2024.

Of these, 27 (4.2%) patients had a hollow organ injury (11 (40.7%) patients with open abdominal trauma and 16 (59.3%) with blunt abdominal trauma). Isolated bowel injury was observed in 8 cases, bowel injury as a part of combined trauma — in 19 cases. Damage to small intestine was the most common (13 (48.2%) patients). Four (14.8%) patients had sigmoid colon injuries, two (7.4%) — transverse colon injuries, three (11.1%) — splenic flexure injuries, one (3.7%) — cecum injury. Combined traumatic injury of small and large intestines was diagnosed in 4 (14.8%) cases.

Baseline examination of all patients was performed in shock chamber of intensive care unit («red zone» of emergency department). Baseline diagnostic algorithm included objective examination with assessment of clinical status, vital functions and FAST protocol data. Intensive care specialists simultaneously administered anti-shock measures to stabilize clinical status.

Two (7.4%) patients were urgently referred to the operating theater due to severe injury, unstable hemodynamics and positive FAST. Laparotomy revealed traumatic bowel injury.

In 25 (92.6%) patients, a whole-body contrast-enhanced CT was performed as a further diagnostic step. CT revealed signs of intestinal wall damage. In retrospective analysis of CT data, direct signs of injury, such as free gas in abdominal cavity and intestinal wall defects, were used as indicators of intestinal injury in 15 (60%) cases. In 10 (40%) patients, CT revealed indirect signs, such as free fluid in abdominal cavity, areas of intestinal wall hypoperfusion and infiltration or gas bubbles in mesentery with suspected intestinal injury. There were no cases of intestinal wall damage without radiographic changes **(Fig. 1)**.

Diagnostic laparoscopy was required in 6 (27.8%) patients. In 5 cases, access conversion was performed upon confirmation of diagnosis. In one case, we imposed intracorporeal sero-serous sutures due to a 3-mm-diameter ileum injury (AAST grade 1). Several diagnostic laparoscopies without bowel injury were not included in analysis.

Traumatic bowel injury was classified using the AAST (The American Association for the Surgery of Trauma) scale. Grade 1 injury (hematoma or serosal wall injury) was observed in one case (3.7%), grade 2 injuries (incomplete wall rupture < 50% of circumference) — in 5 (18.6%) patients, grade III (incomplete intestinal wall rupture > 50% of circumference) — in 6 (22.2%) patients, grade IV bowel injury (complete intestinal wall rupture) — in 9 (33.3%) patients. Mesenteric rupture with segmental devascularization of intestine (grade V) was detected in 6 (22.2%) cases **(Table)**.

Certain parameters such as gender, age and comorbidities were not assessed due to no influence on surgical approach.

Results

We attempted to repair small intestinal wall defect in 6 (22.2%) patients. This method was final for 2 (7.4%) patients (one underwent laparoscopic surgery, and an-

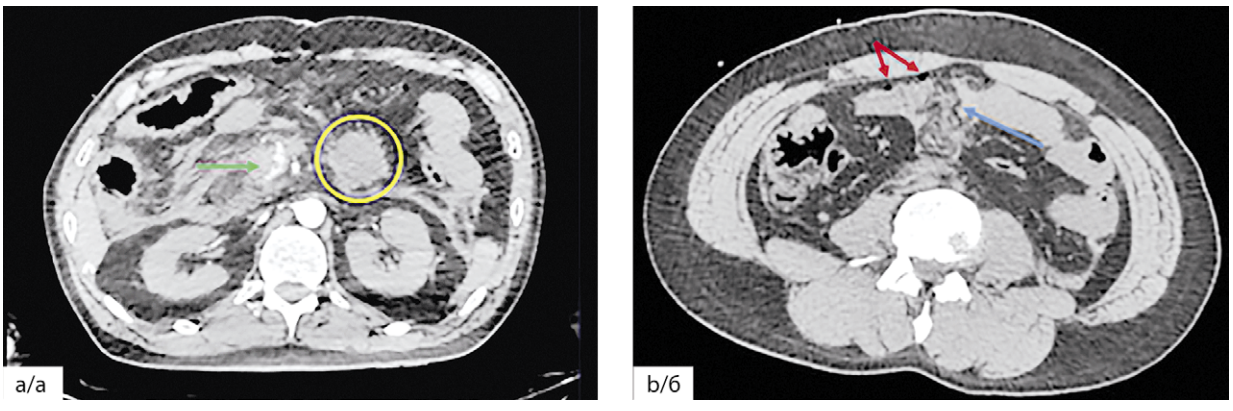

Fig. 1. Contrast-enhanced CT, axial scan.
a — traumatic small intestine injury (yellow circle — mesenteric hematoma; green arrow — extravasation into mesentery); b — small intestine traumatic injury (red arrow — free gas bubbles in abdominal cavity; blue arrow — site of small intestine destruction).

Рис. 1. Компьютерные томограммы с внутривенным болюсным усилением, аксиальная реконструкция.
а — картина травматического повреждения тонкой кишки, где желтый круг — гематома брыжейки тонкой кишки, зеленая стрелка — участок экстравазации в брыжейку тонкой кишки; б — картина травматического повреждения тонкой кишки: красная стрелка — пузырьки свободного газа в брюшной полости, синяя стрелка — участок деструкции тонкой кишки.

AAST grades of small and large bowel injuries
Классификация повреждений тонкой и толстой кишки Американской ассоциации хирургии травм (The American Association for the Surgery of Trauma)

Grade	Type of injury	Description of injury	Our data
I	Hematoma	Contusion or hematoma without devascularization	—
	Laceration	Partial thickness, no perforation	1 patient
II	Laceration	Laceration <50% of circumference	5 patients
III	Laceration	Laceration ⩾50% of circumference without transection	6 patients
IV	Laceration	Transection of the small bowe	9 patients
V	Laceration	Transection of the small bowel with segmental tissue loss	4 patients
	Vascular damage	Devascularized segment	2 patients

other one — laparotomy). Laparoscopic closure of serosal injury implied interrupted intracorporeal sero-serous monofilament absorbable sutures with atraumatic needle. In case of laparotomy, closure of serosal injury implied double-row interrupted monofilament absorbable sutures with atraumatic needle. No complications were observed in these patients. Other four patients required an expanded surgical procedure with resection.

Small bowel resection was performed in 12 (44.4%) patients. In most cases (n=8, 66.7%), the cause of resection was mesenteric trauma with small intestinal segment devascularization. Enteroenterostomy was formed in 9 (75%) patients. In one of these patients, indocyanine green angiography was used at the stage of interintestinal anastomosis to assess intestinal wall perfusion. The purpose of this technique is to minimize the risk of potential interintestinal anastomotic leakage. Final Brooke ileostomy was performed in 3 (25%) patients.

Colonic defect suturing was performed in 2 (7.4%) patients, colon resection — in 8 (29.6%) cases. In 3 (37.5%) patients, enteroenterostomy was performed within 24—48 hours after primary right-sided hemicolectomy (damage-control surgery (DCS) concept). End colostomy was created in five (62.5%) patients. In 3 (11.1%) cases, transverse colon defect site was used to create a double-barreled transverse colostomy.

There were 8 (29.6%) postoperative complications: interintestinal anastomotic leakage in 2 (25%) cases, interintestinal abscess in 1 (12.5%) patient and postoperative laparotomy infection in 4 (50%) cases. Postoperative mortality rate was 7.4%. Two patients with severe concomitant trauma died (severe pelvic trauma, closed fractures of tibiae, traumatic splenic injury (AAST grade IV) and massive blood loss in one case, concomitant liver injury (AAST grade IV), multiple rib fractures and traumatic brain injury in another case).

Discussion

Surgical treatment for traumatic bowel injury includes primary defect closure, intestine resection with or without anastomosis and intestinal stoma [3]. These interventions are applicable to injuries of small and large intestines [14]. Currently, there are no standardized treatment approaches for injuries of any intestinal segments.

Primary closure is generally considered for injuries AAST grade I and II. Intestine resection is performed for grade III—V injuries. Anastomosis with intestinal tube repair is a priority. Currently, there is some discrepancy between DCS strategy and evidence-based medicine. In interests of surgical time at primary laparotomy, anastomosis is not imposed within damage control concept, and decision is made in favor of delayed surgery [15]. A retrospective study of interventions in Iraqi war soldiers with colon injuries revealed significantly lower rate of anastomotic leakage for DCS concept (10% versus 25%) [16]. Modern analysis of patients with primary and delayed anastomosis in peacetime trauma, on the contrary, demonstrated higher incidence of suture failure among patients with delayed anastomoses (18% versus 10% for primary anastomosis) [17].

In available literature, we identified the following contraindications for primary anastomosis: unstable hemodynamics requiring inotropic support, massive transfusion therapy, fecal contamination of abdominal cavity, preoperative period > 6 hours [18, 19]. These criteria correlate with high-risk group for colon injury formulated in the 2019 Eastern Association for the Surgery of Trauma guidelines. Analysis of 16 prospective studies concluded that resection with anastomosis results in lower incidence of septic complications compared to intestinal stoma in high-risk patients [20]. Tantardini C. et al. [21] found that the same criteria were suitable for small intestinal injuries.

Massive blood transfusion is a significant risk factor for unfavorable perioperative course in patients with severe trauma. Negative consequences of massive transfusion therapy are well known: stimulation of systemic inflammatory response increasing the incidence of infectious complications, fluid and electrolyte imbalances, thrombosis and worsening organ dysfunction, particularly due to TRALI syndrome (transfusion-associated acute lung injury) [22, 23]. Demetriades D. et al. [18] recognized transfusion of more than 4 units of packed red blood cells within 24 hours after admission as a standardized quantitative risk factor.

Anastomotic leakage in patients with traumatic bowel injury significantly increases mortality up to 50% [3]. ICG angiography can potentially reduce the risk of suture fail-

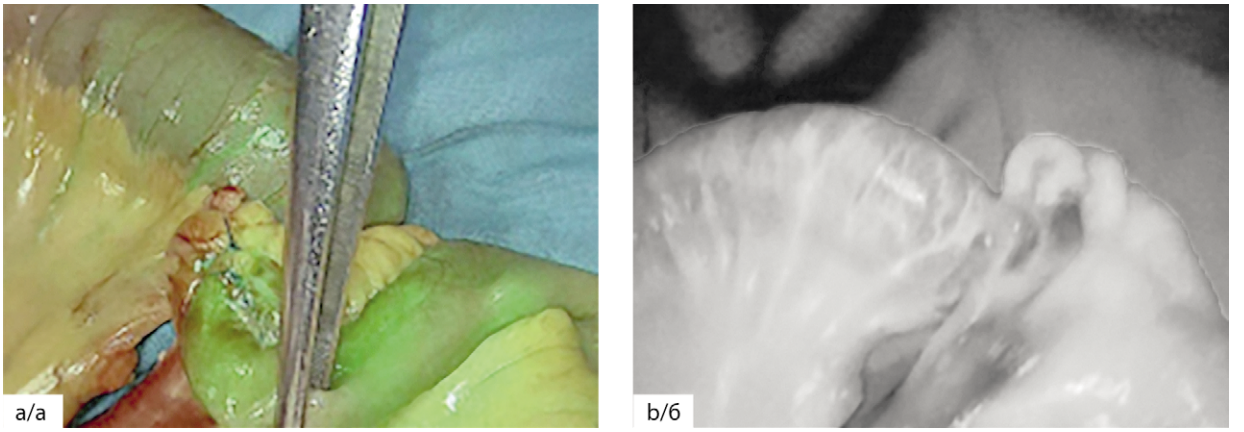

Fig. 2. Intraoperative ICG navigation in polychromatic (a) and monochrome (b) modes (resected small bowel stumps are visible at second-look laparotomy).
Рис. 2. Интраоперационная ICG-навигация в полихромном (а) и монохромном (б) режимах (видны культи резецированной тонкой кишки при second-look лапаротомии).

ure by allowing preliminary assessment of intestinal wall perfusion. Afifi I. et al. [24] described three cases of successful ICG angiography for peacetime bowel trauma. In two cases, ICG angiography verified adequate blood supply to anastomosis. In one case, angiography necessitated more aggressive resection with subsequent anastomosis. No suture leaks were recorded.

We performed ICG angiography in one patient at second-look laparotomy after previous small bowel resection for AAST grade V injury **(Fig. 2)**. Evaluation of perfusion in stump and subsequent anastomosis allowed us to eliminate the risk of anastomotic leakage. Therefore, this technique is very promising. However, there are few studies with minimal sample sizes devoted to its effectiveness in trauma patients. Further large-scale prospective studies are needed to determine the role of ICG fluorescence in traumatic bowel injury.

Adherence to DCS strategy and a trend towards bowel repair allowed us to adopt the following surgical approach for bowel trauma **(Fig. 3)**. Preoperative CT and AAST grade are essential for selection of surgical method.

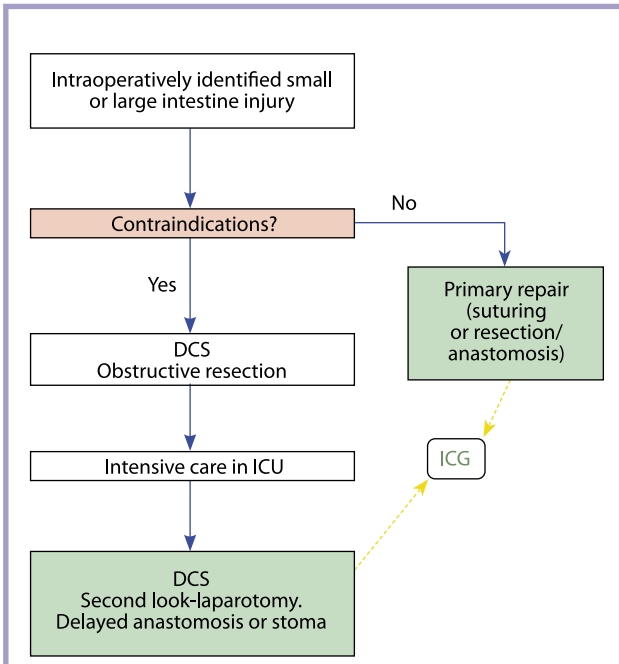

Fig. 3. Surgical strategy for traumatic bowel injury.
Рис. 3. Стратегия хирургического лечения при травматическом повреждении кишечника.

Conclusion

Thus, surgical treatment of traumatic bowel injuries is still a complex objective, and outcomes depend on timely diagnosis. Early detection of injury based on all available diagnostic tools (from ultrasound to computed tomography) minimizes delays in surgical intervention. This is a key factor in preventing fatal septic complications.

A thorough intraoperative examination of the entire intestine is essential to identify all injuries, including hidden ones. Surgical method (from wound suturing to resection and anastomosis) should be strictly individualized and based on assessment of intestinal wall viability. In this context, intraoperative ICG angiography demonstrates particular promise, allows for objective assessment of tissue perfusion and significantly reduces the risk of anastomotic failure.

Thus, a modern approach to treating bowel injuries is based on the principles of early diagnosis, appropriate

surgical management and promising technologies such as ICG imaging.

This treatment strategy reduces mortality and improves the quality of life after traumatic bowel injuries.

Participation of authors:
Concept and design of the study — Bagatelia Z.A., Grekov D.N., Karpov A.A., Kolotilshchikov A.A.
Collection and analysis of data — Karpov A.A., Eminov M.Z., Ankin A.V., Petrishin M.V.
Statistical analysis — Karpov A.A., Ankin A.V., Petrishin M.V.
Writing the text — Bagatelia Z.A., Grekov D.N., Karpov A.A., Kolotilshchikov A.A., Eminov M.Z., Ankin A.V., Petrishin M.V.
Editing — Bagatelia Z.A., Grekov D.N., Karpov A.A.

Участие авторов:
Концепция и дизайн исследования — Багателия З.А., Греков Д.Н., Карпов А.А., Колотильщиков А.А.
Сбор и обработка материала — Карпов А.А., Эминов М.З., Анькин А.В., Петришин М.В.
Статистическая обработка — Карпов А.А., Анькин А.В., Петришин М.В.
Написание текста — Багателия З.А., Греков Д.Н., Карпов А.А., Колотильщиков А.А., Эминов М.З., Анькин А.В., Петришин М.В.
Редактирование — Багателия З.А., Греков Д.Н., Карпов А.А.

The authors declare no conflicts of interest.
Авторы заявляют об отсутствии конфликта интересов.

REFERENCES/ЛИТЕРАТУРА

1. Rosen, Carlo Legome, Eric Wolfe, Richard. Blunt Abdominal Trauma. 2013. https://doi.org/10.1016/B978-1-4377-3548-2.00079-3
2. Menyar A, Abdelrahman H, Al-Thani H, Zarour A, Parchani A, Peralta R, Latifi R. Compartmental anatomical classification of traumatic abdominal injuries from the academic point of view and its potential clinical implication. *J Trauma Manag Outcomes.* 2014;8:14. https://doi.org/10.1186/1752-2897-8-14
3. Smyth L, Bendinelli C, Lee N et al. WSES guidelines on blunt and penetrating bowel injury: diagnosis, investigations, and treatment. *World J Emerg Surg.* 2022;17:13. https://doi.org/10.1186/s13017-022-00418-y
4. Malinoski DJ, Patel MS, Yakar DO, Green D, Qureshi F, Inaba K, Brown CV, Salim A. A diagnostic delay of 5 hours increases the risk of death after blunt hollow viscus injury. *J Trauma.* 2010;69(1):84-87. https://doi.org/10.1097/TA.0b013e3181db37f5
5. Миннуллин М.М., Красильников Д.М., Зайнуллин И.В., Толстиков А.П., Зефиров Р.А. Хирургическая тактика при изолированных повреждениях тонкой и толстой кишки. *ПМ.* 2016;5(97).
Minnullin MM, Krasilnikov DM, Zainullin IV, Tolstikov AP, Zefirov RA. Surgical tactics for isolated injuries of the small and large intestine. *PM.* 2016;5(97).
6. Knipe H, Le L, Hacking C, et al. Bowel and mesenteric trauma. Reference article, Radiopaedia.org (Accessed on 28 Jun 2025). https://doi.org/10.53347/rID-26357
7. Landry, Bret Patlas, Michael Faidi, Samir Coates, Angela Nicolaou, Savvas. Are We Missing Traumatic Bowel and Mesenteric Injuries? *Canadian Association of Radiologists Journal.* 2016. https://doi.org/10.1016/j.carj.2015.11.006
8. LeBedis CA, Anderson Stephan W, Soto Jorge A. CT Imaging of Blunt Traumatic Bowel and Mesenteric Injuries. *Radiol Clin North Am.* 2012;50(1):123-136. https://doi.org/10.1016/j.rcl.2011.08.003
9. Savoia P, Jayanthi SK, Chammas MC. Focused Assessment with Sonography for Trauma (FAST). *J Med Ultrasound.* 2023;31(2):101-106. https://doi.org/10.4103/jmu.jmu_12_23
10. Jawad H, Raptis C, Mintz A, Schuerer D, Mellnick V. Single-Contrast CT for Detecting Bowel Injuries in Penetrating Abdominopelvic Trauma. Am J Roentgenol. 2018;210(4):761-765. https://doi.org/10.2214/AJR.17.18496
11. Bain K, Meytes V, Chang GC, Timoney MF. Laparoscopy in penetrating abdominal trauma is a safe and effective alternative to laparotomy. *Surg Endosc.* 2019;33(5):1618-1625. https://doi.org/10.1007/s00464-018-6436-1
12. Hajibandeh S, Hajibandeh S, Gumber AO, Wong CS. Laparoscopy versus laparotomy for the management of penetrating abdominal trauma: A systematic review and meta-analysis. *Int J Surg.* 2016;34:127-136. https://doi.org/10.1016/j.ijsu.2016.08.524
13. Justin V, Fingerhut A, Uranues S. Laparoscopy in Blunt Abdominal Trauma: for Whom? When?and Why? *Curr Trauma Rep.* 2017;3(1):43-50. https://doi.org/10.1007/s40719-017-0076-0
14. Yamamoto R, Logue AJ, Muir MT. Colon Trauma: Evidence-Based Practices. *Clin Colon Rectal Surg.* 2018;31(1):11-16. https://doi.org/10.1055/s-0037-1602175
15. Ordoñez CA, Pino LF, Badiel M, Sánchez AI, Loaiza J, Ballestas L, Puyana JC. Safety of performing a delayed anastomosis during damage control laparotomy in patients with destructive colon injuries. *J Trauma.* 2011;71(6):1512-1517; discussion 1517-8. https://doi.org/10.1097/TA.0b013e31823d0691
16. Vertrees A, Wakefield M, Pickett C, Greer L, Wilson A, Gillern S, Nelson J, Aydelotte J, Stojadinovic A, Shriver C. Outcomes of primary repair and primary anastomosis in war-related colon injuries. *J Trauma.* 2009;66(5):1286-1291; discussion 1291-3. https://doi.org/10.1097/TA.0b013e31819ea3fc
17. Ordoñez CA, Parra MW, Caicedo Y, Padilla N, Angamarca E, Serna JJ, Rodríguez-Holguín F, García A, Salcedo A, Pino LF, González-Hadad A, Herrera MA, Quintero L, Hernández F, Franco MJ, Aristizábal G, Toro LE, Guzmán-Rodríguez M, Coccolini F, Ferrada R, Ivatury R. Damage control surgical management of combined small and large bowel injuries in penetrating trauma: Are ostomies still pertinent? *Colomb Med (Cali).* 2021;52(2):e4114425. https://doi.org/10.25100/cm.v52i2.4425
18. Demetriades D, Murray JA, Chan L, Ordoñez C, Bowley D, Nagy KK, Cornwell EE 3rd, Velmahos GC, Muñoz N, Hatzitheofilou C, Schwab CW, Rodriguez A, Cornejo C, Davis KA, Namias N, Wisner DH, Ivatury RR, Moore EE, Acosta JA, Maull KI, Thomason MH, Spain DA; Committee on Multicenter Clinical Trials. American Association for the Surgery of Trauma. Penetrating colon injuries requiring resection: diversion or primary anastomosis? An AAST prospective multicenter study. *J Trauma.* 2001;50(5):765-775. https://doi.org/10.1097/00005373-200105000-00001
19. Faria GR, Almeida AB, Moreira H et al. Prognostic Factors for Traumatic Bowel Injuries: Killing Time. *World J Surg.* 2012;36:807-812. https://doi.org/10.1007/s00268-012-1458-7
20. Cullinane DC, Jawa RS, Como JJ, Moore AE, Morris DS, Cheriyan J, Guillamondegui OD, Goldberg SR, Petrey L, Schaefer GP, Khwaja KA, Rowell SE, Barbosa RR, Bass GA, Kasotakis G, Robinson BRH. Management of penetrating intraperitoneal colon injuries: A meta-analysis and practice management guideline from the East-

ern Association for the Surgery of Trauma. *J Trauma Acute Care Surg*. 2019;86(3):505-515.
https://doi.org/10.1097/TA.0000000000002146

21. Tantardini C, Godiris-Petit G, Noullet S et al. Management of the injured bowel: preserving bowel continuity as a gold standard. *BMC Surg*. 2021;21:339.
https://doi.org/10.1186/s12893-021-01332-x

22. Dries DJ. The contemporary role of blood products and components used in trauma resuscitation. *Scand J Trauma Resusc Emerg Med*. 2010;18:63.
https://doi.org/10.1186/1757-7241-18-63

23. Sihler KC, Napolitano LM. Complications of massive transfusion. *Chest*. 2010;137(1):209-220.
https://doi.org/10.1378/chest.09-0252

24. Afifi I, Abdelrahman H, El-Faramawy A, Mahmood I, Khoschnau S, Al-Naimi N, El-Menyar A, Al-Thani H, Rizoli S. The use of Indocyanine green fluorescent in patients with abdominal trauma for better intraoperative decision-making and less bowel anastomosis leak: case series. *J Surg Case Rep*. 2021;2021(6):rjab235.
https://doi.org/10.1093/jscr/rjab235

Поступила/Received 12.12.2025
Принята к печати/Accepted 13.01.2026