Pirogov Russian Journal of Surgery
2026, No. 4, pp. 22–31
https://doi.org/10.17116/hirurgia202604122

# Selection of drainage method for resectable cholangiocarcinoma complicated by obstructive jaundice

© A.N. Polyakov[1], A.G. Kotelnikov[1], V.I. Egorov[1–3], E.R. Virshke[1], D.Yu. Frantsev[1], O.N. Sergeeva[1], D.M. Kantieva[1], D.V. Podluzhny[1], A.P. Tishchenko[4]

[1]Blokhin National Cancer Research Center, Moscow, Russia;
[2]Kazan State Medical University, Kazan, Russia;
[3]Republican Clinical Oncology Dispensary, Kazan, Russia;
[4]Sechenov First Moscow State Medical University Moscow, Russia

**Abstract**

**Objective.** To compare the results of percutaneous and endoscopic biliary decompression for resectable perihilar tumor (PT).

**Material and methods.** Treatment outcomes were analyzed in patients with PT who underwent surgery between 1999 and 2023. The 1st group included patients who underwent percutaneous transhepatic cholangiostomy as the first stage for biliary decompression, the 2nd group — patients who underwent endoscopic biliary drainage.

**Results.** There were 58 patients with percutaneous transhepatic cholangiostomy and 18 ones with endoscopic biliary drainage. Both groups were comparable in main parameters. There were patients with isolated resection of extrahepatic bile ducts in the group of percutaneous transhepatic cholangiostomy, but these were absent in the 2nd group ($p$=0.328). Extended right-sided hemihepatectomies were more common in the 1st group (29.3% versus 11.1%, $p$=0.210). Post-manipulation complications grade ≥ III degree more common after endoscopic biliary drainage (50.0% versus 22.4%, $p$=0.037), and percutaneous cholangiostomy was also more common to correct complications (44.4% versus 10.3%, $p$=0.003). There was no difference in the rate of post-resection complications grade ≥III ($p$=0.787) and postoperative mortality ($p$=0.721). There was also no difference in peritoneal metastases ($p$=1.0) and implantation metastases ($p$=1.0). In addition, we found no worsening of long-term results after percutaneous transhepatic cholangiostomy. The median overall survival in this group was 25 months versus 15 months after endoscopic biliary drainage ($p$=0.740). There was also no difference in disease-free survival ($p$=0.500).

**Conclusion.** Percutaneous transhepatic cholangiostomy as the primary method for obstructive jaundice in patients with resectable PT is accompanied by better immediate results of biliary decompression without worsening the results of resection.

***Keywords:*** *perihilar tumor, extrahepatic bile duct cancer, biliary decompression, percutaneous transhepatic biliary drainage, endoscopic biliary drainage.*

**Information about the authors:**
Polyakov A.N. — https://orcid.org/0000-0001-5348-5011
Kotelnikov A.G. — https://orcid.org/0000-0002-2811-0549
Egorov V.I. — https://orcid.org/0000-0002-6603-1390
Virshke E.R. — https://orcid.org/0000-0002-4006-3642
Frantsev D.Yu. — https://orcid.org/0000-0002-6331-5611
Sergeeva O.N. — https://orcid.org/0000-0003-1932-5983
Kantieva D.M. — https://orcid.org/0000-0003-3953-0036
Podluzhny D.V. — https://orcid.org/0000-0001-7375-3378
Tishchenko A.P. — https://orcid.org/0009-0006-6304-1864
**Corresponding author:** Polyakov A.N. — e-mail: Dr.alexp@gmail.com

**To cite this article:**
Polyakov AN, Kotelnikov AG, Egorov VI, Virshke ER, Frantsev DYu, Sergeeva ON, Kantieva DM, Podluzhny DV, Tishchenko AP. Selection of drainage method for resectable cholangiocarcinoma complicated by obstructive jaundice. *Pirogov Russian Journal of Surgery.* 2026;4:22–31. (In Russ.). https://doi.org/10.17116/hirurgia202604122

## Introduction

Extrahepatic cholangiocarcinoma (CC) is almost always accompanied by obstructive jaundice [1, 2]. Even with limited involvement of the bile duct wall, this syndrome is observed in the majority of patients [3].

The choice of method for biliary decompression in operable patients with CC is a widely debated issue — there are arguments in favor of both percutaneous transhepatic biliary drainage (PTBD) and endoscopic biliary drainage (EBD). However, in international literature focusing on methods for managing complications in pa-

tients with CC, a clear preference is given to the endoscopic technique [4—7].

To justify their choice, colleagues most frequently refer to the work by R. Coelen et al. [8], as well as the studies by K. Komaya [9, 10]. The first mentioned study convincingly demonstrated poorer immediate outcomes in patients with perihilar obstruction (PO) complicated by obstructive jaundice when PTBD was used. Mortality in this group exceeded 40%, with 3 patient deaths attributed to complications of the decompression procedure itself, and an additional 8 deaths occurring after the resection phase. In the comparison group, there were no fatalities following the drainage procedure, and postoperative mortality reached 11.1% (3 out of 27 patients died) [8]. Studies by Japanese colleagues noted worse long-term outcomes in the PTBD group among patients with both common bile duct (CBD) tumors [9] and those with PO [10].

There are studies where EBD does not demonstrate an advantage over PTBD. In a study by Italian colleagues, a trend towards an increased incidence of complications following the drainage procedure was observed in the EBD patient group (47.5% vs. 38.9%; $p$=0.098); however, the drainage method had no impact on the incidence of post-resection complications [11].

A 2022 meta-analysis summarized the results of biliary decompression in 1417 patients with PO. In the PTBD group (633 patients), a positive effect of the procedure was achieved more frequently (risk ratio 3.5; 95% confidence interval — CI 2.05—5.97), while the EBD group (784 patients) had a higher risk of developing cholangitis (risk ratio 1.7; 95% CI 0.92—3.08) and requiring repeat interventions (risk ratio 11.50; 95% CI 3.51—37.70) [12].

A study from 2015 found no data indicating a worse prognosis with the use of PTBD ($p$=0.26 for overall survival). The incidence of peritoneal metastases detected after resection was comparable, at 2.7% for EBD and 3.4% for PTBD ($p$=0.71) [13].

Russian colleagues are advised to rely on a consensus document addressing issues of obstructive jaundice, which recommends PTBD as the method of choice for CC, but does not exclude EBD in cases of limited involvement of the extrahepatic bile ducts (EHBD), provided the clinical facility has the appropriate equipment and expertise [14].

## Material and methods

The study analyzed the treatment outcomes of patients with proximal extrahepatic CC who underwent surgery at the N.N. Blokhin National Medical Research Center of Oncology of the Ministry of Health of Russia from 1999 to 2023. The immediate outcomes of the biliary decompression methods were evaluated, as well as the impact of the decompression technique used on the course of the post-resection period and long-term outcomes. The compared groups were patients who underwent EBD as the first-stage procedure and patients who underwent PTBD.

Statistical analysis of the obtained data was performed using SPSS version 21 and GraphPad Prism version 6 software. Overall survival (OS) and recurrence-free survival (RFS) were calculated using the Kaplan—Meier method, and differences were assessed using the log-rank test. Qualitative characteristics were compared by constructing contingency tables and calculating the statistical significance of differences using the chi-square test with Yates' correction for 2×2 tables. The Mann—Whitney test was used to compare quantitative characteristics, with data presented as median, first and third quartiles. a two-sided p-value was used; differences with $p$<0.05 were considered statistically significant.

## Results

A total of 98 patients with perihilar tumor (PT) were operated on: 10 (10.2%) patients, whose bilirubin level was less than 50 μmol/L and who had no signs of cholangitis, were operated on without prior biliary drainage. The remaining 88 (89.8%) patients underwent biliary decompression before resection. PTBD was performed most frequently ($n$=58; 59.2%), and EBD was performed as the first stage in 18 (18.4%) cases. Patients who underwent other biliary diversion procedures ($n$=12; 12.2%), as well as patients without prior decompression ($n$=10), were excluded from further analysis.

**Table 1** presents the main characteristics of the patients ($n$=76), as well as preoperative parameters, treatment before resection, and immediate outcomes of biliary decompression. It is important to note that the patient groups with EBD ($n$=18) and PTBD ($n$=58) were balanced in terms of main parameters. There were no differences in age or body mass index. There were slightly more men in the PTBD group (53.4% vs. 33.3%; $p$=0.180). Total bilirubin levels before decompression were similar in the compared groups. The level of the CA 19-9 marker (64.1 μmol/L vs. 89.05 μmol/L; $p$=0.299), as well as the neutrophil-to-lymphocyte ratio (1.97 vs. 2.27; $p$=0.199), were lower in the EBD group than in the comparison group, but the differences were not statistically significant. It can be noted that in the PTBD group, biopsy, chemotherapy, photodynamic therapy, and portal vein embolization were performed somewhat more often before surgery, but the differences with the EBD group did not reach statistical significance for any of the listed parameters.

Despite the fact that the incidence of complications from preoperative biliary decompression was comparable in both groups ($p$=0.434), grade III or higher complications developed significantly less frequently in the PTBD group (22.4% vs. 50.0%; $p$=0.037). Furthermore, in this group, placement of a new cholangiostomy drain was required less often to manage developed complications

***Table 1.*** **Patient characteristics, preoperative treatment, immediate results of biliary decompression**

| Parameter | EBD (*n*=18) | PTBD (*n*=58) | *p* |
|---|---|---|---|
| Males, *n* (%) | 6 (33.3) | 31 (53.4) | 0.180 |
| Age, years | 57 [49.0; 66.0] | 58 [50.0; 63.0] | 0.961 |
| Body mass index, kg/m² | 25.53 [24.44; 28.08] | 25.24 [21.64; 27.84] | 0.256 |
| Bilirubinemia μmol/L, μmol/L | 250 [181.5; 284.0] | 248 [152.5; 295.5] | 0.584 |
| Preoperative CA 19-9, U/mL | 64.1 [12.6; 126.5] * | 89.05 [24.4; 319.6] * | 0.299 |
| NLR | 1.97 [1.23; 3.18] | 2.27 [1.70; 3.08] | 0.193 |
| Lobar liver atrophy, *n* (%) | 4 (22.2) | 16 (27.6) | 0.776 |
| Preoperative biopsy performed, *n* (%) | 9 (50.0) | 37 (63.8) | 0.408 |
| Verification, *n* (%) | 6 (33.3) | 22 (37.9) | 0.786 |
| Preoperative chemotherapy, *n* (%) | 0 | 3 (5.2) | 1.0 |
| Photodynamic therapy before resection, *n* (%) | 0 | 4 (6.9) | 0.567 |
| Portal vein embolization, *n* (%) | 0 | 5 (8.6) | 0.331 |
| Complications of biliary decompression, *n* (%) | 11 (61.1) | 29 (50) | 0.434 |
| Decompression complications Clavien—Dindo ⩾ III, *n* (%) | 9 (50) | 13 (22.4) | 0.037 |
| PTBD performed to manage complications, *n* (%) | 8 (44.4) | 6 (10.3) | 0.003 |

*Note.* EBD — endoscopic biliary drainage; PTBD — percutaneous transhepatic biliary drainage; NLR — neutrophil-to-lymphocyte ratio.
* — CA 19-9 levels were unknown for one patient in the EBD group and for 14 patients in the PTBD group.

(10.3%) compared to the need for conversion to percutaneous decompression in the endoscopic drainage group (44.4%; *p*=0.003) to manage complications after EBD. Notably, there were no conversions to endoscopic drainage in the PTBD group.

It should be noted that during resection, there were no differences between the groups regarding the frequency of interventions on liver segment 1 (*p*=0.591), the portal vein (*p*=1.0), or the need for the Pringle maneuver (*p*=1.0). Operative duration (*p*=0.601), blood loss volume (*p*=0.965), and the frequency of blood transfusions (*p*=1.0) were comparable **(Table 2)**. When assessing the immediate outcomes of the resection phase, a trend towards an increased incidence of complications was observed in the EBD group (100.0% vs. 82.8%; *p*=0.105), as well as in the rates of biliary-enteric anastomotic leak (50.0% vs. 36.2%; *p*=0.408) or stricture (16.7% vs. 6.9%; *p*=0.346). This may be related to the fact that there were no isolated extrahepatic bile duct resections in the EBD group, whereas in the PTBD group, such procedures were performed in 6 (10.3%) cases. Additionally, in the percutaneous intervention group, there was a trend towards performing extended right hemihepatectomies (29.3% vs. 11.1%; *p*=0.210). However, as shown earlier, no statistically significant differences were found for any of the parameters.

No differences were found between the groups in the incidence of complications ⩾ grade III according to Clavien—Dindo (44.4% vs. 39.7%; *p*=0.787), nor in the incidence of post-resection liver failure (PRLF) (27.8% vs. 20.7%; *p*=0.531). The incidence of PRLF grade B/C (5.5% vs. 5.2%; *p*=1.0) was also comparable. Mortality did not differ between the compared groups (16.7% vs. 12.4%; *p*=0.721).

As mentioned earlier, all patients without liver resection were only in the PTBD group. In more balanced groups after excluding the 6 patients without major liver resection from the analysis, no differences were found in the incidence of complications ⩾ grade III (*p*=1.0), PRLF (*p*=0.753), or PRLF grade B/C (*p*=1.0). Mortality between them was comparable (*p*=1.0).

Patients received postoperative chemotherapy with similar frequency (*p*=0.790). Photodynamic therapy (PDT) was not performed in the EBD group; in the comparison group, PDT was administered to five patients after R1—R2 resection in cases of microscopic or macroscopic residual tumor at the proximal bile duct resection margin. However, the difference in the frequency of PDT administration was not statistically significant (0 vs. 8.6%; *p*=0.331).

**Table 3** presents the results of the morphological examination, showing that the rate of macroscopically non-radical resections was comparable (5.6% in the EBD group vs. 8.6%; *p*=1.0). It is noteworthy that the proportion of R1 resections was almost two times lower in the EBD group (16.7% vs. 29.3%; *p*=0.369), but the difference was not statistically significant.

Furthermore, according to the data in **Table 3**, the groups were balanced for most morphological parameters. It is noteworthy that there were no patients with involvement of >3 lymph nodes (LN) in the EBD group; however, this did not differ significantly from the comparison group (0 vs. 12.1%; *p*=0.183). It can also be noted that the EBD group had 1.5 times fewer patients with Bismuth

***Table 2.*** **Results of the resection, postoperative therapy**

| Parameter | EBD (*n*=18) | PTBD (*n*=58) | *p* |
|---|---|---|---|
| Major liver resection, *n* (%) | 18 (100.0) | 52 (89.7) | 0.326 |
| Resection of liver segment 1, *n* (%) | 9 (50.0) | 34 (58.6) | 0.591 |
| Extended right hemihepatectomy, *n* (%) | 2 (11.1) | 17 (29.3) | 0.210 |
| Formation of multiple hepaticojejunostomies, *n* (%) | 4 (22.2) | 21 (36.2) | 0.391 |
| Portal vein resection, *n* (%) | 4 (22.2) | 14 (24.1) | 1.0 |
| Pringle maneuver, *n* (%) | 4 (22.2) | 12 (20.7) | 1.0 |
| Operative duration, min | 300 [230; 340] | 305 [150; 615] | 0.601 |
| Blood loss, mL | 1500 [1200; 1300] | 1600 [750; 3000] | 0.965 |
| Blood transfusion, *n* (%) | 10 (55.6) | 34 (58.6) | 1.0 |
| Post-resection complications, *n* (%) | 18 (100.0) | 48 (82.8) | 0.105 |
| Biliary-enteric anastomotic leak, *n* (%) | 9 (50.0) | 21 (36.2) | 0.408 |
| Biliary-enteric anastomotic stricture, *n* (%) | 3 (16.7) | 4 (6.9) | 0.346 |
| Bile leak from liver resection margin, *n* (%)* | 6 (33.3) | 16 (27.6) | 0.767 |
| Gastrointestinal bleeding, *n* (%) | 3 (16.7) | 9 (15.5) | 1.0 |
| Cholangitis, *n* (%) | 7 (38.9) | 25 (43.1) | 0.413 |
| Operative site bleeding, *n* (%) | 2 (11.1) | 4 (6.9) | 0.623 |
| Pneumonia, *n* (%) | 4 (22.2) | 6 (10.3) | 0.235 |
| Deep vein thrombosis, *n* (%) | 2 (11.2)** | 5 (8.6) | 0.667 |
| PRLF in the overall group (*n*=76), *n* (%) | 5 (27.8) | 12 (20.7) | 0.531 |
| PRLF grade B/C in the overall group (*n*=76), *n* (%) | 1 (5.5) | 3 (5.2) | 1.0 |
| PRLF in the hemihepatectomy group (*n*=70), *n* (%) | 5 (27.8) | 12/52 (23.1) | 0.753 |
| PRLF grade B/C in the hemihepatectomy group (*n*=70), *n* (%) | 1 (5.5) | 3 (5.2) | 1.0 |
| Clavien—Dindo grade ⩾ III complications in the overall group (*n*=76), *n* (%) | 8 (44.4) | 23 (39.7) | 0.787 |
| Clavien—Dindo grade ⩾ III complications in the hemihepatectomy group (*n*=70), *n* (%) | 8 (44.4) | 23 (44.2) | 1.0 |
| Mortality in the overall group (*n*=76), *n* (%) | 3 (16.7) | 7 (12.1) | 0.721 |
| Mortality in the hemihepatectomy group (*n*=70), *n* (%) | 3 (16.7) | 7 (13.4) | 1.0 |
| Postoperative chemotherapy, *n* (%) | 8 (44.4) | 29 (50.0) | 0.790 |
| Post-resection photodynamic therapy, *n* (%) | 0 | 5 (8.6) | 0.331 |

*Note.* EBD — endoscopic biliary drainage; PTBD — percutaneous transhepatic biliary drainage; PRLF — post-resection liver failure. * — in 2 patients in the EBD group and 4 patients in the PTBD group, this occurred in combination with biliary-enteric anastomotic leak; ** — in one case, this was accompanied by the development of pulmonary embolism.

IV ductal involvement (22.2% vs. 37.9%), but the observed difference was not significant ($p$=0.266).

In both groups, patients with stage III disease according to AJCC criteria were the most frequent — 50.0% vs. 51.7% ($p$=1.0).

The incidence of first disease recurrence manifesting as peritoneal metastases, ovarian metastases, or implantation metastases along the drain tract was assessed — i.e., events that could be associated with contact of bile containing tumor cell complexes with surrounding tissues during external percutaneous transhepatic drainage. Observation showed that the incidence of peritoneal or ovarian metastases as the first identified recurrence was approximately 5% in both groups ($p$=1.0). It is noteworthy that in the EBD group, such progression developed in one (5.6%) patient, and this patient did not undergo PTBD to manage biliary drainage complications. Furthermore, in the EBD group, one (5.6%) patient developed an implantation metastasis. This patient also did not undergo PTBD to manage complications of the initial endoscopic biliary drainage; the site of implantation metastasis was the tract through which an intraoperative safety drain had been placed. In the PTBD group, implantation metastases developed in 3 (5.2%) patients, which was not statistically significantly different from the EBD group ($p$=1.0).

Long-term outcomes were assessed according to the method of initial drainage **(see figure)**. The median overall survival was 15 months in the EBD group versus 25 months in the percutaneous transhepatic drainage group, but the difference was not statistically significant ($p$=0.740; see **figure, a**).

Similarly, there were no statistically significant differences in recurrence-free survival between the groups: the median RFS was 11 months in the endoscopic drainage group and reached 14 months in the PTBD group ($p$=0.500; see **figure, b**).

***Table 3.*** **Morphological examination data, staging, location of the first relapse of the disease**

| Parameter | EBD (*n*=18) | PTBD (*n*=58) | *p* |
|---|---|---|---|
| R0 resection, *n* (%) | 14 (77.8) | 36 (62.1) | 0.266 |
| R1 resection, *n* (%) | 3 (16.7) | 17 (29.3) | 0.369 |
| R2 resection, *n* (%) | 1 (5.6) | 5 (8.6) | 1.0 |
| Intraductal papillary neoplasm with associated invasive carcinoma, *n* (%) | 0 | 2 (3.4) | 1.0 |
| Number of LNs retrieved | 8 [6; 11] | 7 [4; 11.5] | 0.473 |
| Well-differentiated adenocarcinoma, *n* (%) | 9 (50.0) | 21 (36.2) | 0.408 |
| Perineural invasion, *n* (%) | 10 (55.6) | 34 (58.6) | 1.0 |
| Macrovascular invasion, *n* (%) | 6 (33.3) | 23 (39.7) | 0.783 |
| Lymphovascular invasion, *n* (%) | 1 (5.6) | 6 (10.3) | 1.0 |
| Presence of involved LNs, *n* (%) | 9 (50.0) | 24 (41.4) | 0.591 |
| More than three involved LNs, *n* (%) | 0 | 7 (12.1) | 0.183 |
| Involved/retrieved LN ratio | 0.140 [0.066; 0.65] | 0.205 [0.141; 0.65] | 0.218 |
| Stage IV (Bismuth), *n* (%) | 4 (22.2) | 22 (37.9) | 0.266 |
| Stage I—II (AJCC, 8$^{th}$ edition), *n* (%) | 7 (38.9) | 19 (32.8) | 0.777 |
| Stage III, *n* (%) | 9 (50.0) | 30 (51.7) | 1.0 |
| Stage IVA, *n* (%) | 0 | 4 (6.9) | 0.567 |
| Stage IVB, *n* (%) | 2 (11.1) | 5 (8.6) | 0.667 |
| Postoperative chemotherapy, *n* (%) | 8 (44.4) | 29 (50.0) | 0.790 |
| Post-resection photodynamic therapy, *n* (%) | 0 | 5 (8.6) | 0.331 |
| Peritoneal or ovarian metastases, *n* (%) | 1 (5.6) | 3 (5.2) | 1.0 |
| Implantation metastasis, *n* (%) | 1 (5.6) | 3 (5.2) | 1.0 |

*Note.* EBD — endoscopic biliary drainage; PTBD — percutaneous transhepatic biliary drainage; LN — lymph node.

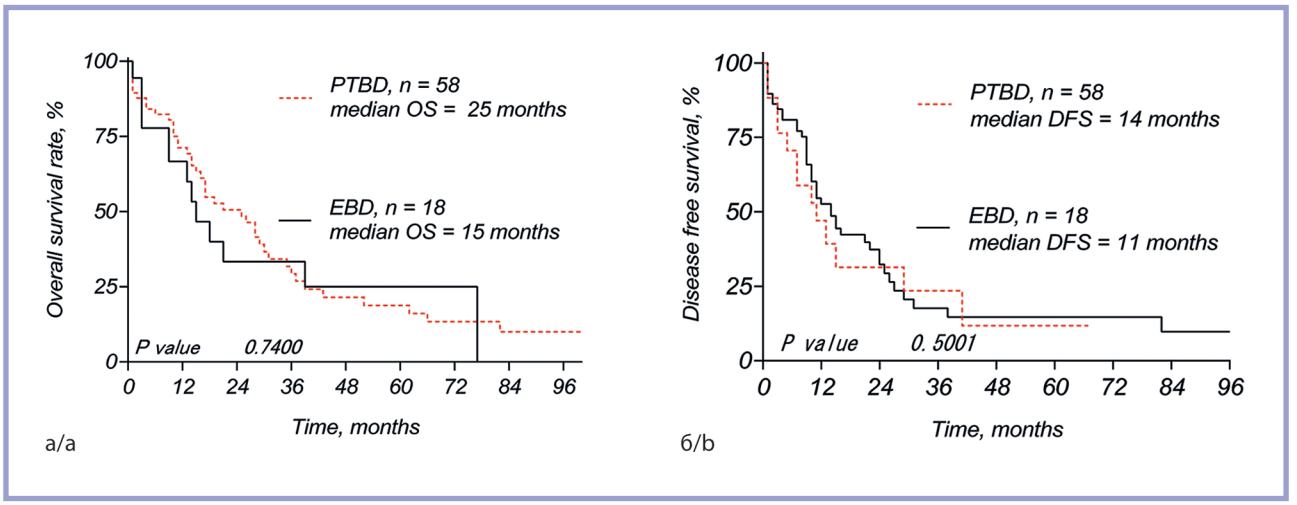


**Overall survival (a) and disease-free survival (b) depending on the initial drainage method performed — endoscopic biliary drainage (EBD) or percutaneous transhepatic biliary drainage (PTBD).**

## Discussion

Obstructive jaundice is the most common sign of extrahepatic CC. Cholangitis often ensues subsequently [1, 2]. Even in cancer limited to the ductal mucosa or the fibromuscular layer, this complication is observed in nearly 80% of patients [3]. According to our data on resectable PO, among 98 patients, only 10 (10.2%) did not have clinically significant obstructive jaundice or cholangitis—these patients did not undergo procedures aimed at biliary decompression.

One of the debated methods of preoperative preparation in patients with resectable CC is the choice of drainage method. Currently, performing endoscopic procedures is widely recommended [4—7].

European colleagues, regarding malignant biliary strictures, strongly advise against percutaneous manipu-

lations and the formation of biliary-enteric anastomoses due to the high risk of complications and reduced quality of life for patients. Moreover, even for resectable tumors, the authors recommend preferring self-expanding metal stents. For unresectable tumors, according to the cited colleagues, the option of a perforated covered or partially covered stent should be considered [6]. In a study by Chinese colleagues, patients who underwent EBD for obstructive jaundice due to CBD cancer also predominated ($n$=64 out of 71) [15]. In the absence of signs of cholangitis, with a not-too-high level of total bilirubin, and without the need for preoperative therapy in CBD cancer, performing pancreaticoduodenectomy without prior decompression is possible. L. Gorji et al. [5] suggest using a blood bilirubin level of less than 10 g/dL (171 μmol/L) as a threshold, but if biliary decompression is necessary, the authors also prefer the endoscopic method.

Most often, as evidence of the advantage of endoscopic drainage in jaundice caused by CC, reference is made to the work by R. Coelen et al. [8], as well as studies by colleagues from Japan [9, 10].

In the publication by R. Coelen et al. [8], it was noted that when attempting to conduct a prospective randomized trial on the impact of biliary decompression methods on treatment outcomes in patients with PO, an extremely high mortality rate was found in the PTBD group—11 (40.7%) out of 27 patients. Alarmingly, 3 patients died due to complications of the procedure itself. Another 8 patients died from post-resection complications. In the EBD group, mortality reached 11.1% (3 out of 27), all three patients in this cohort dying from post-resection complications. Due to the high incidence of fatal complications in the PTBD group, the study was terminated early, concluding that EBD is superior as preoperative biliary decompression for PO. Undoubtedly, the high incidence of fatal complications immediately after performing cholangiostomy—even before resection (11.1%)—is striking. Furthermore, this study noted a trend towards a lower incidence of post-procedural cholangitis after EBD (37% vs. 59%; $p$=0.1). At the same time, 56% of patients from the retrograde access group subsequently underwent percutaneous intervention due to inadequacy of EBD or its complications. Conversely, in the comparison group, conversion from percutaneous to endoscopic biliary drainage was performed in only one patient [8]. In the other two mentioned studies, better long-term outcomes were noted when performing EBD for extrahepatic CC complicated by obstructive jaundice [9, 10].

However, it is worth noting that in case of stent migration or occlusion, repeat endoscopic or percutaneous intervention is necessary, often under worse conditions—in the presence of cholangitis. In the study by K. Gyoten et al. [16], a similar situation occurred in 25% of patients with PO during preoperative therapy. Notably, the preoperative therapy was administered for a median of two courses. The Japanese colleagues successfully managed the complications in all cases [16]; however, according to Russian colleagues, PTBD compares favorably to EBD in terms of better reproducibility for both the primary procedure and any repeat intervention that might be required [17].

An important argument in the debate surrounding the generally accepted approach to managing obstructive jaundice in PO are the results of a meta-analysis published in 2022. The publication included 11 studies, including the aforementioned sole randomized trial. The article presents an analysis of the immediate outcomes of biliary decompression in 1417 patients with PO: 633 patients underwent PTBD (first group), and 784 patients underwent EBD (second group). In the first group, successful decompression of the biliary tree was achieved more frequently (risk ratio 3.5; 95% CI 2.05—5.97), while in the second group, the risk of developing cholangitis was higher (risk ratio 1.7; 95% CI 0.92—3.08). Furthermore, in the second group, the risk of repeat interventions due to complications of the primary procedure or its ineffectiveness was an order of magnitude higher (risk ratio 11.50; 95% CI 3.51—37.70). These results led the authors to conclude that PTBD is more advisable for proximal tumor obstruction of the biliary tree [12].

Analysis of the immediate outcomes of biliary drainage procedures obtained in the present study showed a statistically significant advantage of PTBD over EBD. Despite the comparable overall incidence of complications in the compared groups ($p$=0.434), grade III or higher complications developed significantly more often in the EBD group (50.0% vs. 22.4%; $p$=0.037). This group also more frequently required additional PTBD to manage developed complications or in case of ineffective biliary drainage (44.4% vs. 10.3%; $p$=0.003) compared to the PTBD group. There were no conversions to EBD in the PTBD group.

A study by Italian colleagues (2021) evaluated the surgical treatment outcomes of 639 patients with PO: 198 (31.0%) patients were operated on without drainage, and 441 (69.0%) patients underwent biliary decompression before resection. It is emphasized that the authors noted a predominance of PTBD in specialized centers and EBD in general hospitals. In 43.3% of patients, the first procedure led to complications; additional drainage was performed in 68 patients. a trend towards an increased incidence of complications after the procedure was noted in patients who underwent EBD (47.5% vs. 38.9; $p$=0.098), but the drainage method did not influence the postoperative course [11].

The results of the present study also showed no statistically significant impact of the preoperative drainage method on the course of the post-resection period. a trend towards an increased incidence of postoperative complications was noted in the group of patients with endoscopic interventions (100.0% vs. 82.8%; $p$=0.105), as well as a statistically non-significant association with an increased rate of biliary-enteric anastomotic leak (50.0% vs. 36.2; $p$=0.408) or stricture (16.7% vs. 6.9%; $p$=0.346).

No significant differences were found between the groups in the incidence of grade III or higher complications (44.4% in the EBD group vs. 39.7%; $p$=0.787)

or mortality (16.7% vs. 12.4%, respectively; $p$=0.721). Furthermore, no differences were found in the incidence of PRLF (27.8% in the EBD group vs. 20.7%; $p$=0.531).

Since isolated EHBD resections without major liver resections were only present in the PTBD group ($n$=6), an analysis of immediate resection outcomes was performed excluding the treatment results of these patients. In the more balanced groups, no differences were found in the incidence of Clavien—Dindo grade ⩾III complications ($p$=1.0), PRLF ($p$=0.753), or PRLF grade B/C ($p$=1.0). Mortality was comparable ($p$=1.0).

As mentioned earlier, there are data indicating worse long-term outcomes when PTBD is used in patients with extrahepatic CC complicated by obstructive jaundice [9, 10]. a study published in 2016 noted that when PTBD is performed as preoperative preparation in patients with resectable CBD cancer, the prognosis is worse than when choosing EBD. The five-year OS after pancreaticoduodenectomy was 34.2% in the PTBD group and 48.8% in the endoscopic drainage group ($p$=0.003). The authors attribute this to contact of bile containing tumor cells with the peritoneum. As evidence for this hypothesis, they point to a threefold increase in the incidence of peritoneal dissemination after pancreaticoduodenectomy (30.7% vs. 10.7%; $p$=0.006) specifically in the percutaneous access group [9]. In a study published a year later, a positive impact of EBD in resectable PO ($n$=320) was shown, with five-year OS reaching 44.3% in this group compared to 37% in the PTBD group ($p$=0.019). The authors also associate this with a higher incidence of peritoneal metastases, as well as the risk of implantation metastasis along the tract of the placed cholangiostomy drain. The incidence of implantation metastases in the cited study reached 3.6%. An imbalance in tumor extent between groups was noted; however, the reduction in OS in the PTBD group persisted after pseudo-randomization when comparing long-term outcomes in equivalent groups ($p$=0.018). It should be noted that RFS did not differ between the compared groups ($p$=0.413) [10].

At the same time, there are data showing no negative impact of percutaneous drainage on OS ($p$=0.26), nor on the incidence of peritoneal metastases in PO (3.4% for PTBD vs. 2.7% for EBD; $p$=0.71) [13].

Our results showed that the incidence of peritoneal or ovarian metastases as the first identified recurrence did not differ between the compared groups, amounting to approximately 5% for both PTBD and EBD ($p$=1.0). It is noteworthy that in the EBD group, such progression developed in one (5.6%) case; this patient did not undergo PTBD to manage complications, i.e., there was no conversion to a percutaneous procedure and no contact of bile with the peritoneum. In the EBD group, one (5.6%) patient developed an implantation metastasis in the soft tissues at the site of a drain placed during the resection phase, and this patient also did not undergo PTBD to manage EBD complications. In the PTBD group, implantation metastases were identified in 3 (5.2%) patients, but there was no difference compared to the EBD group ($p$=1.0).

Furthermore, no statistically significant differences were found in long-term outcomes between the compared groups. The median overall survival in the endoscopic drainage group was 15 months versus 25 months in the percutaneous manipulation group ($p$=0.740). No statistically significant differences were found in recurrence-free survival between the compared groups either: the median RFS was 11 months for EBD versus 14 months for the PTBD group ($p$=0.500).

Undoubtedly, the development of endoscopic technologies and their widespread introduction into clinical practice are yielding results. Certain successes are noted by domestic authors. In a study by Russian colleagues on unresectable PO, technical success in biliary decompression using EBD was achieved in all cases. However, the colleagues noted that, despite including only patients with unresectable tumors in the study, the extent of the biliary stricture corresponded to Bismuth stage I—II in 16 (64.0%) out of 25 patients. This indicates a certain selection of patients for EBD [18]. The Russian experience with using covered self-expanding metal stents with microscopic perforations in a group of patients with obstructive jaundice of various tumor etiologies, including CC, yielded positive results. The use of such stents reduced the risk of developing cholecystitis and pancreatitis compared to the use of partially or fully covered stents [19]. Nevertheless, despite the successes in applying EBD in patients with CC complicated by obstructive jaundice, PTBD should not be avoided, and in clinics with extensive positive experience using PTBD, this method should be preferred for resectable PO complicated by obstructive jaundice. This is confirmed in the Russian consensus document on the treatment of patients with obstructive jaundice [14] and is supported by the results of the present retrospective study.

## Conclusion

Thus, the obtained results demonstrated an advantage of percutaneous transhepatic biliary drainage over endoscopic biliary drainage in resectable perihilar tumors complicated by obstructive jaundice when comparing the immediate outcomes of preoperative drainage, as well as comparable immediate and long-term outcomes of the resection phase in the compared groups.

**Participation of authors:**
Concept and design of the study — Polyakov A.N., Virshke E.R.
Data collection and processing — Frantsev D.Yu., Sergeeva O.N., Kantieva D.M.
Text writing — Polyakov A.N., Egorov V.I.
Editing — Kotelnikov A.G., Podluzhny D.V.

**The authors declare that there is no conflict of interests.**

## REFERENCES


1. Zhou H, Liu C, Yu X, Su M, Yan J, Shi X. Efficacy and safety of endoscopic nasobiliary drainage versus percutaneous transhepatic cholangial drainage in the treatment of advanced hilar cholangiocarcinoma: a systematic review and meta-analysis. *BMC Gastroenterol.* 2024;24(1):302. https://doi.org/10.1186/s12876-024-03397-3
2. Pietrzak J, Przybyłkowski A. Endoscopic Treatment of Malignant Hilar Biliary Obstruction. *Cancers (Basel).* 2023;15(24):5819. https://doi.org/10.3390/cancers15245819
3. Miura F, Sano K, Amano H, Toyota N, Wada K, Tokairin T, Kondo F, Hayano K, Matsubara H, Takada T. Is it possible to define early distal cholangiocarcinoma? *Langenbecks Arch Surg.* 2016;401(1):25-32. https://doi.org/10.1007/s00423-015-1351-6
4. Nagino M, Hirano S, Yoshitomi H, et al. Clinical practice guidelines for the management of biliary tract cancers 2019: The 3rd English edition. *J Hepatobiliary Pancreat Sci.* 2021;28(1):26-54. https://doi.org/10.1002/jhbp.870
5. Gorji L, Beal EW. Surgical Treatment of Distal Cholangiocarcinoma. *Curr Oncol.* 2022;29(9):6674-6687. https://doi.org/10.3390/curroncol29090524
6. Del Vecchio Blanco G, Mossa M, Troncone E, et al. Tips and tricks for the diagnosis and management of biliary stenosis-state of the art review. *World J Gastrointest Endosc.* 2021;13(10):473-490. https://doi.org/10.4253/wjge.v13.i10.473
7. Lamarca A, Edeline J, Goyal L. How I treat biliary tract cancer. *ESMO Open.* 2022;7(1):100378. https://doi.org/10.1016/j.esmoop.2021.100378
8. Coelen RJS, Roos E, Wiggers JK, et al. Endoscopic versus percutaneous biliary drainage in patients with resectable perihilar cholangiocarcinoma: a multicentre, randomised controlled trial. *Lancet Gastroenterol Hepatol.* 2018;3(10):681-690. https://doi.org/10.1016/S2468-1253(18)30234-6
9. Komaya K, Ebata T, Fukami Y, et al. Percutaneous biliary drainage is oncologically inferior to endoscopic drainage: a propensity score matching analysis in resectable distal cholangiocarcinoma. *J Gastroenterol.* 2016;51(6):608-619. https://doi.org/10.1007/s00535-015-1140-6
10. Komaya K, Ebata T, Yokoyama Y, et al. Verification of the oncologic inferiority of percutaneous biliary drainage to endoscopic drainage: A propensity score matching analysis of resectable perihilar cholangiocarcinoma. *Surgery.* 2017;161(2):394-404. https://doi.org/10.1016/j.surg.2016.08.008
11. Giuliante F, Ardito F, Aldrighetti L, et al. Liver resection for perihilar cholangiocarcinoma: Impact of biliary drainage failure on postoperative outcome. Results of an Italian multicenter study. *Surgery.* 2021;170(2):383-389. https://doi.org/10.1016/j.surg.2021.01.021
12. Van Eecke E, Degroote H, Vanlander A, Hindryckx P. Outcome of primary ERCP versus primary PTC for biliary drainage in malignant hilar biliary strictures: a systematic review and meta-analysis. *Surg Endosc.* 2022;36(10):7160-7170. https://doi.org/10.1007/s00464-022-09413-5
13. Wiggers JK, Groot Koerkamp B, Coelen RJ, et al. Percutaneous Preoperative Biliary Drainage for Resectable Perihilar Cholangiocarcinoma: No Association with Survival and No Increase in Seeding Metastases. *Ann Surg Oncol.* 2015;22 Suppl 3:S1156-S1163. https://doi.org/10.1245/s10434-015-4676-z
14. Хатьков И.Е., Аванесян Р.Г., Ахаладзе Г.Г. и др. Российский консенсус по актуальным вопросам диагностики и лечения синдрома механической желтухи. *Хирургия. Журнал им. Н.И. Пирогова.* 2020;(6):5-17.
Khat'kov IE, Avanesyan RG, Akhaladze GG, et al. Russian consensus on current issues in the diagnosis and treatment of obstructive jaundice syndrome. *Pirogov Russian Journal of Surgery.* 2020;(6):5-17. (In Russ.). https://doi.org/10.17116/hirurgia20200615
15. Chen Z, Yu B, Bai J, et al. The Impact of Intraoperative Frozen Section on Resection Margin Status and Survival of Patients Underwent Pancreatoduodenectomy for Distal Cholangiocarcinoma. *Front Oncol.* 2021;11:650585. https://doi.org/10.3389/fonc.2021.650585
16. Gyoten K, Kuriyama N, Maeda K, et al. Safety and efficacy of neoadjuvant chemotherapy based on our resectability criteria for locally advanced perihilar cholangiocarcinoma. *Langenbecks Arch Surg.* 2023;408(1):261. https://doi.org/10.1007/s00423-023-03000-5
17. Францев Д.Ю., Сергеева О.Н., Долгушин Б.И. Лечение гилюсной холангиокарциномы. Современное состояние вопроса. *Сибирский онкологический журнал.* 2019;18(1):103-115.
Frantsev DYu, Sergeeva ON, Dolgushin BI. Therapy for hilar cholangiocarcinoma. *Siberian Journal of Oncology.* 2019;18(1):103-115. (In Russ.). https://doi.org/10.21294/1814-4861-2019-18-1-103-115
18. Качмазова А.В., Тетерин Ю.С., Тигиев Л.Р., Ярцев П.А., Рогаль М.Л., Байрамов Р.Ш. Эндоскопическое лечение пациентов с механической желтухой при опухоли Клацкина. *Хирургия. Журнал им. Н.И. Пирогова.* 2023;4:55-60.
Kachmazova AV, Teterin YuS, Tigiyev LR, Yartsev PA, Rogal ML, Bayramov RSh. Endoscopic treatment of obstructive jaundice in patients with Klatskin tumor. *Pirogov Russian Journal of Surgery.* 2023;4:55-60. (In Russ., In Engl.) https://doi.org/10.17116/hirurgia202304155
19. Куликов Ю.Д., Тетерин Ю.С., Миронова А.С., Ярцев П.А., Рохас Тадевосян Т.Э., Нугуманова К.А. Эндоскопическое стентирование при опухолевых стриктурах панкреатобилиарной зоны. *Хирургия. Журнал им. Н.И. Пирогова.* 2024;(1):29-33.
Kulikov YuD, Teterin YuS, Mironova AS, Yartsev PA, Rohas Tadevosyan TE, Nugumanova KA. Endoscopic stenting for malignant pancreatobiliary strictures. *Pirogov Russian Journal of Surgery.* 2024;(1):29-33. (In Russ., In Engl.) https://doi.org/10.17116/hirurgia202401129


Received 17.03.2025
Accepted 19.03.2025