Хирургия. Журнал имени Н.И. Пирогова
2026, №1, с. 116–120
https://doi.org/10.17116/hirurgia2026011116

Pirogov Russian Journal of Surgery
2026, No. 1, pp. 116–120
https://doi.org/10.17116/hirurgia2026011116

Киста печени, осложненная свищом в брюшную стенку

© MAHER FAHD HEJAZEE, FADI BASSAM ALMAHAMEED, ASHRAF ALAKKAD

Больница Мадинат Заид, Аль-Дхафра, ОАЭ

Резюме

Доброкачественные, заполненные жидкостью образования, называемые простыми кистами печени, часто обнаруживаются случайно. Хотя кисты обычно протекают бессимптомно, они могут вызывать осложнения, включая инфекцию, разрыв или кровотечение. Формирование свища в брюшную стенку — редкое осложнение, представляющее диагностические и терапевтические трудности. В апреле 2024 г. 29-летний мужчина с ожирением (индекс массы тела 30,56 кг/м^2) обратился в больницу Мадинат Заид с левосторонней пневмонией, которая была купирована внутривенным введением антибиотиков. Последующая КТ выявила гиподенсное образование размером 11×10×5 см в правой доле печени с частичной краевой кальцификацией без значимого контрастного усиления. Дифференциальный диагноз включал эхинококковую кисту и билиарную опухоль. Лабораторные результаты показали нормальные уровни маркеров гепатита и опухолевых маркеров, за исключением повышенного уровня CA19-9. Лапароскопическая ревизия выявила кисту размером 15×15 см, спаянную с печенью и брюшной стенкой, содержащую 400 мл желчи. Гистопатологическое исследование подтвердило доброкачественность билиарной кисты. Пациентка хорошо восстановилась после операции, рецидивов или осложнений при последующем наблюдении не наблюдалось. Это редкий случай простой кисты печени, осложненной свищом в брюшную стенку. Успешный исход был достигнут благодаря мультидисциплинарному подходу, включавшему визуализацию, лабораторные исследования и хирургическое вмешательство. Для обеспечения оптимального ухода за пациентом важно учитывать редкие осложнения, возникающие при лечении кисты печени.

Ключевые слова: *простая киста печени, желчная киста, свищ брюшной стенки, лапароскопия, CA19-9, доброкачественное кистозное образование.*

Автор, ответственный за переписку: Ashraf Goma ALakkad — e-mail: ashraf.alaqqad@gmail.com

Как цитировать:
Maher Fahd Hejazee, Fadi Bassam Almahameed, Ashraf ALakkad. Киста печени, осложненная свищом в брюшную стенку. *Хирургия. Журнал им. Н.И. Пирогова*. 2026;1:116–120. (In Engl.). https://doi.org/10.17116/hirurgia2026011116

Simple liver cyst complicated by fistula into abdominal wall: a case report

© MAHER FAHD HEJAZEE, FADI BASSAM ALMAHAMEED, ASHRAF ALAKKAD

Madinat Zayed Hospital, AL Dhafra Region, UAE

Abstract

Benign, fluid-filled lesions called simple liver cysts are commonly seen incidentally on imaging. While they are usually asymptomatic, they can cause complications including infection, rupture, or hemorrhage. The formation of a fistula into the abdominal wall is a rare complication, with diagnostic and therapeutic challenges.

Case Presentation: In April 2024, a 29-year-old obese (body mass index 30.56) male presented to Madinat Zayed Hospital with left pneumonia, which was resolved with intravenous antibiotics. A subsequent CT scan, however, showed an 11×10×5 cm hypodense lesion in the right hepatic lobe, with partial marginal calcification but no significant contrast enhancement. Differential diagnoses included hydatid cyst and biliary neoplasm. The findings in the laboratory were normal hepatitis markers and tumor markers except for elevated CA19-9 levels. Laparoscopic deroofing of the cyst revealed a 15×15 cm cyst adherent to the liver and abdominal wall containing 400 ml of bile. There was histopathological confirmation of a benign biliary cyst. The patient recovered well postoperatively and did not have recurrence or complications on follow-up.

Conclusion: This is a rare case of a simple liver cyst complicated by a fistula into the abdominal wall. Successful outcome resulted from multidisciplinary management using imaging, laboratory investigations, and surgical intervention. It is important to consider rare complications of liver cyst management to provide optimal patient care and this report highlights the importance of this.

Keywords: *Simple liver cyst, biliary cyst, abdominal wall fistula, laparoscopic deroofing, CA19-9, benign cystic lesion.*

Corresponding author: Ashraf Goma ALakkad — e-mail: ashraf.alaqqad@gmail.com

To cite this article:
Maher Fahd Hejazee, Fadi Bassam Almahameed, Ashraf ALakkad. Simple liver cyst complicated by fistula into abdominal wall: a case report. *Pirogov Russian Journal of Surgery*. 2026;1:116–120. (In Engl.). https://doi.org/10.17116/hirurgia2026011116

Introduction

Liver cysts can be found as alone, numerous, or disperse, especially in cases of polycystic liver disease [1]. Simple cysts are found in about 5 to 10 percent of people, and their occurrence increases significantly as people get older. Polycystic liver disorder is a genetic condition with an autosomal dominant pattern [2, 3]. Mutations in PRKCSH and SEC63 encoding β subunit of glucosidase II and Sec63, respectively, trigger it [4]. Both proteins play a role in the molecular machinery that helps with the translocation, folding, and quality control of newly synthesized glycoproteins in the endoplasmic reticulum [5]. Neoplastic cysts, including benign biliary cystadenocarcinomas and biliary cystadenomas, are acquired, but the exact cause remains unknown [5]. Traumatic cysts are formed when there is bile leakage from a damaged intrahepatic bile duct following an injury [6].

Most liver cysts don't show any symptoms. Sometimes they can be detected as a mass during a physical exam [6]. Most of them are discovered incidentally during abdominal imaging, particularly with ultrasound [6]. Approximately five percent of patients show symptoms and report vague issues like pain, nausea, feeling full quickly, vomiting, or heartburn [6]. After identifying a cyst, it's important to differentiate a simple cyst from other types of cystic lesions in the liver, such as cystic neoplasms and hydatid cysts. Some complications of liver cysts that have been reported include torsion, biliary fistula, obstructive jaundice, intracystic hemorrhage, rupture, infection, malignancy, portal vein occlusion, portal hypertension, varices, and Budd-Chiari Syndrome [7—9].

A rare but noteworthy complication is the formation of a fistula between a liver cyst and the abdominal wall [10]. This abnormal complication can result from infection or trauma to the cyst, leading to erosion and fistulous tract development [11]. Such a fistula is not only a complication of the clinical picture, but it also presents a diagnostic and therapeutic problem [11]. Optimizing patient outcomes requires an understanding of the pathophysiology, presentation, and management of this unusual complication [12].

This report describes the clinical and pathological aspects of a simple liver cyst complicated by a fistula into the abdominal wall, discussing its diagnostic and treatment dilemmas according to the existing literature.

Case presentation

A 29-year-old male presented to Madinat Zayed Hospital in April 2024 with left pneumonia, which was treated successfully with intravenous antibiotics. The patient was obese, with a BMI of 30.56, and has a past medical history of appendectomy performed 10 years ago. A CT scan of the chest, abdomen and pelvis performed on April 19, 2024, revealed patchy consolidation with air bronchograms and bronchiectasis in the medial basal segment of the left lower lung lobe, accompanied by ground-glass opacities in a tree-in-bud pattern across the remaining segments of the left lower lung lobe, suggesting an infective etiology.

Additionally, the scan identified an 11×10×5 cm well-delineated hypodense lesion, inseparable from the lateral aspect of the right hepatic lobe. The lesion showed partial marginal calcification with no significant contrast enhancement and no signs of infiltration into the liver or adjacent structures. Differential diagnoses included a partially calcified hydatid cyst and neoplastic lesions like biliary cystadenoma, necessitating further evaluation and histopathological correlation.

Laboratory investigations revealed a negative hepatitis screen, AFP of 1.2 IU/ml (normal), CEA of 1.32 mcg/L (normal), CA19-9 of 51.7 units/ml (elevated), and echinococcosis antibodies<1:160 (normal). Based on the clinical and radiological findings, laparoscopic deroofing of the liver cyst was performed on May 17, 2024. Operative findings indicated that the right lobe of the liver was adhered to the abdominal wall. A cyst, measuring approximately 15×15 cm, was identified and attached to the liver. Aspiration yielded 400 ml of pure bile. The cyst was opened, and part of its wall was excised and sent for histopathology. A small opening measuring about 0.5 cm was observed on the liver surface at the point of attachment, surrounded by hard fibrosis. Minimal bile leakage was noted, which was managed with TachoSil gauze and Gluetac application to seal the opening. A 14 Fr drain was placed in the cyst.

Post-operatively, the patient recovered well. The abdominal drain was removed on postoperative day three, and the patient was discharged in good condition. During follow-up on day 11, the patient was seen in the outpatient clinic, reported doing well, and had his sutures removed. The histopathological examination of the cyst wall confirmed a benign cystic lesion with a single layer

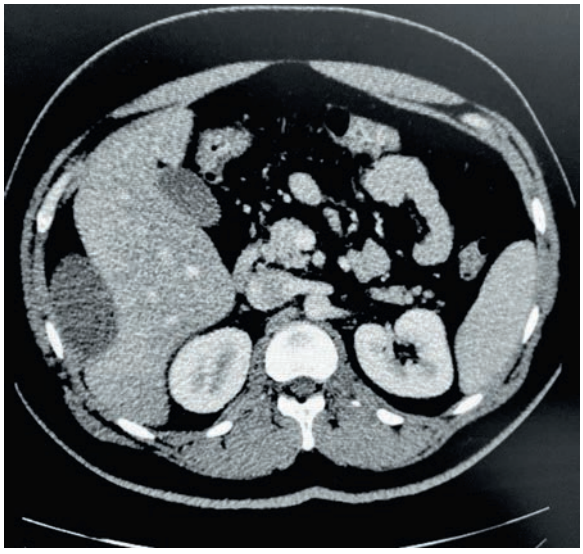

Fig. 1. **Abdominal CT scan showing 11×10×5 cm liver cyst in right lobe.**

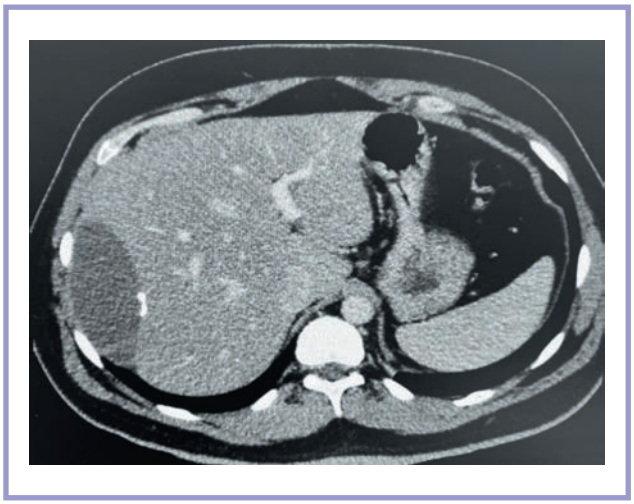

Fig. 2. **Abdominal CT scan showing liver cyst in right lobe with calcification.**

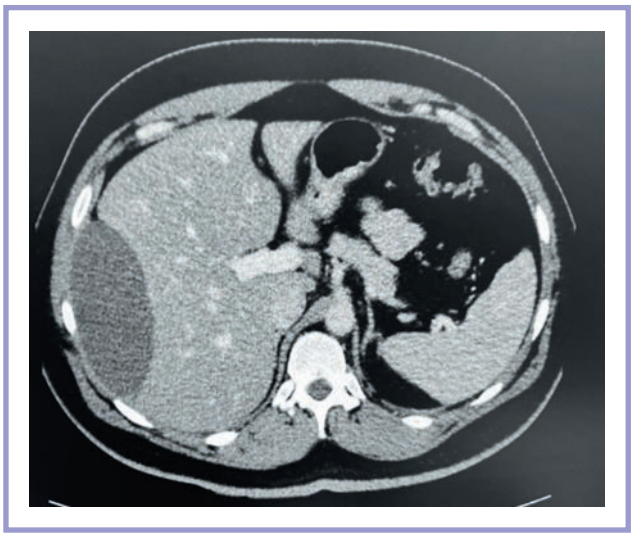

Fig. 3. **Abdominal CT scan showing 11×10×5 cm liver cyst in right lobe.**

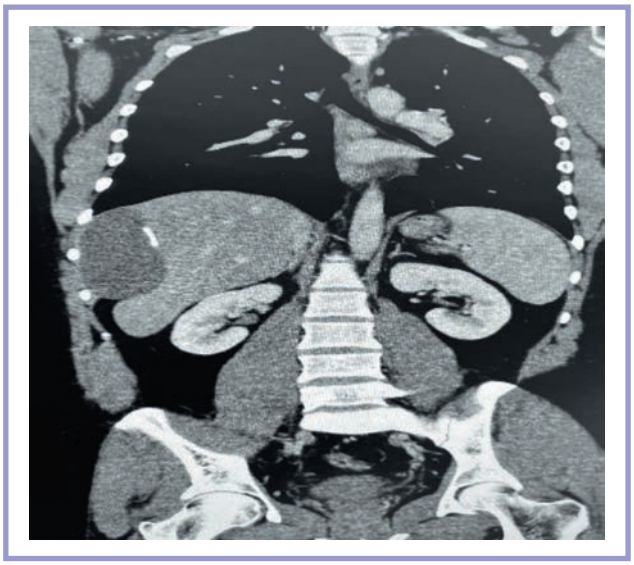

Fig. 4. **CT scan coronal view of liver cyst in right lobe.**

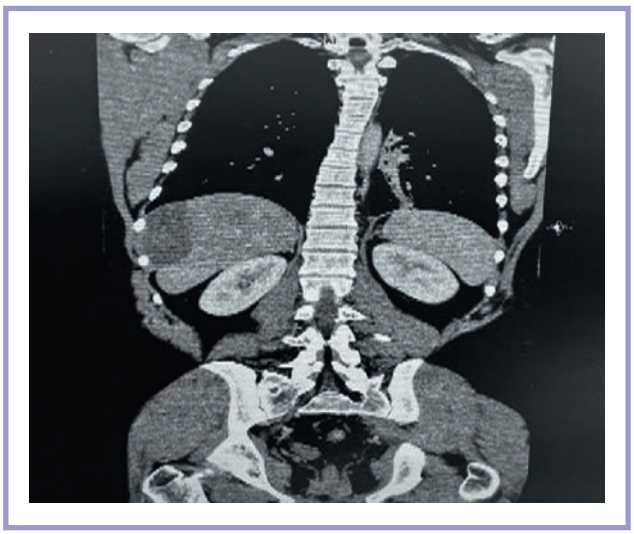

Fig. 5. **CT scan coronal view of liver cyst in right lobe.**

of columnar epithelium, fibrous wall, chronic inflammation, and hemorrhage. No ovarian-type stroma, dysplasia, or malignancy was identified. The lining cells were positive for CK19 and CK7 and negative for Calretinin and WT-1, favoring the diagnosis of a simple biliary cyst.

Discussion

This case report presents a case of a 29-year-old male who was admitted with acute left-sided pneumonia for which he received intravenous antibiotics. Further imaging demonstrated an approximately 11×10×5 cm sized, predominantly hypodense mass in the right hepatic lobe with only a small area of marginal calcification and minimal contrast enhancement. Serum CA19-9 levels were raised, whereas other tumor markers were not significantly increased. Laparoscopic deroofing of the cyst revealed a 15×15 cm cyst in close contact with the liver and the abdominal wall filled with bile, measuring 400 ml. A histopathological examination of the lesion established the diagnosis of benign biliary cyst. The patient had an uncomplicated postoperative course and was well on follow-up.

Simple hepatic cysts are usually non-cancerous and do not cause symptoms; the patient may be diagnosed accidentally during other imaging tests [6]. However, the complications include infection, rupture, hemorrhage, or compression of other structures in the surrounding area [11]. The formation of a fistula between the hepatic cyst and the abdominal wall is rather a rare occurrence. The majority of hepato-cutaneous fistulas have been described in association with hydatid disease or pyogenic liver abscesses [13]. For exam-

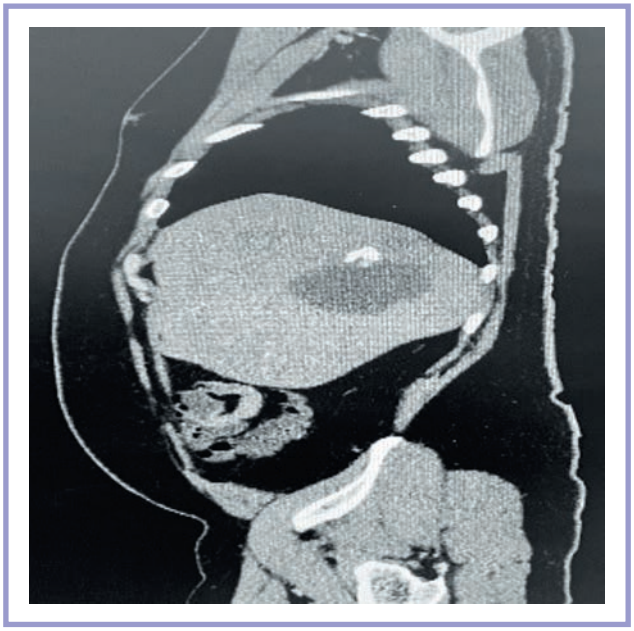

Fig. 6. **CT scan sagittal view of liver cyst in right lobe.**

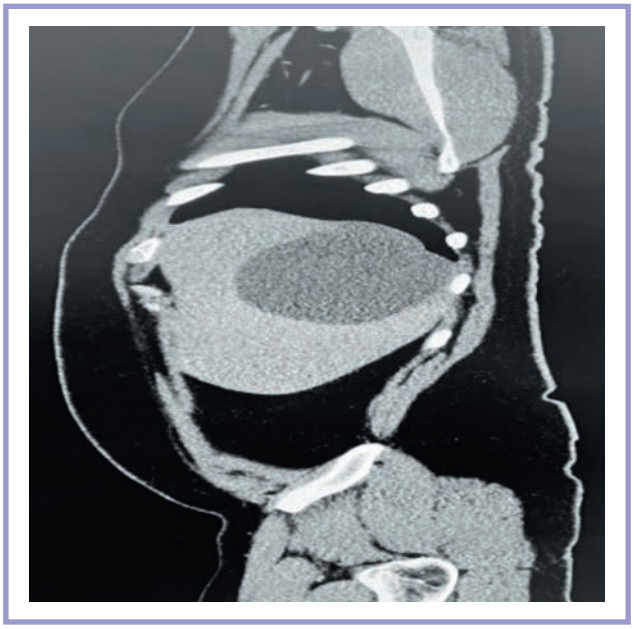

Fig. 7. **CT scan sagittal view of liver cyst in right lobe.**

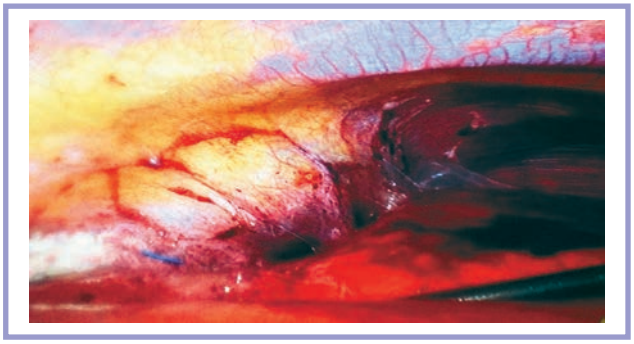

Fig. 8. **Abdominal wall bulge (cyst) attached to right hepatic lobe, aspiration done and 400 ml bile was drained.**



Fig. 9. **Abdominal wall bulge (cyst) attached to right hepatic lobe, aspiration done and 400 ml bile was drained.**

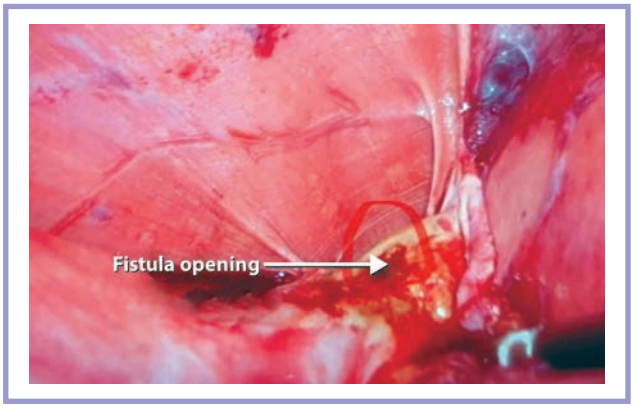

Fig. 10. **After De-roofing of cyst, the fistula opening at right hepatic lobe.**

ple, a case report documented a hepato-cutaneous fistula due to an E. coli-induced pyogenic liver abscess treated with antibiotics and saline lavage only [14]. On the other hand, our case was a simple biliary cyst with fistulous communication to the abdominal wall, a presentation rarely reported in the literature. Bile within the cyst and adhesion of the cyst to the abdominal wall indicate that the cyst communicates with the bile duct and the outside areas [15]. This condition required surgical management and laparoscopic deroofing to excise the cyst and treat the fistulous complication.

Abdominal computed tomography, ultrasonography (U/S), magnetic resonance cholangiopancreatography, and endoscopic retrograde cholangiopancreatography are really helpful for diagnosing the abdominal fistulas and cystic situation [16]. The primary diagnostic tools that we usually go for are CT scans and ultra-

sounds, which can be used in any situation [6]. ERCP is one of the more invasive tools that can give clear detection and treatment options, such as sphincterotomy for patients with intrabiliary cyst ruptures. Meanwhile, MRCP is used to determine where the obstruction of the biliary system is located(17, 18). In our case report, findings of the CT scan identified an 11×10×5 cm well-delineated hypodense lesion, inseparable from the lateral aspect of the right hepatic lobe. The lesion showed partial marginal calcification with no significant contrast enhancement and no signs of infiltration into the liver or adjacent structures.

Patients with hepatic cysts have been reported to have raised serum CA19-9 level, both benign and malignant [19]. In our case, the elevated CA19-9 level had returned to normal postoperatively, as reported by other authors. For instance, a case report described a ruptured large hepatic cyst with increased serum CA19-9 concentrations that reduced following laparoscopic fenestration [10]. This implies that the elevated CA19-9 levels in benign hepatic cysts may be due to irritation or inflammation of the cyst wall and not neoplastic transformation.

Conclusion

Indeed, this case demonstrates that, although simple hepatic cysts are benign lesions, it is necessary to consider less frequent but serious complications, including abdominal wall fistulas. It also underscores the need for detailed diagnostic work-up and radiologic and laboratory investigations to enable the correct management plans. Laparoscopic deroofing was successful in the treatment, therefore the patient had a good outcome.

The authors declare no conflicts of interest.

ЛИТЕРАТУРА/REFERENCES

1. Front Matter. Cochrane Handbook for Systematic Reviews of Interventions. 2008. p. i-xxi.
2. Hoevenaren IA, Wester R, Schrier RW, McFann K, Doctor RB, Drenth JP, et al. Polycystic liver: clinical characteristics of patients with isolated polycystic liver disease compared with patients with polycystic liver and autosomal dominant polycystic kidney disease. *Liver Int*. 2008;28(2):264-70. https://doi.org/10.1111/j.1478-3231.2007.01595.x
3. Gall TM, Oniscu GC, Madhavan K, Parks RW, Garden OJJH. Surgical management and long-term follow-up of non-parasitic hepatic cysts. *HPB (Oxford)*. 2009;11(3):235-241. https://doi.org/10.1111/j.1477-2574.2009.00042.x
4. Drenth JP, te Morsche RH, Smink R, Bonifacino JS, Jansen JBJNg. Germline mutations in PRKCSH are associated with autosomal dominant polycystic liver disease. *Nat Genet*. 2003;33(3):345-347. https://doi.org/10.1038/ng1104
5. Drenth JP, Martina JA, Van De Kerkhof R, Bonifacino JS, Jansen JBJTimm. Polycystic liver disease is a disorder of cotranslational protein processing. *Trends Mol Med*. 2005;11(1):37-42. https://doi.org/10.1016/j.molmed.2004.11.004
6. Macutkiewicz C, Plastow R, Chrispijn M, Filobbos R, Ammori BA, Sherlock DJ, et al. Complications arise in simple and polycystic liver cysts. *World journal of hepatology*. 2012;4(12):406-411. https://doi.org/10.4254/wjh.v4.i12.406
7. Ratcliffe P, Reeders S, Theaker JJBMJ. Bleeding oesophageal varices and hepatic dysfunction in adult polycystic kidney disease. *Br Med J (Clin Res Ed)*. 1984;288(6427):1330-1331. https://doi.org/10.1136/bmj.288.6427.1330
8. Ribeiro Junior MAF, Molla Neto OLd, Gonçalves A, Saad WA, Chaib EJE. Portal hypertension due to a non-parasitic hepatic cyst. 2003;1:110-112.
9. Van Keimpema L, Nevens F, Vanslembrouck R, Van Oijen MG, Hoffmann AL, Dekker HM, et al. Lanreotide reduces the volume of polycystic liver: a randomized, double-blind, placebo-controlled trial. *Gastroenterology*. 2009;137(5):1661-1668. e2. https://doi.org/10.1053/j.gastro.2009.07.052
10. Mizukami R, Nakazawa A, Einama T, Kariya R, Ohara M, Ichio K, et al. Ruptured large hepatic cyst with elevated serum and ascites CA19-9 level. *Journal of Surgical Case Reports*. 2024;2024(8). https://doi.org/10.1093/jscr/rjae309
11. Isogai H, Inoue M, Miura M. Hepatic cyst infection complicated by a hepatobronchial fistula diagnosed with unique features. *Oxford Medical Case Reports*. 2021;2021(10). https://doi.org/10.1093/omcr/omab105
12. Aghajanzadeh M, Ashoobi MT, Hemmati H, Samidoust P, Delshad MSE, Pourahmadi Y. Intrabiliary and abdominal rupture of hepatic hydatid cyst leading to biliary obstruction, cholangitis, pancreatitis, peritonitis and septicemia: a case report. *Journal of medical case reports*. 2021;15(1):311. https://doi.org/10.1186/s13256-021-02822-5
13. Athavale VS, Athavale PV, Agrawal RJJoPNR. A Case Of Hepato-Gastro Cutaneous Fistula. *Journal of Pharmaceutical Negative Results*. 2022:10284-10288. https://doi.org/10.47750/pnr.2022.13.S09.1205
14. Lawrence P. Pyoderma gangrenosum: the Groote Schuur Hospital experience, 1970-1990 1991.
15. Rizki-Safitri A, Shinohara M, Miura Y, Danoy M, Tanaka M, Miyajima A, et al. Efficient functional cyst formation of biliary epithelial cells using microwells for potential bile duct organization in vitro. *Sci Rep*. 2018;8(1):11086. https://doi.org/10.1038/s41598-018-29464-w
16. Aghajanzadeh M, Asgary M, Foumani AA, Alavi S, Rimaz S, Banihashemi ZJIJLS. Surgical management of pleural complications of lung and liver hydatid cysts in 34 patients. *International Journal of Life Sciences*. 2014;8(4):15-19. https://doi.org/10.3126/ijls.v8i4.10893
17. Sıkar HE, Kaptanoğlu L, Kement MJUTACD. An unusual appearance of complicated hydatid cyst: necrotizing pancreatitis. *Ulus Travma Acil Cerrahi Derg*. 2017;23(1):81-3. https://doi.org/10.5505/tjtes.2016.26820
18. Ufuk F, Duran MJTJoem. Intrabiliary rupture of hepatic hydatid cyst leads to biliary obstruction, cholangitis, and septicemia. 2018;54(1):e15-e7.
19. Chogahara I, Oshita A, Nakahara H, Itamoto TJSCR. Spontaneous rupture of hemorrhagic hepatic cyst: two case reports. *Surg Case Rep*. 2022;8(1):30. https://doi.org/10.1186/s40792-022-01382-0

Поступила/Received 15.01.2025
Принята к печати/Accepted 12.03.2025