Pirogov Journal of Surgery
2022, No. 4, pp. 34-41
https://doi.org/10.17116/hirurgia202204134

Results of total mesorectal excision and transanal endoscopic microsurgery for rectal adenocarcinoma with submucosal invasion

S.V. CHERNYSHOV[1], M.A. NAGUDOV[1], E.A. KHOMYAKOV[1, 2], S.B. KOZYREVA[2], O.A. MAYNOVSKAYA[1], E.G. RYBAKOV[1]

[1]Ryzhikh National Medical Research Center for Coloproctology, Moscow, Russia;
[2]Russian Medical Academy for Continuous Professional Education, Moscow, Russia

ABSTRACT

Objective. To analyze early and long-term outcomes after total mesorectal excision (TME) and transanal endoscopic microsurgery (TEM) in patients with T1 rectal cancer.

Material and methods. A retrospective non-randomized comparative study included 2 groups of patients: group 1 — total mesorectal excision, group 2 — transanal endoscopic microsurgery. In the second group, total mesorectal excision was proposed for patients with tumor invasion depth pT1sm3 and/or lymphovascular invasion and/or low differentiation. If total mesorectal excision was performed as a salvage surgery, the patient was excluded from further analysis.

Results. There were 156 patients with rectal adenocarcinoma pT1 between October 2011 and August 2019 (102 cases — TEM, 54 cases — TME). We excluded 10 patients from the TEM group due to salvage surgery. Duration of TEM was 40.0 (34; 50) min, TME — 139 (120; 180) min (p=0.00001). Postoperative hospital-stay was also significantly less in the TEM group (7 (6; 9) vs. 10 (7; 11) days, p=0.00001). Six (6.5%) patients in the TEM group and 1 (1.8%) patient in the TME group developed a local recurrence in pelvic cavity (p=0.1). There were no distant metastases. Disease-free 3-year survival was 92% after TEM and 96% after TME (p=0.058).

Conclusion. Transanal endoscopic microsurgery is a relatively safe alternative to total mesorectal excision for early rectal cancer.

Keywords: *colorectal cancer, early rectal cancer, transanal endoscopic microsurgery, total mesorectal excision, TEM, TME.*

INFORMATION ABOUT THE AUTHORS:
Chernyshov S.V. — https://orcid.org/0000-0002-6212-9454
Nagudov M.A. — https://orcid.org/0000-0002-0735-2100
Khomyakov E.A. — https://orcid.org/0000-0002-3399-0608
Kozyreva S.B. — https://orcid.org/0000-0003-1827-1872
Maynovskaya O.A. — https://orcid.org/0000-0001-8189-3071
Rybakov E.G. — https://orcid.org/0000-0002-3919-9067
Corresponding author: Nagudov M.A. — e-mail: nagudov-marat@yandex.ru

TO CITE THIS ARTICLE:
Chernyshov SV, Nagudov MA, Khomyakov EA, Kozyreva SB, Maynovskaya OA, Rybakov EG. Results of total mesorectal excision and transanal endoscopic microsurgery for rectal adenocarcinoma with submucosal invasion. *Pirogov Russian Journal of Surgery = Khirurgiya. Zhurnal im. N.I. Pirogova*. 2022;4:34–41. (In Russ.). https://doi.org/10.17116/hirurgia202204134

Introduction

Total mesorectal excision (TME) is a standard treatment for rectal cancer. This procedure ensures local recurrence rate < 6% and increases recurrence-free survival by more than 2 times compared to other surgical techniques [1]. Despite the obvious efficacy regarding freedom from cancer, TME is associated with perioperative mortality up to 1-2% and postoperative morbidity up to 30% [2, 3]. The majority of surgeons form preventive stoma after TME that implies the second surgical stage in the future. However, the most unfavorable outcome of "sphincter-sparing" surgery is functional disorders with low anterior resection syndrome (LARS) [4]. These disturbances can negate the efforts of surgeon and the patient's desire to avoid a permanent stoma and maintain normal defecation.

Development of imaging in medicine, first of all, endorectal ultrasound (ERUS), and magnetic resonance imaging (MRI) revolutionized preoperative tumor staging. Currently, physicians are able to identify the so-called early cancer uT1N0/mrT1N0 and perform local excision [5, 6].

Transanal endoscopic microsurgery (TEM) is the most standardized method of local excision of rectal tumors. This technique ensures precise resection of tumor and intestinal wall within intact tissues [7–9]. There are few randomized trials of radical interventions and TEM. Moreover, local excision is often accompanied by neo- or adjuvant chemo- and radiotherapy. In our opinion, this fact impairs between-group comparability and complicates assessment of the role of surgery and radiotherapy to treatment outcomes. We found no similar studies in Russian-language literature. This manuscript is devoted to a ret-

rospective comparison of early and long-term results after total mesorectal excision and transanal endoscopic microsurgery in patients with T1 rectal cancer.

Material and methods

A retrospective non-randomized trial included patients who underwent surgical treatment at the operated on at the Ryzhikh National Medical Research Centre for Coloproctology.

Inclusion criterion was rectal cancer with submucosal invasion confirmed by intraoperative morphological examination (pT1). We excluded patients with multiple malignancies and distant metastases.

There were 2 groups of patients: group 1 — total mesorectal excision, group 2 — transanal endoscopic microsurgery.

Excised specimens were analyzed according to standard technique with assessment of lateral and distal resection margins, T1 tumor invasion depth in accordance with the Kikuchi grading system, lymphovascular invasion and tumor differentiation. In case of TME, we also analyzed the state of regional lymph nodes. The final stage of cancer was established according to the TNM classification (the 8th edition, 2016).

In the second group, total mesorectal excision was proposed for patients with tumor invasion depth pT1sm3 and / or lymphovascular invasion and / or low differentiation. If total mesorectal excision was performed as a "salvage" surgery, the patient was excluded from further analysis.

Postoperative follow-up examination included CT of the chest, abdomen and small pelvis, CEA and CA 19-9 markers.

We analyzed 30-day postoperative complications and rated their severity according to Clavien-Dindo grading system [10].

Statistical analysis

To compare frequencies, we used the two-sided Fisher's exact test or Pearson χ^2 test. In case of non-Gaussian distribution, data were described as median and quartiles. Means and standard deviations were applied for data with normal distribution. Between-group comparison was performed using the Mann-Whitney test. Disease-free survival was analyzed using the Kaplan-Meier method. We compared Kaplan-Meier survival curves using log-rank test. Differences were significant at p-value <0.05. Statistical analysis was carried out using the Statistica TIBCO software package (USA).

Results

There were 156 patients with rectal adenocarcinoma pT1 between October 2011 and August 2019 (102 cases — transanal endoscopic microsurgery, 54 cases — total mesorectal excision). Morphological examination after TEM revealed lymphovascular invasion in 38 specimens. TME was proposed in all cases. Ten patients agreed and underwent surgery. Therefore, we excluded these patients from the study. TME was not performed in 28 patients because these ones refused surgery. Thus, the outcomes of TEM were finally analyzed in 92 patients **(Fig. 1)**.

Age and ASA grade were similar in both groups **(Table 1)**. In the TEM group, gender-adjusted distribution was symmetric (49% of men). However, women prevailed in the TME group (70%) ($p = 0.03$). Mean tumor dimension was significantly high-

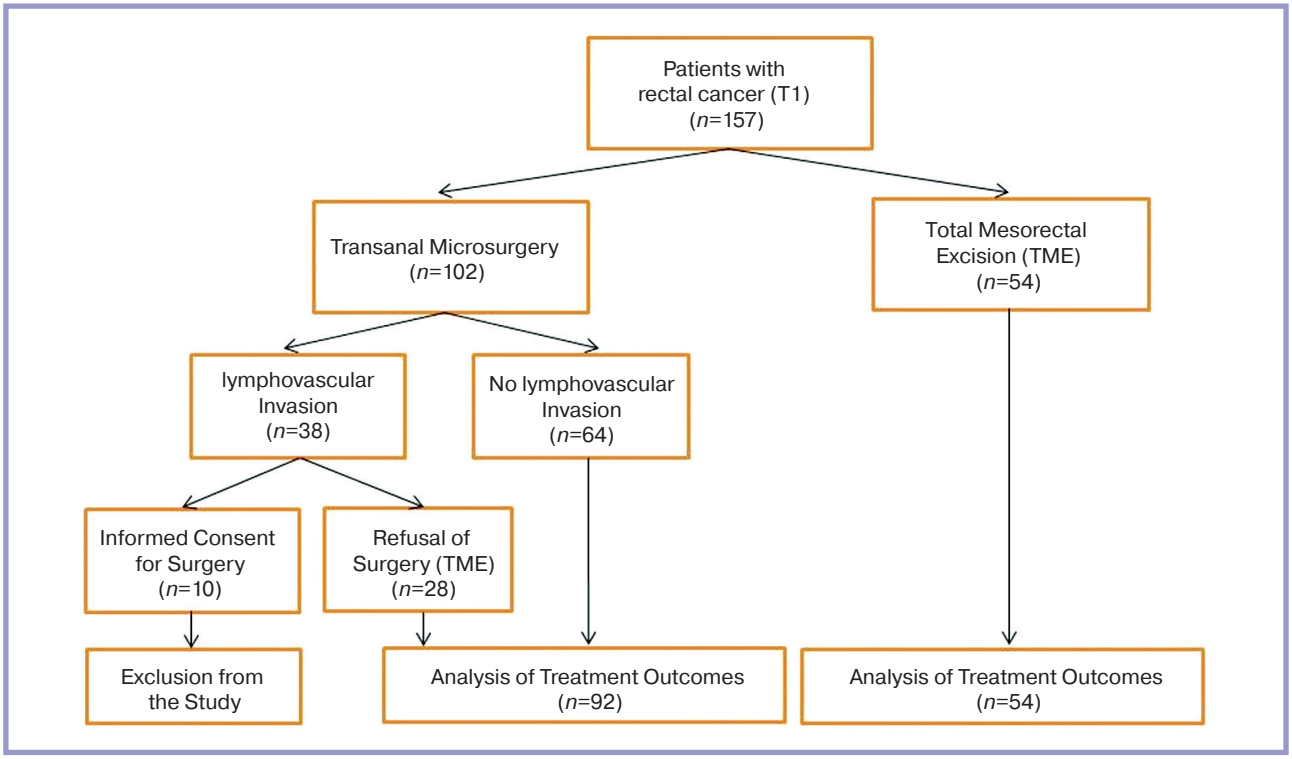

Fig. 1. **Study flowchart.**

er in the TME group (4.0 (3.0; 5.0) vs. 3.0 (2.5; 4.0) cm, p = 0.005) **(Table 1)**.

In the TME group, biopsy confirmed cancer in 39 out of 54 (72%) cases, in the TEM group — 47 out of 92 (51%) patients (p <0.01) **(Table 1)**.

For preoperative verification of invasive rectal tumor and depth of invasion, we performed transrectal ultrasound in 113 patients (74 (80.4%) in the TEM group and 39 (72.2%) in the TME group). Transrectal ultrasound correctly defined tumor invasion grade in 27 out of 113 (26%) patients. There was an obvious tendency to underdiagnosis of invasive cancer, since the tumor was recognized as non-invasive in 71 (62.8%) patients. Overdiagnosis towards T2 cancer was observed only in 15 (13.3%) cases. Between-group differences were expectable **(Table 1)**. Indeed, patients with uT0 tumors prevailed among those selected for local excision (p = 0.013), patients with uT2 neoplasms — in the group of total mesorectal excision (p = 0.0002) **(Table 1)**.

Preoperative pelvic MRI was carried out in 66% of patients in both groups. Muscle layer invasion (T2) was significantly more common in the TME group (22 (62.8%) vs. 14 (22.7%) cases, p = 0.001) **(Table 1)**.

Median of TEM time significantly less compared to TME (40.0 (34; 50) vs. 139 (120; 180) min, p = 0.00001). Postoperative hospital-day was also significantly less in the TEM group (7 (6; 9) vs. 10 (7; 11) days, p = 0.00001). In case of total mesorectal excision, we performed the following procedures: low anterior resection — 19 (36%), anterior — 25 (56%), abdominoperineal resection — 9 (18%) cases. Laparoscopic surgery was performed in 22 patients (40%), Hartmann procedure — in 2 (3.7%) cases. In the TME group, preventive stoma was formed in 40 (76%) cases. Three (3%) patients required colostomy (sigmoid colon) after TEM due to intraoperative connection with abdominal cavity. Median period until stoma closure in the TME group was 4 (3; 6) months **(Table 2)**.

Postoperative morbidity after TEM was 6.8% (7 patients), after TME — 12.7% (7 patients) (p = 0.17). Severity of complications according to Clavien-Dindo grading system was similar in both groups (p = 0.3). Postoperative complications after TEM included bleeding (n=1, 1%), atonic bladder (n=2, 2%), rectovaginal fistula (n=1, 1%), antibiotic-associated colitis (n=1, 1%), atrial flutter (n=1, 1%), parastomal phlegmon (n=1, 1%). In the TME group, adverse events included antibiotic-associated colitis (n=2, 3.7%), gastrointestinal paresis (n=2, 3.7%), colorectal anastomotic leakage (n=3, 5.56%) **(Table 2)**.

In the TEM group, highly differentiated adenocarcinoma was histologically verified in 14 (16%) cases, moderately differentiated tumor — in 78 (84%) cases. In the TME group, these values were 8 (14%) and 46 (86%) cases, respectively (p = 0.86). In the TEM group, invasion depth T1sm1 was found in 41 (45%) patients, T1sm2 — 17 (18%), T1sm3 — 34 (37%). Tumor invasion depth was similar in the TME group (T1sm1 — 20 (37%), T1sm2 — 9 (16%), T1sm3 — 25 (47%), p = 0.4). Lymphovascular invasion was found in 30.5% (28/92) and 26% (14/54) of patients, respectively (p = 0.7). Thus, both groups were comparable regarding the main factors of tumor aggression (differentiation, submucosal invasion depth and lymphovascular invasion). According to histological data, 6 (6.5%) patients had positive resection margin after TEM (lateral edge in all cases) and only 1 (1.8%) patient (circular resection margin) after TME (p = 0.4). Biopsy of postoperative specimen revealed regional lymph node metastases in 11 (20.3%) patients after TME **(Table 3)**.

We followed-up all patients in both groups. The follow-up period was 38 (range 9-88) months in the TEM group and 39

Table 1. **Characteristics of patients and tumors**

Variable	TEM group (n=92)	TME group (n=54)	*p-value*
Age, years	61±11	60.7±8.8	0.25
Gender (m/f)	45/47 (49%)	16/38 (30%)	0.03
Tumor dimension, cm	3.0 (2.5; 4.0)	4.0 (3.0; 5.0)	0.005
Distance to anal canal:			
0—6 cm	51 (55%)	18 (32%)	0.01
7—11 cm	29 (31%)	14 (26%)	0.5
12—15 cm	12 (14%)	22 (42%)	0.0002
Invasion depth according to ERUS data:			
T0	53 (71.6%)	18 (46.2%)	0.007
T1	18 (24.3%)	9 (23.1%)	0.6
T2	3 (4.1%)	12 (30.8%)	0.0004
ERUS not performed	18	15	0.3
Invasion depth according to MRI data:			
T0	28 (45.1%)	9 (25.7%)	0.09
T1	20 (32.2%)	4 (11.4%)	0.04
T2	14 (22.7%)	22 (62.8%)	0.001
MRI not performed	30	19	0.4
Biopsy:			
Adenoma	45 (49%)	15 (28%)	0.01
Adenocarcinoma	47 (51%)	39 (72%)	
ASA grade:			
I—II	34 (37%)	28 (51%)	0.1
III—IV	58 (63%)	26 (49%)	

Table 2. **Characteristics of surgeries and early postoperative outcomes**

Variable	TEM group (*n*=92)	TME group (*n*=54)	*p-value*
Surgery time, min	40.0 (34; 50)	139 (120; 180)	0.00001
Postoperative hospital-stay, days	7 (6; 9)	10 (7; 11)	0.00001
Laparoscopic approach	—	22 (40%)	—
Surgery:			
Low anterior resection	—	19 (36%)	—
Anterior resection	—	25 (56%)	—
Abdominoperineal resection	—	9 (18%)	—
Colostomy after primary surgery	3 (3%)	40 (76%)	0.0001
Colostomy for postoperative complications	—	1 (2%)	—
Period until colostomy closure, months	—	4 (3; 6)	—
Permanent colostomy	—	2 (3.7%) + 1 disconnection	—
Complications after colostomy closure	—	3 (5.4%)	—
Complications (overall incidence)	7 (6.8%)	7 (12.7%)	0.17
Clavien-Dindo grading system:			
I	1 (1%)	2 (3.7%)	0.3
II	5 (5.4%)	3 (5.5%)	0.6
III	1 (1%)	2 (3.7%)	0.3
Atonic bladder	2 (2%)	0	0.3
Bleeding	1 (1%)	0	0.7
Rectovaginal fistula	1 (1%)	0	0.7
Antibiotic-associated colitis	1 (1%)	2 (3.7%)	
Atrial flatter	1 (1%)	0	0.7
Parastomal phlegmon	1 (1%)	0	0.7
Paresis	0	2 (3.7%)	0.12
Colorectal anastomotic leakage	—	3 (5.56%)	

(range 11-80) months in the TME group ($p = 0.7$). Local pelvic recurrences developed in 6 (6.5%) patients after TEM and 1 (1.8%) patient after TME ($p = 0.1$) **(Table 4)**. All patients with local recurrence underwent additional therapy **(Table 5)**. Local control after treatment was achieved for all relapses in the TEM group. In case of recurrence after TME, we performed only chemo- and radiotherapy with subsequent palliative multimodal chemotherapy due to unresectable recurrent neoplasm. There were no distant metastases in both groups throughout the entire follow-up period.

Analysis of Kaplan-Meier disease-free survival revealed that all relapses occurred within 3 years after surgery in both groups **(Fig. 2)**. Disease-free 3-year survival after transanal endoscopic microsurgery was 92%, after TME — 96% ($p = 0.058$) **(Fig. 2)**.

Discussion

Various data on tumor features associated with local and regional metastasis [14] and criteria of local resection of early rectal cancer [3, 13] were accumulated in numerous studies over the past decades. According to the European Association for Endoscopic Surgery (EAES) guidelines, indications for local resection are highly and moderately differentiated adenocarcinoma < 4 cm with invasion depth T1sm1 and no lymphovascular invasion [13]. In the American Society of Clinical Oncology guidelines, these criteria are expanded on tumors with invasion depth T1sm2 and no dimension-related limitations [3].

Total mesorectal excision is a standard treatment for rectal cancer and minimizes the risk of local recurrence [1]. However, deterioration in the quality of life (anal sphincter dysfunc-

Table 3. **Results of morphological examination**

Variable	TEM group (*n*=92)	TME group (*n*=54)	*p-value*
Tumor differentiation grade:			
Highly differentiated	14 (16%)	8 (14%)	0.86
Moderately differentiated	78 (84%)	46 (86%)	
Tumor invasion depth:			
T1sm1	41 (45%)	20 (37%)	0.47
T1sm2	17 (18%)	9 (16%)	0.9
T1sm3	34 (37%)	25 (47%)	0.4
Lymphovascular invasion	28 (30.5%)	14 (26%)	0.7
Number of lymph nodes examined	—	17.7 (12; 23)	—
Lymph node lesion according to morphological examination	—	11 (20.3%)	—
Positive resection margin	6 (6.5%)*	1 (1.8%)**	0.1

Note. * — all cases of positive lateral resection margin in the TEM group; ** — positive circular resection margin.

Table 4. **Long-term treatment outcomes**

Variable	TEM group (*n*=92)	TME group (*n*=54)	*p-value*
Mean follow-up period (min-max), months	38 (9—88)	39 (11—80)	0.7
Local recurrence	6 (6.5%)	1 (1.8%)	0.1
Distant metastases	0	0	

Table 5. **Recurrences in both groups**

Surgery	Resection margins (primary surgery)	Localization of recurrence	Treatment for recurrence	Local control
TEM	R1	Scar	Abdominoperineal rectal resection	yes
TEM	R0	Local extraintestinal	Chemo- and radiotherapy with subsequent rectal extirpation	yes
TEM	R0	Local extraintestinal	Chemo- and radiotherapy	yes
TEM	R0	Local extraintestinal	Chemo- and radiotherapy	yes
TEM	R1	Scar	Low anterior rectal resection	yes
TEM	R0	Local extraintestinal	Low anterior rectal resection	yes
TME	R0	Local extraintestinal	Chemo- and radiotherapy + palliative multimodal chemotherapy	no

tion, LARS, sexual and urinary dysfunction) after TME dictates the need to develop less traumatic methods of local excision [11]. Risk of regional lymph node lesion is the main limiting factor for local tumor excision. Mou S. et al. [12] reported low tumor differentiation and lymphovascular invasion are the main risk factors of local and regional metastases in patients with submucosal invasion. However, this risk does not disappear in patients without these factors. Our study included patients with early moderately or highly differentiated rectal cancer. Lymphovascular invasion detected after TEM was the cause for TME and exclusion of patients from further analysis. However, we analyzed those patients who refused "salvage" surgery. Importantly, incidence of lymphovascular invasion ($p = 0.7$) and submucosal invasion ($p = 0.4$) was similar in both groups. Thus, both groups were comparable by the main factors of tumor aggression, age, gender and concomitant diseases.

Upper ampullary rectal cancer was more common in the TME group ($p = 0.0002$) and its dimension was larger ($p = 0.005$). These findings indicate a relationship between localization and dimension of tumor and choice of treatment strategy.

High incidence of postoperative complications is one of the main causes of looking for surgical alternative to TME. Indeed, Sajid M.S. et al. [13] reported more than 5 times higher incidence of complications after TME compared to TEM (OR 0.19, 95% CI 0.08 — 1.44). In our study, postoperative morbidity was also insignificantly higher after TME (12.7% vs. 6.8%, $p = 0.17$). Moreover, surgery time and postoperative hospital-day were significantly higher in the TME group ($p = 0.00001$).

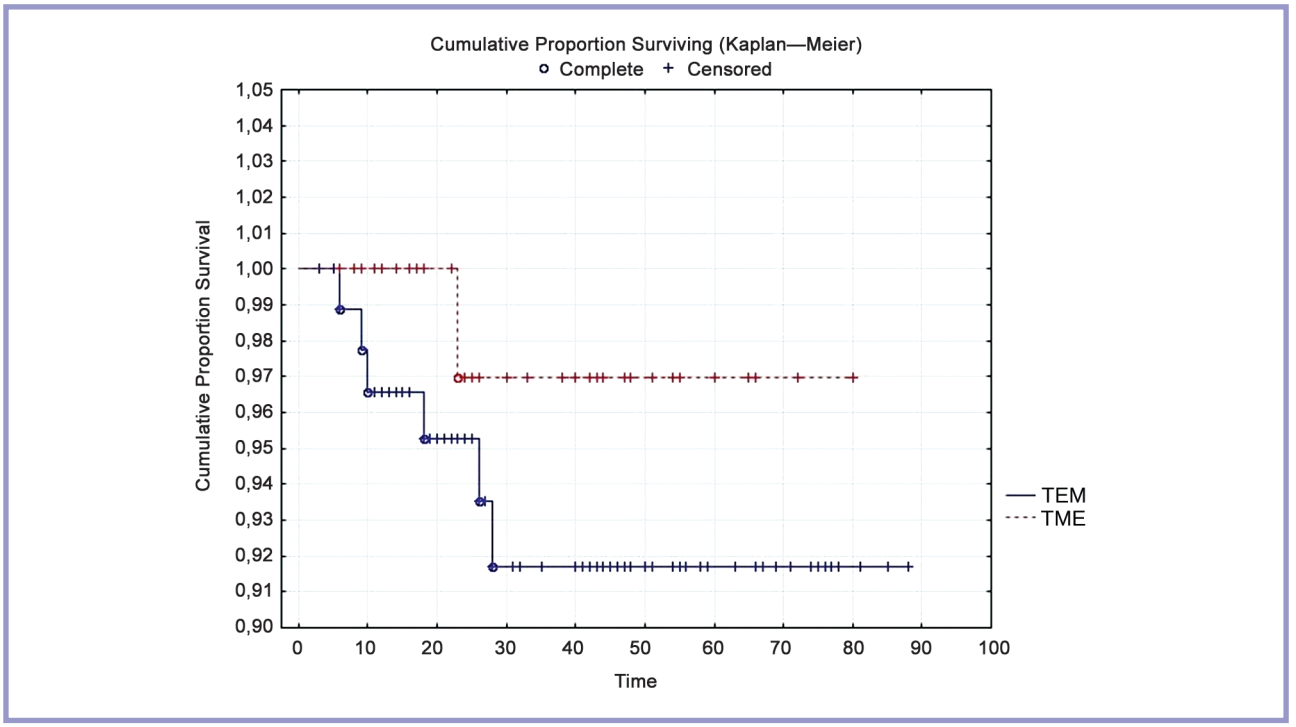

Fig. 2. **Kaplan-Meier disease-free survival.**

Resection margin is the main feature of surgery influencing local recurrence [14]. In our study, there were no significant between-group differences in the incidence of positive resection margin ($p = 0.4$). Morphological examination after TME revealed lymph node metastases in 11 (20.3%) patients. Considering the homogeneity of both groups regarding tumor aggression factors (lymphovascular invasion, depth of submucosal invasion), lymph node lesion in 20.3% of patients casts doubt on the quality of tumor resection in the TEM group. Nevertheless, disease-free survival was similar in both groups ($p = 0.058$). All relapses in both groups occurred within 3 years after surgery. Three-year disease-free survival was 92% after TEM and 96% after TME. Considering this fact, we can say that active control examinations within several years after surgery and their minimization after this period are reasonable.

Conclusion

Transanal endoscopic microsurgery is a relatively safe alternative to total mesorectal excision for early rectal cancer. This procedure is characterized by low postoperative morbidity, similar disease-free survival, less surgery time and postoperative hospital-stay.

The authors declare no conflicts of interest.

REFERENCES

1. Heald RJ. The «Holy Plane» of rectal surgery. *Journal of the Royal Society of Medicine.* 1988;81(9):503-508.
2. Gomila A, Carratala J, Camprubi D, Shaw E, Badia JM feminine, Cruz A, et al. Risk factors and outcomes of organ-space surgical site infections after elective colon and rectal surgery. *Antimicrob Resist Infect Control.* 2017;6:40. https://doi.org/10.1186/s13756-017-0198-8
3. Shelygin YuA, Nagudov MA, Ponomarenko AA, Alekseev MV, Rybakov EG, Tarasov MA, Achkasov SI. Meta-analysis of management of colorectal anastomotic leakage. *Khirurgiya. Zhurnal im. N.I. Pirogova.* 2018;8(2):30-41. https://doi.org/10.17116/hirurgia201808230
4. Juul T, Ahlberg M, Biondo S, Espin E, Jimenez L, Matzel K. Low anterior resection syndrome and quality of life: An international multicenter study. *Dis Colon Rectum.* 2014;57(5):585-591. https://doi.org/10.1097/DCR.0000000000000116
5. Morino M, Risio M, Bach S, Beets-Tan R, Bujko K, Panis Y, et al. Early rectal cancer: the European Association for Endoscopic Surgery (EAES) clinical consensus conference. *Surg Endosc.* 2015;29(4):755-773. https://doi.org/10.1007/s00464-015-4067-3
6. Benson AB, Venook AP, Al-Hawary MM, Cederquist L, Chen Y-J, Ciombor KK, et al. Rectal Cancer, Version 2.2018, NCCN Clinical Practice Guidelines in Oncology. *J Natl Compr Canc Netw.* 2018;16(7):874-901. https://doi.org/10.6004/jnccn.2018.0061
7. Barendse RM, Musters GD, de Graaf EJR, van den Broek FJC, Consten ECJ, Doornebosch PG, et al. Randomised controlled trial of transanal endoscopic microsurgery versus endoscopic mucosal resection for large rectal adenomas (TREND Study). *Gut.* 2018;67(5):837-846. https://doi.org/10.1136/gutjnl-2016-313101
8. Van den Broek FJC, de Graaf EJR, Dijkgraaf MGW, Reitsma JB, Haringsma J, Timmer R, et al. Transanal endoscopic microsurgery versus endoscopic mucosal resection for large rectal adenomas (TREND-study). *BMC Surg.* 2009;9:4. https://doi.org/10.1186/1471-2482-9-4
9. Chernyshov SV, Tarasov MA, Nagudov MA, Mtvralashvili DA, Likutov A, Rybakov EG. Systematic review and meta-analysis of transanal endoscopic microsurgery versus endoscopic submucosal dissection for rectal adenomas and early rectal cancer. *Coloproctology.* 2019;18(68):7-20. https://doi.org/10.33878/2073-7556-2019-18-2-7-14
10. Clavien PA, Barkun J, de Oliveira ML, Vauthey JN, Dindo D, Schulick RD, et al. The Clavien-Dindo classification of surgical complications: five-year experience. *Ann Surg.* 2009;250(2):187-196. https://doi.org/10.1097/SLA.0b013e3181b13ca2
11. Havenga K, Maas CP, DeRuiter MC, Welvaart K, Trimbos JB. Avoiding long-term disturbance to bladder and sexual function in pelvic surgery, particularly with rectal cancer. *Semin Surg Oncol.* 2000;18(3):235-243. https://doi.org/10.1002/(sici)1098-2388(200004/05)18:3<235::aid-ssu7>3.0.co;2-7
12. Mou S, Soetikno R, Shimoda T, Rouse R, Kaltenbach T. Pathologic predictive factors for lymph node metastasis in submucosal invasive (T1) colorectal cancer: A systematic review and meta-analysis. *Surg Endosc.* 2013;27(8):2692-2703. https://doi.org/10.1007/s00464-013-2835-5
13. Sajid MS, Farag S, Leung P, Sains P, Miles WFA, Baig MK. Systematic review and meta-analysis of published trials comparing the effectiveness of transanal endoscopic microsurgery and radical resection in the management of early rectal cancer. *Colorectal Dis.* 2014;16(1):2-14. https://doi.org/10.1111/codi.12474
14. Graham RA, Garnsey L, Jessup JM. Local excision of rectal carcinoma. *Am J Surg.* 1990;160(3):306-312. https://doi.org/10.1016/s0002-9610(06)80030-9

Received 11.02.2021
Accepted 07.04.2021