Pirogov Journal of Surgery
2021, No. 12, pp. 27-33
https://doi.org/10.17116/hirurgia202112127

Analysis of future liver remnant parameters in children after extended liver resection

D.G. AKHALADZE, G.S. RABAEV, YU.N. LIKAR, E.D. KIREEVA, D.YU. KACHANOV, G.V. TERESHCHENKO, N.G. USKOVA, N.N. MERKULOV, K.S. SEMIN, I.V. TVERDOV, N.S. GRACHEV

Dmitry Rogachev National Medical Research Center of Pediatric Hematology, Oncology and Immunology, Moscow, Russia

ABSTRACT

Objective. To analyze the initial data on future liver remnant volume and its function evaluated by ^{99m}Tc-Bromesida hepatobiliary scintigraphy in children with liver tumors.

Material and methods. Extended liver resections were performed in 58 patients aged 2 months — 208 months (median 26 months) for various neoplasms. Before hepatectomy, all children underwent contrast-enhanced CT with volumetry and hepatobiliary scintigraphy with ^{99m}Tc-Bromezida and subsequent quantitative assessment of its accumulation in the future liver remnant. All consecutive patients eligible for extended liver resection were retrospectively analyzed.

Results. The analysis included patients who underwent extended liver resection between June 2017 and March 2021. Among 91 liver resections, 58 (64%) procedures were extended hepatectomies including 2 ALPPS procedures. Median volume of future liver remnant was 44.5% (16.5—91.4), median future liver remnant function — 10.14%/min/m^2 (1.8—30). Four patients with adequate liver function had insufficient volume of future liver remnant. Insufficient future liver remnant volume and its appropriate function were observed in 2 patients. Not life-threatening post-resection liver failure developed in 2 patients.

Conclusion. Evaluation of future liver remnant function is the most sensitive method to predict post-hepatectomy liver failure in children. The cut off value of future liver remnant volume in children is below 25% and probably below 16.5%. Further data collection and research are warranted to determine significant values. These data will contribute to define the new indications for two-staged hepatectomies in children.

Keywords: *future liver remnant function, future liver remnant, children, ALPPS.*

INFORMATION ABOUT THE AUTHORS:
Akhaladze D.G. — https://orcid.org/0000-0002-1387-209X; e-mail: d.g.akhaladze@gmail.com
Rabaev G.S. — https://orcid.org/0000-0002-5691-2522; e-mail: rabaevgesha@gmail.com
Likar Yu.N. — https://orcid.org/0000-0002-6158-2222; e-mail: yury.likar@fccho-moscow.ru
Kireeva E.D. — https://orcid.org/0000-0003-3990-8879; e-mail: elena.kireeva@fccho-moscow.ru
Kachanov D.U. — https://orcid.org/0000-0002-3704-8783; e-mail: kachanov78@gmail.com
Tereshchenko G.V. — https://orcid.org/0000-0001-7317-7104; e-mail: galina.tereshenko@fccho-moscow.ru
Uskova N.G. — https://orcid.org/0000-0001-9424-1646; e-mail: nataliyauskova@gmail.com
Merkulov N.N. — https://orcid.org/0000-0003-0404-6420; e-mail: dr.mernich@yandex.ru
Semin K.S. — https://orcid.org/0000-0002-1897-9312; e-mail: kirillsemin1@rambler.ru
Tverdov I.V. — https://orcid.org/0000-0001-5150-1436; e-mail: twerdov.iwan@yandex.ru
Grachev N.S. — https://orcid.org/0000-0002-4451-3233; e-mail: nick-grachev@yandex.ru
Responsible author: Akhaladze D.G. — e-mail: d.g.akhaladze@gmail.com

TO CITE THIS ARTICLE:
Akhaladze DG, Rabaev GS, Likar YuN, Kireeva ED, Kachanov DYu, Tereshchenko GV, Uskova NG, Merkulov NN, Semin KS, Tverdov IV, Grachev NS. Analysis of future liver remnant parameters in children after extended liver resection. *Pirogov Russian Journal of Surgery = Khirurgiya. Zurnal im. N.I. Pirogova*. 2021;12:27–33. (In Russ.). https://doi.org/10.17116/hirurgia202112127

Introduction

Despite modern data on the possibility of R1 resection in surgical treatment of hepatoblastoma in exceptional cases, total resection is still the “gold standard” for these patients [1]. Among other things, hepatoblastoma as an embryonic tumor is characterized by fast growth that inevitably affects the details of liver resection. Extended resection is required in most cases. One of the most common procedures is extended hemihepatectomy. Children with POST-TEXT III-IV hepatoblastoma require a maximum permissible resection when liver transplantation is considered as an alternative option. These procedures may be followed by post-resection hepatic failure and various methods of surgical prevention have been proposed. Since the combined treatment of hepatoblastoma and some other liver malignancies implies timely adjuvant chemotherapy, the ALPPS procedure ensuring the earliest regenerative hypertrophy of the future liver remnant is the most attractive surgery. Some national and foreign authors reported various volumetric characteristics as indications for ALPPS. Nevertheless, liver remnant volume of 25% is considered the most common

value [2—7]. At the same time, assessment of functional reserve of future liver remnant has not been described in pediatric practice while this approach became very popular in adult surgical hepatology and influenced the evolutionary trajectory of ALPPS procedure. Considering traumatic nature of this surgery and risks of complications after the first surgical stage, analysis of functional reserve of the future liver remnant in children seems to be an urgent objective. Solving of this problem can call into question advisability of such interventions in the treatment of liver tumors in children [8].

The objective was to analyze the initial data on future liver remnant volume and its function in children with liver tumors.

Material and methods

Depending on histological type of liver tumor, most patients received neoadjuvant chemotherapy in accordance with the approved treatment protocol (SIOPEL for hepatoblastoma and hepatocellular cancer, CWS-2009 for embryonic sarcoma, EURHAB for rhabdoid tumor). Planning the forthcoming surgery, we considered primary tumor spread to obtain resection margin free of tumor cells and pathomorphosis after neoadjuvant chemotherapy. Anatomical liver resections via open and laparoscopic approaches were preferred.

Evaluation of liver volumetric characteristics

Preoperative examination included CT volumetry with assessment of total liver volume (TLV)), future liver remnant volume (FLR-V), FLR/TLV ratio and remnant liver volume/body weight ratio (RLV-BWR) [9—12]. FLR/TLV > 25% determined sufficient volume of the future liver remnant as the most common value in adult and pediatric liver surgery. RLV-BWR ⩾ 0.5 was considered as sufficient value.

^{99m}Tc-Bromesida hepatobiliary scintigraphy

Future liver remnant function (FLR-F) was quantified during ^{99m}Tc-Bromesida hepatobiliary scintigraphy. This technique was introduced at the Dmitry Rogachev National Medical Research Center of Pediatric Hematology, Oncology and Immunology and described earlier [13]. According to the literature, risk of postoperative hepatic failure is minimal in adults with a threshold value ⩾ 2.7 %/min/m^2 obtained during ^{99m}Tc hepatobiliary scintigraphy (^{99m}Tc-Mebrofenin) [14].

Table 1. **Characteristics of patients**

Variable (n=58)	n (%)
Age, months	26 (2—208)
Gender	
Male	47 (81%)
Female	11 (19%)
Body mass, kg	Average 18.5 (4.1—76)
Tumor	
Hepatoblastoma	35 (60%)
Hepatocellular cancer	6 (10.2%)
Embryonic liver sarcoma	7 (12.2%)
Malignant germ cell liver tumor (yolk sac tumor)	1 (1.8%)
Intrahepatic cholangiocarcinoma	1 (1.8%)
Focal nodular hyperplasia	3 (5.2%)
Liver hemangioma	3 (5.2%)
Calcifying nodular stromal-epithelial tumor	1 (1.8%)
Liver angiomyolipoma	1 (1.8%)
Intraoperative data	
Surgery time, min	350 (47—710)
Blood loss, ml	150 (0—9000)

Postoperative period

In postoperative period, we assessed liver function considering laboratory data and excluded postoperative liver failure. The latter was classified in accordance with the ISGLS grading system (International Study Group of Liver Surgery) criteria [15, 16].

Results

Extended liver resections for various liver neoplasms were performed in 58 patients aged 2 — 208 months (median 26 months) for the period from June 2017 to March 2021. Patients underwent combined treatment for hepatoblastoma, hepatocellular cancer, embryonic liver sarcoma, rhabdoid liver tumor, liver rhabdomyosarcoma, cholangiocellular cancer and metastatic le-

Table 2. **Surgical interventions. Medians of FLR/TLV ratio (FLR-V, %) and functional reserve of the future liver remnant (FLR-F (%/min/m^2) depending on the type of liver resection**

Surgery	n	Remnant liver segments	FLR-V, %	FLR-F, %/min/m^2
Right-sided hemihepatectomy	9	SI, II, III, IV	52.8 (44—76.5)	12.2 (6.1—18.9)
Left-sided hemihepatectomy	4	SI, V—VIII	62.8 (56.6—84)	27.7 (10—30)
Mesohepatectomy	5	SI, II, III, VI, VII	60 (41—91.4)	8.8 (4.53—20.7)
Extended right-sided hemihepatectomy	23	SI, II, III	35 (16.5—53.3)	7.5 (1.8—18.7)
Two-stage extended right-sided hemihepatectomy (ALPPS)	1	SI, II, III	21.5 (before stage 1) 33 (after stage 1)	5.7 (before stage 1) 7.8 (after stage 1)
Two-stage extended right-sided hemihepatectomy (ALPPS)	1	SI, II, III	30 (before stage 1) 77 (after stage 1)	2.1 (before stage 1) 16.5 (after stage 1)
Extended left-sided hemihepatectomy	12	SVI, VII	41.2 (29—66)	13.8 (4.4—31.2)
Segmentectomies	3*	Except for resected segments	64.5 (63—67)	16 (4.55—16.01)

Note. * one patient underwent simultaneous caudate lobectomy and double segmentectomy 5, 6. Two patients underwent anatomical triple segmentectomy 4b, 5, 6. Considering the number of resected segments, we classified surgery as an extended liver resection.

sions. Isolated surgical treatment was carried out in 1 patient with hepatocellular cancer, 1 patient with calcifying nodular stromal-epithelial tumor, as well as patients with benign liver neoplasms (mesenchymal hamartoma, focal nodular hyperplasia, epithelioid angiomyolipoma, hemangioma). One patient with nephroblastoma of the right kidney complicated by thrombosis of inferior vena cava, left renal and right hepatic veins and right atrium underwent on-pump right-sided nephradrenalectomy with right-sided hemihepatectomy, extirpation of inferior vena cava and right atrium repair. Characteristics of patients are shown in **Table 1**.

Surgeries

Surgical interventions, as well as volumetric and functional characteristics of the future liver remnant are shown in **Table 2**.

Fifty-eight patients underwent extended liver resections, i.e. resection of 3 or more anatomical segments. Extended hemihepatectomies as the largest resections regarding the volume of excised liver parenchyma made up 64% (n = 37). A large volume of excised liver parenchyma was also observed in patients undergoing resections of central segments combined with other segmentectomies (n = 6, 10%). Analysis of volumetric characteristics of the liver remnant and its functional reserve in extended liver resections was the most interesting **(Table 3)**.

Relationship of volumetric and functional characteristics of FLR

Considering the accepted threshold values of volume (25%) and functional reserve (2.7 %/min/m^2) of the future liver remnant, it is obvious that the greatest risk of post-resection liver failure should be in patients with decrease of both indicators. However, there were no similar cases **(Fig. 1)**.

In our sample, post-resection liver failure occurred in 2 patients **(Table 4)**. None of the other 56 patients had liver failure.

Discussion

Fast growth of liver malignancies and their dimensions often determine the need for extended liver resections in children. However, another feature of pediatric patients is predominant stability of key indicators affecting development of post-resection liver failure **(Table 3)**. Significant differences in TLV, FLR-V, their ratio, as well as RLV-BWR and FLR-F from those in adults may be associated with absent diffuse liver lesions, low hepatic toxicity of chemotherapeutic drugs used in most current protocols. Moreover, children have significantly higher reparative potential of liver.

Table 3. **Volumetric and functional values of liver and its future remnant before extended resections (n=59)**

Indicator	Median number series
TLV, ml	442 (111—1921)
FLR, ml	194 (30—1099)
FLR/TLV, %	44.5 (16.5—91.4)
RLV-BWR	1.5 (0.4—3.8)
Hepto-biliary scintigraphy (FLR-F), %/min/m^2	10.14 (1.8—30)

There are no literature data on post-resection liver failure in children. Nevertheless, the future liver remnant volume < 25% is considered to be an indication for surgical prevention of liver failure including ALPPS procedure [8].

Information on liver failure in children who underwent liver resection is absent in the literature. Nevertheless, the volume of the future liver remnant of less than 25% is considered an indication for surgical prophylaxis of liver failure, including ALPPS surgery [8]. The rarity of indications for these interventions is clearly demonstrated in this manuscript and **Table 2**.

In our sample, extended right-sided hemihepatectomies made up 43%. Among these patients, we would like to emphasize those with low FLR-V accompanied by normal functional characteristics of liver. This group included all patients with the future liver remnant volume < 25% (patients 1—4) **(Table 4)**. Of these, only the first one with FLR-F higher than the allowable value underwent ALPPS procedure. Others underwent single-stage extended liver resections. This circumstance is explained by the fact that the first patient underwent ALPPS surgery at initial stage of hepatobiliary scintigraphy research.

On the contrary, functional reserve of the future liver remnant was below the threshold value in patients 5 and 6 with sufficient volumetric characteristics **(Table 4)**. Post-resection liver failure grade B occurred only in the 5th patient. There was the largest intraoperative blood loss in this patient. This fact together with low functional reserve of the future liver remnant could contribute to liver failure. Considering higher sensitivity of functional characteristics of the future liver remnant, we performed ALPPS surgery in the 6th patient with sufficient FLR-V (30 ml) and favorable postoperative outcome.

The 4th patient deserves a special attention. This one with extremely low volume of the future liver remnant (16.5%) and high quantitative indicators obtained during scintigraphy (almost

Table 4. **Characteristics of patients with insufficient volume and function of the future liver remnant**

Patient	Age, months	Body weight, kg	Surgery	FLR-V, %	FLR-F, %/min/m^2	RLV-BWR	SGLS grade of liver failure
1	23	11.5	eRHHE (ALPPS)	21.5 (before stage 1) 33 (after stage 1)	5.7 (before stage 1) 7.8 (after stage 1)	1.4 (before stage 1) 2.2 (after stage 1)	No
2	15	8.5	eRHHE, segmentectomy 1, atypical resection S2	19.8	13.8	1.9	No
3	43	12.9	eRHHE	21	13.6	0.8	No
4	27	14.3	eRHHE, segmentectomy 1	16.5	4.78	0.4	Grade A
5	158	36.6	eRHHE	43	1.8	0.9	Grade B
6	3	4.1	eRHHE (ALPPS)	30 (before stage 1) 77 (after stage 1)	2.1 (before stage 1) 16.5 (after stage 1)	0.7 (before stage 1) 3.5 (after stage 1)	No

Note. eRHHE — extended right-sided hemihepatectomy.

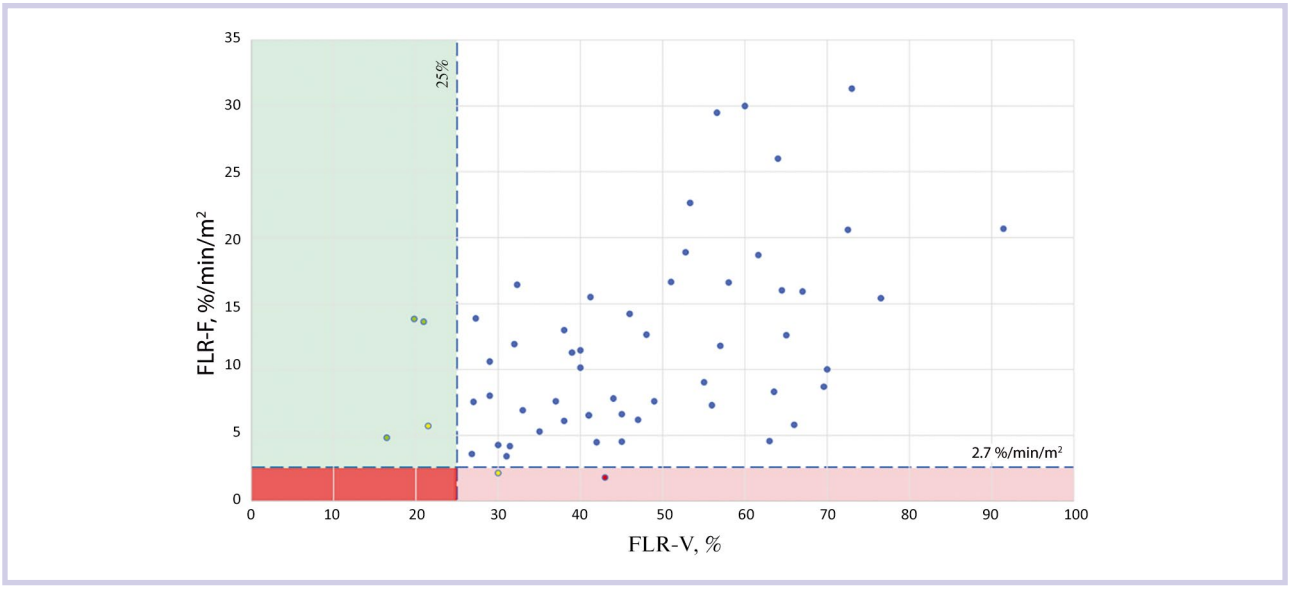

Distribution of volumetric (FLR-V) and functional (FLR-F) indicators of the future liver remnant after extended liver resections (*n*=58).

Note. FLR-V and FLR-F are indicated after the 1st stage of ALPPS.
○ — patients with FLR-F below the threshold value undergoing liver resection
○ — patients with FLR-V below the threshold value undergoing liver resections.
○ — patients with sufficient FLR-V and FLR-F undergoing liver resection.

2 times higher than the accepted thresholds for adults) underwent a single-stage surgery. Postoperative laboratory data were classified as ISGLS grade A without clinically significant disorders.

Conclusion

Considering initial data on liver functional reserve obtained during ^{99m}Tc hepatobiliary scintigraphy in children with liver tumors, we can make the following conclusions:

1. Future liver remnant function is the most sensitive method to predict post-hepatectomy liver failure in children compared to volumetric characteristics of the future liver remnant and their relation to the patient's body weight.

2. Threshold FLR-V in children is below 25% and probably below 16.5%.

Further study of sensitive indicators of volume and function of the future liver remnant is needed to determine new indications for two-stage liver resections in children.

The authors declare no conflicts of interest.

REFERENCES

1. Aronson DC, Weeda VB, Maibach R, Czauderna P, Dall'Igna P, de Ville de Goyet J, et al. Childhood Liver Tumour Strategy Group (SIOPEL). Microscopically positive resection margin after hepatoblastoma resection: what is the impact on prognosis? A Childhood Liver Tumours Strategy Group (SIOPEL) report. *Eur J Cancer*. 2019;106:126-132. https://doi.org/10.1016/j.ejca.2018.10.013
2. Perilongo G, Maibach R, Shafford E, Brugieres L, Brock P, Morland B, et al. Cisplatin versus cisplatin plus doxorubicin for standard-risk hepatoblastoma. *N Engl J Med*. 2009;361(17):1662-1670. https://doi.org/10.1056/NEJMoa0810613
3. Chan A, Chung PH, Poon RT. Little girl who conquered the «ALPPS». *World J Gastroenterol*. 2014;20(29):10208-10211. https://doi.org/10.3748/wjg.v20.i29.10208
4. Sidorov DV, Ryabov AB, Vrublevsky SG, Trunov VO, Lozhkin MV, Glazunov AA, et al. Two-step resection of the liver (ALLPS) in a child with giant embryonic sarcoma. *Detskaya khirurgiya* (Russian Journal of Pediatric Surgery). 2017;21(1):47-50. (In Russ.).
5. Hong JC, Kim J, Browning M, Wagner A, Lerret S, Segura AD, et al. Modified Associating Liver Partition and Portal Vein Ligation for Staged Hepatectomy for Hepatoblastoma in a Small Infant. *Ann Surg*. 2017;266:16-17. https://doi.org/10.1097/SLA.0000000000002217
6. Xu ZL, Wang L, Fan W, Hao Z, Li C. ALPPS for hepatic mesenchymal hamartoma in an infant. *Journal of Pediatric Surgery Case Reports*. 2018;37:70-73. https://doi.org/10.1016/j.epsc.2018.07.023
7. Ruiz Figueroa EF, Fernández-Placencia RM, Berrospi Espinoza FE, Gomez HF, Chávez Passiuri IK. Monosegmental ALPPS: a long-term survival alternative to liver transplant in PRETEXT IV hepatoblastoma. *J Surg Case Rep*. 2019;2019(5):rjz144. https://doi.org/10.1093/jscr/rjz144
8. Akhaladze DG. Is the ALPPS procedure justified in children? *Khirurgiia* (Mosk). 2021;(2):101-105. (In Russ.). https://doi.org/10.17116/hirurgia2021021101
9. Majd M, Reba RC, Altman RP. Hepatobiliary scintigraphy with 99mTc-PIPIDA in the evaluation of neonatal jaundice. *Pediatrics*. 1981;67(1):140-145.
10. Sevilla A, Howman-Giles R, Saleh H, Trpezanovski J, Concannon R, Williams K, et al. Hepatobiliary scintigraphy with SPECT in infancy. *Clin Nucl Med*. 2007;32(1):16-23.
11. McDermott WJ, Greenberger NJ, Isselbacher KJ, Weber AL. Major hepatic resection: diagnostic techniques and metabolic problems. *Surg*. 1963;54(1):56-66.

12. Chaib E, Morales MM, Bordalo MB, Antonio LG, Feijo LF, Ishida RY, et al. Predicting the donor liver lobe weight from body weight for split-liver transplantation. *J Med Biol Res*. 1995;28(7):759-760.

13. Likar YuN, Akhaladze DG, Rumyantsev AG. Hepatobiliary scintigraphy in the preoperative assessment of the future remnant liver function (literature review and own examples). *Russian Journal of Pediatric Hematology and Oncology*. 2020;7(1):62-69. (In Russ.). https://doi.org/10.21682/2311-1267-2020-7-1-62-69

14. De Graaf W, Van Lienden KP, Dinant S, Roelofs J, Busch O, Gouma DJ, et al. Assessment of future remnant liver function using hepatobiliary scintigraphy in patients undergoing major liver resection. *J Gastrointest Surg*. 2010;14(2):369-378. https://doi.org/10.1007/s11605-009-1085-2

15. Rahbari NN, Garden OJ, Padbury R, Brooke-Smith M, Crawford M, Adam R, et al. Posthepatectomy liver failure: a definition and grading by the International Study Group of LiverSurgery (ISGLS). *Surgery*. 2011;149(5):713-724.

16. Wakabayashi H, Ishimura K, Okano K, Karasawa Yu, Goda F, Maeba T, et al. Application of preoperative portal vein embolization before major hepatic resection in patients with normal or abnormal liver parenchyma. *Surgery*. 2002;131:26-33.

17. Rathore S, Matsuo H, Terashima M, Kinoshita Y, Kimura M, Tsuchikane E, et al. Procedural and in-hospital outcomes after percutaneous coronary intervention for chronic total occlusions of coronary arteries 2002 to 2008: impact of novel guidewire techniques. *JACC Cardiovasc Interv*. 2009;2(6):489-497. https://doi.org/10.1016/j.jcin.2009.04.008

Received 30.04.2021
Accepted 20.05.2021