Pirogov Journal of Surgery
2021, No. 12, pp. 20-26
https://doi.org/10.17116/hirurgia202112120

Retrosternal goiter in thoracic surgical practice

V. ANIKIN[1, 2], K. WELMAN[1], N. ASADI[1], P. DALAL[1], I. RESHETOV[2], E. BEDDOW[1]

[1]Harefield Hospital of the Royal Brompton and Harefield Hospital NHS Foundation Trust, Harefield, UK;
[2]Sechenov First Moscow State Medical University, Moscow, Russia

ABSTRACT

Objective. To evaluate and optimize surgical approaches to the management of retrosternal goiter.

Material and methods. A cohort retrospective single-center study included 56 patients aged 68.3±9.8 years with retrosternal goiter who underwent surgery between 2004 and 2019. Right-sided goiter was diagnosed in 16 cases, left-sided goiter in 21 patients, bilateral goiter in 19 patients. Palpable neck mass was found in 17 (30.4%), stridor in 16 (28.6%), thyrotoxicosis in 4 (7.1%) and recurrent laryngeal nerve palsy in 2 (3.6%) cases. X-ray signs of tracheal compression were detected in 43 (76.8%) patients, deviation in 26 (46.4%) patients. Resection through cervical collar incision was performed in 40 (71.4%) patients. Additional sternotomy was required in 11 (19.6%) patients, 1 (1.8%) patient required collar incision and right anterior mediastinotomy. Right-sided posterolateral thoracotomy without collar incision was performed in 1 (1.8%) patient with a suspected mediastinal teratoma. Three patients underwent median sternotomy only because of preoperative diagnosis of teratoma in one and thymoma in two patients.

Results. There was no perioperative mortality. Transient vocal changes occurred in 3 (5.4%) patients, recurrent laryngeal nerve palsy in 3 (5.4%), atrial fibrillation in 2 (3.6%), wound complications in 2 (3.6%), left phrenic nerve palsy in 1 (1.8%), transient hypocalcaemia in 1 (1.8%) and persistent hypothyroidism in 1 (1.8%) patient. Hospital-stay ranged from 2 to 12 (5.5±2.0) days. Multinodular goiter was found in 53 (94.6%) patients, diffuse goiter in 1 (1.8%), ectopic thyroid in 1 (1.8%) and oncocytic tumor in 1 (1.8%) patient. One (1.8%) patient underwent simultaneous resection of RSG via a collar incision and right-sided VATS upper lobectomy for primary lung cancer. One (1.8%) patient also underwent simultaneous resection of RSG via collar incision and right-sided VATS subcarinal lymph node biopsy for coexistent lymphoma. Mean vertical length of goiter in the collar incision group was 7.6 cm compared to 10.6 cm in the sternotomy group. Mean weight of specimens was 162.3 g in patients with collar incisions and 312.5 g in the sternotomy group. Sternotomy was required in 14 (25%) patients.

Conclusion. Resection of retrosternal goiter is more commonly performed via cervical collar incision with mandatory availability of sternotomy. Radiological measurement of craniocaudal length may predict the need for sternotomy. Surgical outcomes are not affected by surgical approach. Simultaneous thoracic interventions for a coexistent pathology in patients with RSG may be considered. Further research of minimally invasive interventions for RSG resection is required.

Keywords: *retrosternal goiter, sternotomy, simultaneous surgery.*

INFORMATION ABOUT THE AUTHORS:
Anikin V. — https://orcid.org/0000-0001-5634-9306; e-mail: v.anikin@rbht.nhs.uk
Welman K. — https://orcid.org/0000-0002-3014-8159; e-mail: klvwelman@gmail.com
Asadi N. — https://orcid.org/0000-0002-3975-3902; e-mail: n.asadi@rbht.nhs.uk
Dalal P. — https://orcid.org/0000-0001-5583-8618; e-mail: p.dalal@rbht.nhs.uk
Reshetov I. — https://orcid.org/0000-0002-0909-6278; e-mail: reshetoviv@mail.ru
Beddow E. — https://orcid.org/0000-0002-9184-5783
Corresponding author: Anikin V. — e-mail: anikin@rbht.nhs.uk

TO CITE THIS ARTICLE:
Anikin V, Welman K, Asadi N, Dalal P, Reshetov I, Beddow E. Retrosternal goiter in thoracic surgical practice. *Pirogov Russian Journal of Surgery = Khirurgiya. Zurnal im. N.I. Pirogova*. 2021;12:20–26. (In Russ.). https://doi.org/10.17116/hirurgia202112120

Introduction

Retrosternal goitre (RSG) is defined as a thyroid mass that extends 3 or more centimetres below the suprasternal notch when the neck is hyperextended [1]. Retrosternal extension can be detected in 1–20% of goitres, depending on the chosen definition [2]. Even though RSG are usually benign in nature, few previous studies have demonstrated recommended an aggressive surgical approach due to the possibility of malignancy that could reach as high as 17%. [3,4]. Surgical removal is usually curative and prevents potentially fatal compressive symptoms. A collar incision is the main surgical access, but an additional sternotomy, thoracotomy or endoscopic techniques [5] may be required to assist surgical removal.

The aim of this study is to define the preoperative characteristics of patients with RSG operated in a tertiary cardio-thoracic centre, to evaluate the factors that may influence surgical approaches, to assess clinical outcomes in order to optimise the treatment strategy and to inform patients better on an individual basis about the expected outcomes of surgery. Another goal of this study is to demonstrate how a sternotomy and other thoracic approaches may be used in patients with a retrosternal goitre alone or in combination with other pathology.

Materials and Methods

Retrospectively analysis of all patients with RSG operated in the Department of Thoracic Surgery of Harefield Hospital from 2004 to 2019 was performed. Harefield Hospital is a specialist tertiary cardio-thoracic centre. Data were collected in line with the trust's policy on data protection, and data such as patient demographics, presentation, intraoperative management and follow-up details were recorded, in accordance with the declaration of Helsinki. Ethical approval of the study was not thought because of the retrospective nature of the study and because no new or experimental approach have been used to treat these patients. The work has been reported in line with the STROCSS criteria [6]. All patients underwent computed tomography (CT) scanning prior to referral. A single radiology specialist analysed all radiological data, to avoid reporter bias. Simple data analysis techniques were used. There were no exclusions.

All patients with pathology of thyroid gland treated in our institution in the described period were included in this study. There were 56 patients with RSG referred electively to our centre in the study period. Nineteen (33.9%) were referred by respiratory physicians, 16 (28.6%) by endocrinologists, 12 (21.4%) by ENT specialists and 9 (16.1%) by general practitioners. The age ranged from 37 to 87 (mean 68.3 ± 9.8) years. There were 44 (78.6%) females and 12 (21.4%) males. The pathology was right sided in 16 (28.6%), left-sided in 21 (37.5%) and bilateral in 19 (33.9%) patients. Only in 7 (12.5%) patients the RSG was detected incidentally on routine chest radiography requested for other reasons. These patients had no relatable signs or symptoms. The other 49 (87.5%) patients had a combination of symptoms, the most common being breathing difficulties such as shortness of breath on exertion or even stridor **(Table 1)**. The second most common symptom was dry cough, usually of several months' duration. This often occurred in conjunction with breathing difficulties, but in 3 (5.4%) patients, dry cough was the only symptom experienced. Vocal changes were noted in 11 (19.6%) cases, mostly comprising deepening or weakening of the voice.

Initial examination revealed a variety of findings, most common being a palpable mass on the neck **(Table 2)**. The majority of patients were euthyroid, but 4 (4.7%) had evidence of thyrotoxicosis and 2 (3.6%) were hypothyroid. Two (3.6%) patients had preoperatively proven complete recurrent laryngeal nerve palsy.

Tracheal compression was seen on a CT scan in 43 (76.8%), and tracheal deviation was detected in 26 (46.4%) patients **(Fig. 1)**. In most cases, the tracheal deviation was contralateral to the predominant side of the pathology, however, in one patient with bilateral pathology, the deviation was apparently posterior with displacement of the oesophagus laterally. Compression of the superior vena cava (SVC) was evident on the CT scans of 4 (7.1%) patients, both of whom had dilated neck veins on initial examination. Preoperative CT showed that the average vertical length of goitres in the collar incision group was 7.6 cm, and the average length of goitres in the sternotomy group was 10.6 cm. The longest goitre recorded on CT was 18 cm in craniocaudal length, the shortest was 3.3 cm. The widest measurement

Table 1. **Clinical symptoms in patients with retrosternal goiter**

Symptom	No. of cases	Percentage
None	7	12.5
Exertional dyspnoe	29	51.8
Dry cough	15	26.8
Vocal changes	11	19.6
Acid reflux	9	16.1
Dysphagia	7	12.5
Chest pain	4	7.1
Referred otalgia	1	1.8

Table 2. **Clinical data in patients with retrosternal goiter**

Finding	No. of cases	Percentage
Anterior neck mass	17	30.4
Stridor	16	28.6
Dilated neck veins	9	16.1
Hyperthyroidism	4	7.1
Hypothyroidism	2	3.6

in both transverse and anteroposterior diameters was 8 cm. In 31 (55.4%) patients the lower edge of the goitre was adjacent with the aortic arch causing displacement of it. The mass was contained within the anterior mediastinum in 21 (37.5%) patients, 8 (14.3%) patients had RSG mainly in the posterior mediastinum and in 27 (48.2%) cases RSG occupied more than one mediastinal compartment.

Five (8.9%) patients underwent preoperative radiology-assisted biopsies of the mass, which were all reported as Thy-2 in nature. Radiological diagnosis of RSG is usually straightforward, but in 1 (1.8%) patient a mediastinal teratoma **(Fig. 2)** and in 2 (3.6%) patients thymoma was diagnosed.

All operative procedures have been performed by one of the consultant thoracic surgeons as a primary operator or as a first assistant. The mass was removed in 40 (71.4%) patients via a cervical collar incision only. In 11 (19.6%) patients an addition-

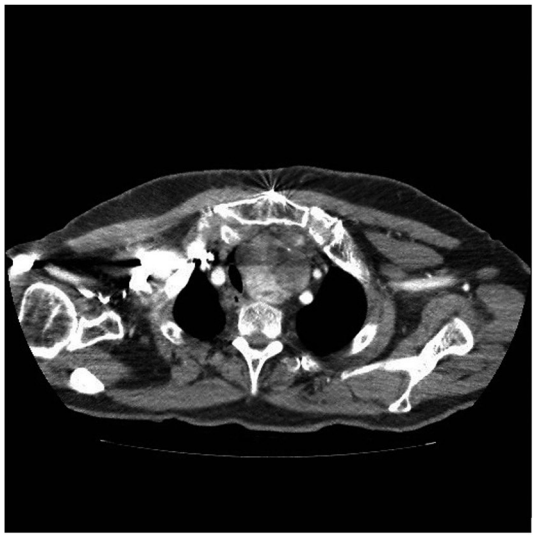

Fig. 1. **CT. Compression and displacement of trachea following retrosternal goiter.**
Previous sternotomy for coronary artery bypass grafting.

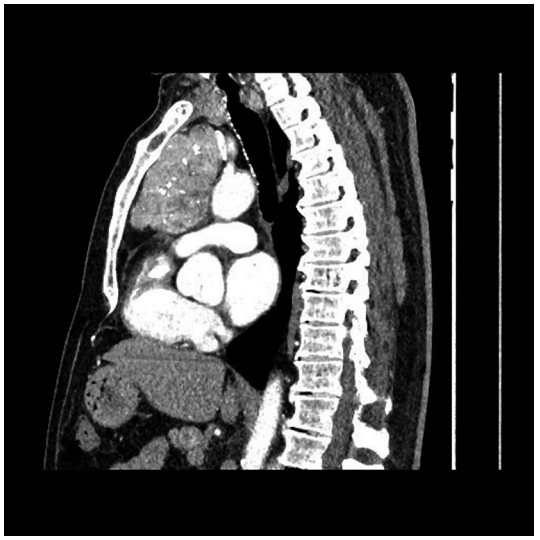

Fig. 2. **Sagittal CT scan of a patient with retrosternal goiter.**
Preoperative diagnosis of teratoma. The mass was resected through median sternotomy.

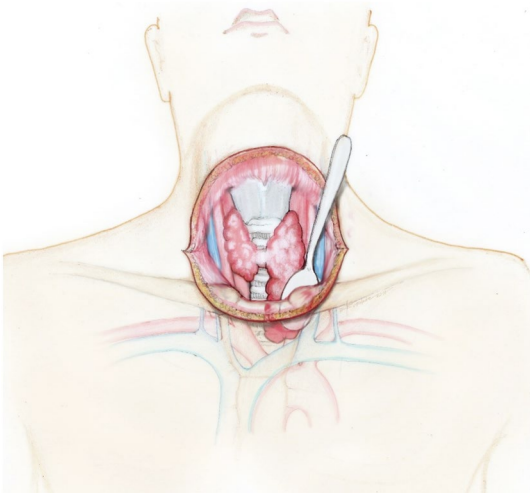

Fig. 3. **Mobilization of retrosternal goiter using a spoon.**

al sternotomy was required and 1 (1.8%) patient had a right anterior mediastinotomy to push the right-sided goitre from below to deliver it up and out through the collar incision to avoid the need for sternotomy. All procedures with confirmed diagnosis of RSGwere started with a standard collar incision with exposure of goitre. The mass was mobilised and delivered into the neck incision with traction and with the help of digital exploration of the mediastinum. We did not employ neuromonitoring during the procedure. A tissue sparing subtotal resection was performed in all patients. A sternotomy was performed when an individual operator decided that any further attempts of mobilisation of the intrathoracic component of the goitre presents a very high risk of bleeding or damage to the critical anatomical structures or if it was not possible to mobilise the mass through the neck incision only. A previously described technique [1] may also prevent the need for sternotomy should the use of a finger through the cervical incision fail to deliver the thyroid, is the use of a sterilised dessertspoon to scoop the RSG mass from within its cavity and present it out through the collar incision **(Fig. 3)**. The spoon is passed initially under control of a finger under the lower end of the mass. After that a finger is withdrawn and the lesion could be relatively easy moved upwards manipulating the spoon around the target. This is particularly useful in patients with localisation of the mass in the posterior mediastinum or in patients with a very narrow upper thoracic inlet. Seven (12.5%) of our patients with RSG mainly in the posterior mediastinum were managed with a collar incision and the "spoon technique". In 1 (1.8%) patient simultaneous removal of RSG via a collar incision and the right VATS upper lobectomy for a primary lung cancer was performed. One (1.8%) patient also had a simultaneous removal of RSG via a collar incision and a right VATS subcarinal lymph node biopsy for a coexistent lymphoma. A right postero-lateral thoracotomy without a collar incision was performed in 1 (1.8%) patient with a suspected mediastinal teratoma. Three patients underwent a median sternotomy only because of preoperative diagnosis of teratoma in one **(Fig. 2)** and thymoma in two patients. Altogether a sternotomy was required in 14 (25%) patients, and it was always performed electively.

Results

There was no operative mortality. The anaesthetic time ranged from 92.6 to 170.6 (mean 118.8 ± 12.0) min in the cervical collar group and from 132.6 to 160.6 (mean 235.8± 14.0) min in the sternotomy group. Hospital stay ranged from 2 to 12 days (mean 5.5 ± 2.0 days). In the cervical collar group, mean hospital stay was 5 days, whereas in the sternotomy group, the mean stay was 7 days. There was no increased morbidity which we could attribute solely to the advanced age.

Vocal changes were seen in 6 (17.1%) patients, 3 of whom were found to have recurrent laryngeal nerve palsy. Of these, two had a collar incision alone and this complication has likely occurred because of a very large size of the mass. One patient developed this complication after right thoracotomy for a suspected teratoma when the mass was impacted into the right thoracic outlet. Only one patient with vocal changes had undergone a sternotomy and this had resolved at one month. Sternotomy was therefore not associated with increased risk of vocal changes.

Other complications included postoperative atrial fibrillation, superficial wound infection, transient hypocalcaemia and hypothyroidism in 1 (1.8%) patient each. One patient had left phrenic nerve palsy which developed after removal of RSG via a collar incision. This complication has likely occurred because of a transmitted traction to the nerve in a patient with a very large mass adjacent to the left lateral surface of the pericardium. No patient experienced tracheomalacia or needed a tracheostomy, and none experienced postoperative bleeding or haematoma. Overall, our complication rate was low and there was no evidence that any complication was more common following sternotomy.

All 56 patients were followed up postoperatively. Persistent breathing difficulties remained in 3 patients and 1 had worsen-

ing of her thyroid-related eye symptoms. No patient required a postoperative blood transfusion. The difference in pre-operative and post-operative haemoglobin levels was used as a marker for blood loss. The average difference in pre-operative and to post-operative haemoglobin was 1.5 g/dL in the cervical collar group versus 3.1 g/dL in the sternotomy group. No revision surgery was required.

All specimens were sent for histology. Multinodular goitre was found in 53 (94.6%), smooth goitre in 1 (1.8%), ectopic normal thyroid tissue in 1 (1.8%) and borderline oncocytic tumour in 1 (1.8%) patient. A difference was seen in the weight of specimens obtained via cervical collar alone versus sternotomy, with the average specimen being 156.3 g in collar incisions and 307.5 g in sternotomy patients. Preoperative CT showed that the average vertical length of goitres in the collar incision group was 7.6 cm, and the average length of goitres in the sternotomy group was 10.6 cm. There was no correlation between goitre size and the number or type of symptoms experienced.

Discussion

Surgical removal of the mass is the gold-standard management in patients with RSG. However, guarded follow-up may be considered because RSGs are typically slow growing in nature. In patients with evidence of airway compromise, most centres would strongly encourage operative management, and some have successfully employed tracheobronchial stenting as a procedure to delay definitive surgery where appropriate [7]. However, it has never been done in this series.

Our patients were predominantly female, which is similar to the findings in other studies [4]. Strength of this study is that this is a relatively large cohort of patient operated in a specialised thoracic department of a tertiary cardio-thoracic centre. RSG detection is usually an incidental finding, although is quoted to be up to 20% in some areas of the world [3]. The overwhelming majority of patients did not present with an anterior neck mass. The most common presenting complaint in our patients was breathing difficulties, secondary to tracheal deviation or compression. The unusual presentation of right-sided ear pain occurred in one patient in association with a large left-sided RSG causing deviation of structures to the right. It is thought that this may have been referred pain created by pressure on the vagus nerve, and it is a rare phenomenon [8].

RSG is usually contained within the anterior mediastinum, however, posterior mediastinal RSG occurs in 10–15% of cases [9].

Most RSG can be managed through a cervical incision although it has been suggested that RSG with a large proportion of mass in the posterior mediastinum more likely require sternotomy [10]. Extension of the mass to the aortic arch and SVC obstruction are also factors that have been attributed to increased rates of sternotomy [11, 12]. Seven (12.5%) out of 8 patients who had RSG mainly in the posterior mediastinum were managed with a collar incision and the “spoon technique” [1] similar to using a Parker-Langenbeck retractor to deliver the RSG through a collar incision [13].

All our patients who underwent sternotomy had evidence of extension to the level of the aortic arch. But out of 31 (55.4%) patients who had extension of the RSG to the aortic arch only 11 (35.5%) required a sternotomy, and therefore aortic arch extension should not be considered as a reliable predictor of sternotomy. Of two patients with evidence of SVC obstruction on preoperative CT, one underwent a collar incision alone without sternotomy which demonstrates that SVC obstruction does not imply obligatory sternotomy.

The average vertical length of goitres in the collar incision group was 7.6 cm, whereas the average length of goitres in the sternotomy group was 10.6 cm. In the average-sized person, those who require sternotomy for surgical removal tend to have an RSG that is 3 cm longer in craniocaudal dimension than those who can be managed by collar incision alone. Therefore, the craniocaudal length of the goitre is possibly a more reliable predictor of sternotomy in our practice.

There was no operative mortality among our patients, however, previous studies have reported mortality rates of up to 2.3% [14]. Overall complication rate was low and vocal changes were the most common adverse effects. The rate of recurrent laryngeal nerve palsy in our patients was 5.4%, which compares favourably with previously reported rates of up to 13.2% [12]. In thyroid surgery without retrosternal extension, the rate of recurrent laryngeal nerve palsy is widely accepted to be less than 1%. It is well-documented that retrosternal extension carries a greater risk of injury to the recurrent laryngeal nerve during surgical removal [15]. However, a lower incidence of recurrent laryngeal nerve injury when employing sternotomy was reported [16].

Another well known complication is transient hypocalcaemia, occurring in up to 6% of surgeries for RSG secondary to parathyroid manipulation or damage [17]. This complication was encountered in only one (1.8%) patient. One patient developed the left phrenic nerve palsy, which is rare, but should be kept in mind when discussing possible complications with patients preoperatively. In the sternotomy group the average anaesthetic time was 117 min longer and hospital stay was 2 days longer. No complication was more common with sternotomy. The relatively high (25%) incidence of sternotomy in this series is probably related to referral patterns when the patients with particularly extensive disease were referred to our department.

Surgical management for patients with RSG requires careful preoperative planning and many factors should be considered when considering alternative approaches such as sternotomy and thoracotomy. Manubriotomy may be another safe alternative, which allows exposure of structures within the thoracic inlet although direct comparison of this technique against others has not been evaluated in terms of patient risk [15]. Newer techniques such as endoscope-assisted and video-assisted thoracoscopic thyroidectomy and other versions of minimally inviasive interventions also provide options for minimally invasive surgical removal of RSG [18]. Further study of the success of these techniques is needed.

Concomitant procedures are not very common in patients with RSG, but in our practice one patient have been operated radically for a primary lung cancer and one patient had a diagnostic procedure for a lymphoma confirming possibility of such an approach.

Age discrimination in surgery is a widely debated topic in the United Kingdom. The Royal College of Surgeons have reported on access to surgery in relation to age and suggest that biological rather than chronological age should be considered clinically relevant [19]. The oldest patient operated on in our study was 87-years old and the mean age of our patients (68.3 years) is older than the mean ages of 40–50 years quoted in other studies [4].

Conclusion

Surgical removal of RSG should be offered to essentially all the patients with this pathology. Preferably it should be performed via a cervical incision with mandatory availability of sternotomy in case of emergency or planned conversion.

Radiological measurement of craniocaudal length may predict the need of a sternotomy. Surgical outcomes are not affected by surgical approach. Simultaneous thoracic interventions for a coexistent pathology in patients with RSG may be considered. The future research of minimally invasive interventions for removal of RSG is required.

Conflict of interest

The authors declare no potential conflicts of interest with respect to the research, authorship, and/or publication of this article.

Ethical Approval

All procedures performed in studies involving human participants were in accordance with the ethical standards of the institutional and/or national research committee and with the 1964 Helsinki declaration and its later amendments or comparable ethical standards. This article does not contain any studies with animals performed by any of the authors.

Informed Consent

Informed consent was obtained from all individual participants included in the study.

Funding

This study was partially supported by Cryosurgery Fund of Harefield Hospital.

Provenance and peer review

Not commissioned, externally peer-reviewed.

Acknowledgement

Authors express deep gratitude to Mr M. Bunalade for an excellent artwork which was used in this paper.

The authors declare no conflicts of interest.

REFERENCES

1. Welman K, Heyes R, Dalal P, Hough S, Bunalade M and Anikin V. Surgical Treatment of Retrosternal Goitre. *Indian J Otolaryngol Head Neck Surg*. 2017;69:345-350. https://doi.org/10.1007/s12070-017-1151-0
2. Rodrigues J, Furtado R, Ramani A, Mitta N, Kudchadkar S, Falari S. A rare instance of retrosternal goitre presenting with obstructive sleep apnoea in a middle-aged person. *Int J Surg Case Rep*. 2013;12:1064-1066. https://doi.org/10.1016/j.ijscr.2013.07.040
3. Sanders LE, Rossi RL, Shahian DM, Williamson WA. Mediastinal goiters: the need for an aggressive approach. *Arch Surg*. 1992;127:609-613. https://doi.org/10.1001/archsurg.1992.01420050137018
4. Katlic MR, Grillo HC, Wang CA. Substernal goiter: analysis of 80 patients from Massachusetts General Hospital. *Am J Surg*. 1985;149:283-287. https://doi.org/10.1016/s0002-9610(85)80086-6
5. Fan Q, Gong K, Zhu B, Zhang NW. Experience of managing substernal goitre by totally endoscopic procedure. *Beijing Da Xue Xue Bao*. 2014;46:488-491. PMID: 24943035.
6. Agha R, Abdall-Razak A, Crossley E, Dowlut N, Iosifidis C and Mathew G, for the STROCSS Group. The STROCSS 2019 Guideline: Strengthening the Reporting of Cohort Studies in Surgery. *International Journal of Surgery*. 2019;72:156-165. https://doi.org/10.1016/j.ijsu.2019.11.002
7. Piao M, Yuan Y, Wang Y, Feng C. Successful management of trachea stenosis with massive substernal goitre via tracheobronchial stent. *J Cardiothorac Surg*. 2013;8:212. https://doi.org/10.1186/1749-8090-8-212
8. Schoenen J, Broux R, Moonen G. Unilateral facial pain as the first symptom of lung cancer: are there diagnostic clues? *Cephalalgia*. 1992;12:178-179. https://doi.org/10.1046/j.1468-2982.1992.1203178.x
9. Kacprzak G, Karas J, Rzechonek A, Blasiak P. Retrosternal goitre located in the mediastinum: surgical approach and operative difficulties. *Interact Cardiovasc Thorac Surg*. 2012;15:935-937. https://doi.org/10.1093/icvts/ivs339
10. Chen X, Xu H, Ni Y, Sun K, Li W. Complete excision of a giant thyroid goiter in posterior mediastinum. *J Cardiothorac Surg*. 2013;8:207. https://doi.org/10.1186/1749-8090-8-207
11. McKenzie GA, Rook W. Is it possible to predict the need for sternotomy in patients undergoing thyroidectomy with retrosternal extension? *Interact Cardiovasc Thorac Surg*. 2014;19:139-143. https://doi.org/10.1093/icvts/ivu094
12. Sakkary MA, Abdelrahman AM, Mostafa AM, Abbas AA, Zedan MH. Retrosternal goitre: the need for thoracic approach based on CT findings: surgeon's view. *J Egypt Natl Canc Inst*. 2012;24:85-90. https://doi.org/10.1016/j.jnci.2012.04.002
13. Naraynsingh V, Ramarine I, Cawich S, Maharaj R, Dan D. Cervical leverage: a new procedure to deliver deep retrosternal goitres without thoracotomy. *Int J Surg Case Rep*. 2013;11:992-996. https://doi.org/10.1016/j.ijscr.2013.08.014
14. Landerholm K, Järhult J. Should asymptomatic retrosternal goitre be left untreated? A prospective single-centre study. *Scand J Surg*. 2014;23:1-4. https://doi.org/10.1177/1457496914523411
15. Testini M, Gurrado A, Bellantone R, Brazzarola P, Cortese R, De Toma G, et al. Recurrent laryngeal nerve palsy and substernal goiter. An Italian multicenter study. *J Visc Surg*. 2014;151:183-189. https://doi.org/10.1016/j.jviscsurg.2014.04.006
16. Rolighed L, Rønning H, Christiansen P. Sternotomy for substernal goiter: retrospective study of 52 operations. *Langenbecks Arch Surg*. 2015;400:301-306. https://doi.org/10.1007/s00423-015-1288-9
17. Shaha AR, Jaffe BM. Parathyroid preservation during thyroid surgery. *Am J Otolaryngol*. 1998;19:113-117. https://doi.org/10.1016/s0196-0709(98)90106-5
18. Gupta P, Lau KK, Rizvi I, Rathinam S, Waller DA. Video assisted thoracoscopic thyroidectomy for retrosternal goitre. *Ann R Coll Surg Engl*. 2014;96:606-608. https://doi.org/10.1308/003588414x14055925058634

19. Ablicov AYu, Ablicov YuA, Vasilashko VI, Lukyanov PA. Thoracoscopic surgery of retrosternal and inrathoracic goiter. *Bulletin of Pirogov National medical and surgical center.* 2019;14(1):22-26. https://doi.org/10.25881/BPNMSC.2019.28.33.004

20. Gostimskii AV, Romanchishen AF, Selikhanov BA, Lisovskii OV. Urgent operations in pations with with diseases of thyroid gland complicated by compression of neck and mediastinum. *Vestnik Rossijskoj Voenno-meditsinskoj akademii*. 2019;S1:60-63.

21. Ahamat N. Access all ages: assessing the impact of age on access to surgical treatment. *Bull R Coll Surg Engl*. 2012;94:300. https://doi.org/10.1308/147363512x13448516926748

Received 05.11.2021
Accepted 08.03.2021