Хирургия. Журнал имени Н.И. Пирогова
2020, №1, с. 14-24
https://doi.org/10.17116/hirurgia202001114

Pirogov Journal of Surgery
2020, №1, pp. 14-24
https://doi.org/10.17116/hirurgia202001114

Diagnostic and treatment of the intraductal papillary mucinous tumor of pancreas

© A.G. KRIEGER[1], G.G. KARMAZANOVSKIY[1], V.I. PANTELEEV[1], D.S. GORIN[1], N.N. VETSHEVA[2], S.V. BERELAVICHUS[1], A.R. KALDAROV[1], A.V. GLOTOV[1]

[1]Federal State Budget Institution «National Medical Research Center of Surgery named after A.V. Vishnevsky» under Ministry of Health of Russian Federation (director — academician of Russian Academy of Science A.Sh. Revishvili), 117997, Moscow, Bolshaya Serpuhovskaya street, 27;
[2]State budget institution of health of Moscow city «Scientific-practical clinical center of diagnostics and telemedical technologies under Ministry of Health of Moscow», 109029, Moscow, Srednyaya Kalitnikovskaya street, 28, building 1

ABSTRACT

Objective — adjustment of diagnostics and management of the surgical treatment of patients with intraductal papillary mucinous tumor of pancreas.

Material and methods. From 2012 to 2018, 45 patients with intraductal papillary mucinous tumor were observed. During the observation the ultrasound examination, contrast-enhanced computed tomography and magnetic resonance tomography with contrast were used. In 29 cases radical surgery was performed, nonradical in 1 case; case follow-up is chosen for 15 patients.

Results. Intraductal papillary mucinous tumor was diagnosed and the definition of the type of tumor was made on the base of 2 types of imaging methods. Intraductal papillary mucinous tumor type 1 was founded in 5 (11%), whereas intraductal papillary mucinous tumor type 2 was founded in 20 (44,5%) and intraductal papillary mucinous tumor type 3 was observed in 20 (44,5%) cases. Intraductal papillary mucinous tumor associated with carcinoma was observed in 16 cases. Pancreaticoduodenal resection was performed in 20, distal exsection of pancreas was performed in 4 cases (2 in open manner access, 2 in robot-assisted manner), pancreatic head resection was performed in 3 cases (1 in open manner access, 2 in laparoscopic access) and in 2 cases the duodenopancreatectomy was performed.

Explorative laparotomy was performed in case of intraductal papillary mucinous tumor type 2 associated with mucilaginous carcinoma and miliary metastasis in the liver. Early postoperative complications were observed in 5 cases (16, 6%): biliary fistula (n=2), postoperative wound infection (n=2), arrosive hemorrhage type B in ISGPS (n=1, was treated in an X-ray endovascular manner). Case follow-up was chosen in 15 cases of intraductal papillary mucinous tumor over the course of 6 to 74 months and disease progression was not observed.

Conclusions. Intraductal papillary mucinous tumor is a condition associated with high risk of malignant change and demands early disease detection. The treatment should be provided in medical centers that specialize in the pancreas deceases, where a full patient examination as well as a clear-eyed understanding of diagnostic information with the execution of desirable type of surgical intervention with the guaranty of achievement R0 condition can be offered.

Keywords: intraductal papillary mucinous tumor, intraductal papillary mucinous carcinoma, pancreas.

INFORMATION ABOUT THE AUTHORS:

Kriger A.G. — https://orcid.org/0000-0002-4567-8312
Karmazanovskiy G.G. — https://orcid.org/0000-0002-9357-0998
Panteleev V.I. — https://orcid.org/0000-0002-1575-1267; e-mail: vpantel@mail.ru
Gorin D.S. — https://orcid.org/0000-0002-6452-4458
Vetsheva N.N. — https://orcid.org/0000-0001-8727-4320
Berelavichus S.V. — https://orcid.org/0000-0001-8727-6111
Kaldarov A.R. — https://orcid.org/0000-0002-4486-4594
Glotov A.V. — https://orcid.org/0000-0002-6904-9318
Corresponding author: Panteleev V.I. — e-mail: vpantel@mail.ru

TO CITE THIS ARTICLE:

Kriger AG, Karmazanovskiy GG, Panteleev VI, Gorin DS, Vetsheva NN, Berelavichus SV, Kaldarov AR, Glotov AV. Diagnostic and treatment of the intraductal papillary mucinous tumor of pancreas. *Pirogov Russian Journal of Surgery = Khirurgiya. Zhurnal im. N.I. Pirogova*. 2020;01:14-24. (In Russ.). https://doi.org/10.17116/hirurgia202001114

Introduction

Intraductal papillary mucinous tumor — borderline cacoethic epithelial tumor that is formed in the Wirsung canal and/or in its lateral branches out of the mucin-producing cells [1].

Incidence rate of the intraductal papillary mucinous tumor is higher for male population and ranges from 0.31 to 4.35 per 100000 people [2]. Mean patient's age at diagnosis was 64 years old [2].

Depending on the site in the Wirsung canal we can point out 3 types of intraductal papillary mucinous tu-

mors: type 1 — the whole or only a part of the Wirsung canal is affected; type 2 — the side branches of the Wirsung canal are affected; type 3 — comprises the combination of first two types. In the pancreas there can be also seen several independent intraductal papillary mucinous tumors (a multicentric growth). [3].

Diagnostics of the intraductal papillary mucinous tumor is hampered due to external reasons such as poverty of morbidities and variety of X-ray manifestations. In spite of the growth of publications devoted to the intraductal papillary mucinous tumors in the latest time, awareness and doctor's skills of interpretation of X-ray images are lacking. On the one hand, gastroenterologists and general surgeons in case of such patients give wrong interpretation. They name chronic pancreatitis instead of the intraductal papillary mucinous tumor that leads to delayed curative therapy. On the other hand, it is not a rare occurrence when the given diagnosis is correct, but the indications for surgical treatment and extent of operation are set too high. We had patients with the intraductal papillary mucinous tumor of collateral canals, who were offered a duodenopancreatectomy as a method of treatment. Currently existing alarm situation with the diagnostics and treatment of the intraductal papillary mucinous tumor demands an awareness from wide range of doctors regarding this problem.

The department of radiological diagnostics and abdominal surgery of the Federal State Budget Institution «National Medical Research Center of Surgery named after A.V. Vishnevsky» has been persistently working on optimization of the diagnostics and treatment of the pancreas tumors including the intraductal papillary mucinous tumor. In current message, we are giving the results of the work of the abovementioned departments of the Center concerning intraductal papillary mucinous tumors.

Methods

In the department of abdominal surgery from 2012 to 2018, 45 patients with intraductal papillary mucinous tumor were observed. 33 (73%) were females, 12 (27%) were males. Mean age was 61.2 years. On presentation to the Center, the clinical manifestations of the decease were appraised together with the existing concomitant diseases. Patient examination was done in the complex manner and included: examination of the general blood test as well as the blood chemistry value; sonography and endoscopic ultrasound of pancreas, multispiral computed tomography of abdominal organs with intravenous contrast agent administration, magnetic resonance tomography with cholangiopancreatography and esophagogastroduodenoscopy. Multispiral computed tomography was a dominant way of observation, which in 14 cases was grouped with the magnetic resonance tomography and magnetic resonance cholangiopancreatography, for 9 patients the diffusion-weighted images were available (in 1 case there was no chart of the estimated diffusion coefficient). All imaging examinations were done in accordance with the protocols that are approved in the Center [4].

Preoperative diagnosis was based on the results of minimum 2 radiological method of diagnostics, which later in the postoperative period were squared, with the data of the post mortem examination.

30 patient underwent a surgical treatment. 29 patients (96,6%) underwent a radical surgery; explorative operation was used in 1 case (3,4%). To ensure good hemostasis in technically challenging conditions we used middle-large green clip-applier and hemostatic titanium clips of SLS standard (Peters Surgical, France).

All patients underwent an urgent histological test of the resection margin of pancreas to determine the atypic cells, the dysplasia rate of epithelium and the quantity of the functional acinuses of pancreas (we measured the area taken by acinuses in the full section of the resection margin).

Routine histologic examination of surgical material was done in accordance with the standard Center procedure that is based on the guidelines of the College of American Pathologists (CAP) [5].

Case follow-up is done in 15 cases, among which 12 are intraductal papillary mucinous tumor type 2 and 3 are intraductal papillary mucinous tumor type 3. Refusal of surgical intervention in case of intraductal papillary mucinous tumor type 3 are associated with the severe form of myasthenia in 1 case; refusal of surgical treatment from 75 years old patient (a retired surgeon), who is sure that he would die under the knife because of the concurrent conditions; the advisability of the surgery in third case is questioned because of small size of the tumor with the «soft», as reported by the MSCT data, pancreas. Follow-up period varies from 3 to 70 months (median is 15 months).

Long-term results were possible to evaluate for 19 operated patients. Follow-up period varied from 3 to 70 months (median is 15 months).

Results

Evaluation of the clinical presentations of intraductal papillary mucinous tumor showed that the presence of pain in epigastric region was seen in 25 (55%) of cases and, as a rule, was associated with tumor type 1 and 3. Character of pain varied from intermittent episodes to gnawing pain related or not related with the food intake. In3 cases the pain intensity reached 7-8 points on visual analog score and demanded chronic administration of the non-steroidal anti-inflammatory drugs. General weakness developed in 8 cases (18%), where 6 (13%) showed significant loss of flesh. Obstructive jaundice was seen in 3 (6,6%) cases.

Duration of a disease in case of the operated patients lasted for a median of 30 months, ranging from 1 month to 19 years. Among these patients 7 were continually admitted to the medical and surgical hospitals where they were given the treatment for chronic pancreatitis, wherein in 2 cases the percutaneous drainage of the cyst cavity

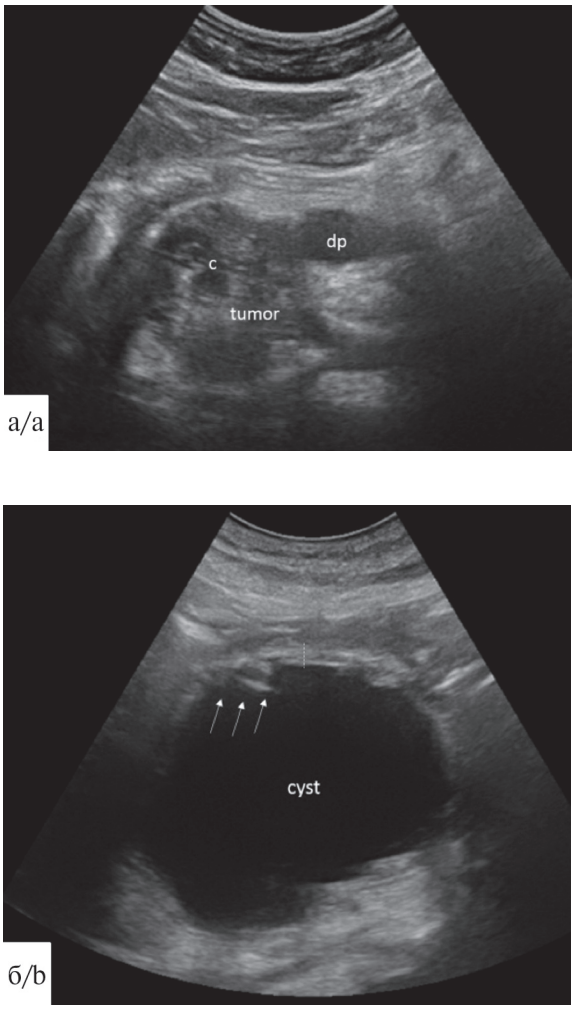

Fig. 1. Ultrasound image of the intraductal papillary mucinous tumor.

a — tumor of the pancreas head with cystic component (c), in the pancreas body the widening of the Wirsung canal (dp); b — cyst formation (cyst) inside the pancreas head with the thick walls (pointed by the diotted lines) and mural overgrowth (pointed by arrows) erroneously diagnosed as mucinous cystadenoma.

of the tumor was done, in 1 case the tumor was anastomosed with the jejunum; in regard to the obstructive jaundice in 2 cases percutaneous transhepatic biliary drainage (PTBD) was used and 1 case cholecystostomy was chosen as a treatment.

Total absence of clinical symptomatology was found in 15 non-operated and in 5 operated patients with intraductal papillary mucinous tumor type 1 and 3. In these cases, the diagnosis was determined with the routine radio examination.

Objective evaluation of the desease duration in case of the non-operated patients was handicapped by the lack of clinical manifestations. In such cases the reference point was the time of detection of the intraductal papillary mucinous tumor during the radio examination; as a result the average figure was estimated as 16,5 months.

On presentation to the National Medical Research Center of Surgery named after A.V. Vishnevsky" all patients received additional examinations. According to the data from the lab tests, no specific deviances were detected.

Ultrasound investigation of abdominal cavity before the operation was done in 14 cases and helped to discover the pancreas masses in 12 (85, 7%) cases. The presence of the intraductal papillary mucinous tumor was suspected in 5 out of 12 cases, where standard ultrasound characteristics of this tumor were observed: cystous or cystous-solid structure with the presence of iso— or hypoechoic soft-tissue component along with the expansion of the Wirsung canal for a median of 1, 0 sm (min — 0,6 sm, max — 1,6 sm) and thickening of its walls (**Fig. 1A**).

Fully cystous tumor structure without apparent expansion of the Wirsung canal in 3 out 12 cases forbade distinguishing the intraductal papillary mucinous tumor from other cystous masses (**Fig. 1B**).

In 4 out of 12 assessments, hypoechoic masses had mainly solid structure. That demanded differential exclusion from adenocarcinoma and neuroendocrine tumor.

The presence of the detectable diffuse changes in parenchyma with the widening of the Wirsung canal in 2 cases was erroneous diagnosed as the sign of the chronic pancreatitis.

Indications of the malignification in the form of the presence of the solid component with extension into peripancreatic mass and on great vessels as well as regional lymphadenopathy were founded in 5 cases (**Fig. 2**).

Endo-ultrasound investigation was done for 9 patients with the aim of the differential exclusion of different cystic tumors and specification of resectability in case of carcinoma.

Clinical manifestations of intraductal papillary mucinous tumor were: the widening of the Wirsung canal, hy-

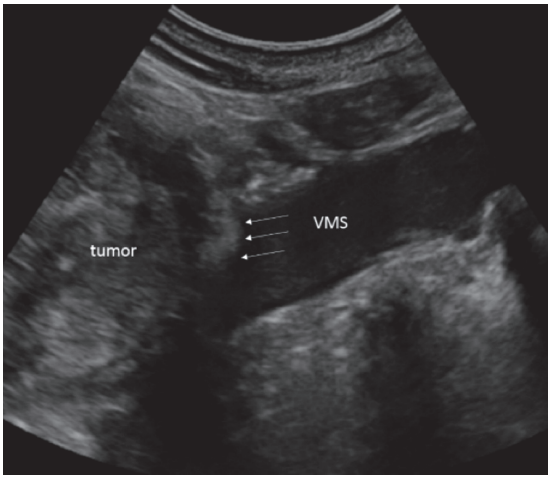

Fig. 2. Ultrasound image of the intraductal papillary mucinous tumor associated with carcinoma.

Cystic-solid formation (tumor) with invasion of the superior mesenteric vein (VMS) wall (pointed by the arrows).

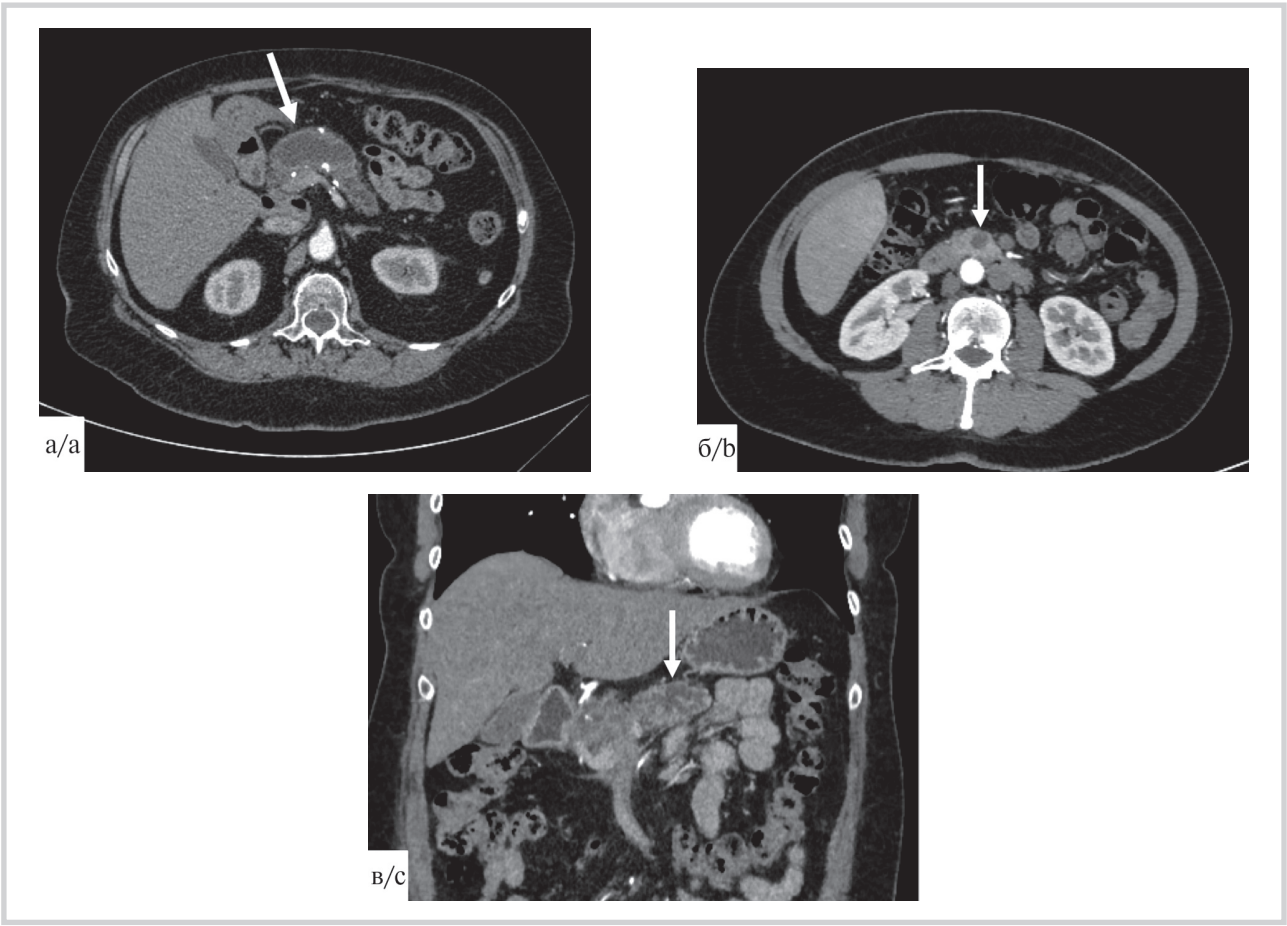

Fig. 3. Multispiral computed tomography, arterial phase.

a — intraductal papillary mucinous tumor type 1 axial section; b — intraductal papillary mucinous tumor type axial section; c - intraductal papillary mucinous tumor type 3 coronal slice.

poechoic thickening of its walls, intramural nodes or mural papillary projections and presence of pancreas atrophy. In first case, at suspicion on presence of intraductal papillary mucinous tumor 2 type a thin needle biopsy was performed. At the time of cytological examination of the punctate the presence of the atypical cells was not detected, response to mucin was positive, amylase — 190 Units; CEA (carcinoembryonic antigen — 2105 ng/ml, CA 19-9 (carbohydrate antigen 19-9) — 109855 ng/ml.

Multispiral computed tomography was done in 29 cases and helped readily make a diagnosis intraductal papillary mucinous tumor in 26 cases on foot of presence of singular or multiple cysts, presence of solid component inside cysts, diffuse or segmental widening of the Wirsung canal (**Fig. 3**).

Manifestations of the malignant change of tumor were founded in 15 cases. They included the widening of Wirsung canal greater than 10 mm, the size of cyst cavity more than 40 mm, regional lymphadenopathy and presence of solid component that accumulates the contrast agent.

Intraductal papillary mucinous tumor associated with the invasive carcinoma featured in two forms: tumors with intraluminal mural enlargement that fast accumulated contrast agent and carcinomas with predominantly invasive growth outside of the pancreas ductal system.

Invasive intraductal papillary mucinous tumors type 3 sited in head of pancreas were prone to germinate the duodenum (**Fig. 4**).

The onset of hypodense zone during arterial and venous phase of investigative procedure proved the malignancy of the tumor. Further morphological examination revealed the presence of the intraductal papillary mucinous tumors associated with adenocarcinoma in these patients.

In 9 out of 39 patients, there was no clear picture in regards to the presence of the intraductal papillary mucinous tumor from the multispiral computed tomography data. Diagnosis differentiated with the serous or mucinous cystadenomas, postnecrotic cysts. For the purpose of differential exclusion, the magnetic resonance tomography or endoultrasound was used and allowed to confirm the presence of the intraductal papillary mucinous tumor (**Fig. 5**).

Diagnostic pitfalls during the multispiral computed tomography examination were done in 4 cases of the intraductal papillary mucinous tumor. The diagnostic error was: common bile duct cyst in 1 case, chronic pancreati-

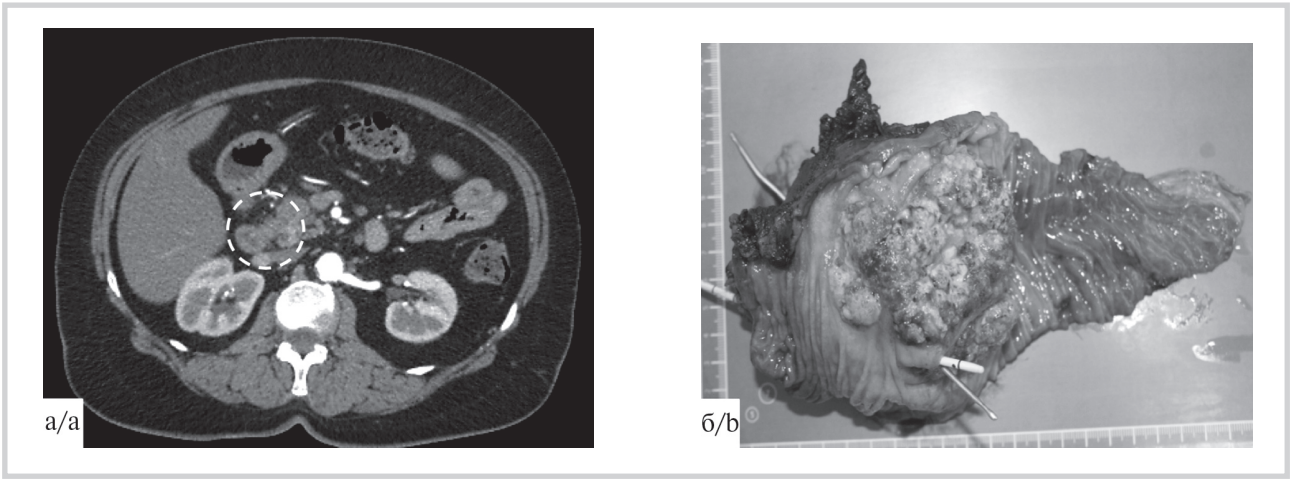

Fig. 4. Intraductal papillary mucinous tumor associated with ductal adenocarcinoma with the invasion of the duodenum.
a — multispiral computed tomography, arterial phase, axial section — malignant invasion highlighted by the circle; b — extracted organ complex during the pancreaticoduodenal resection – invasion of carcinoma into the duodenum. .

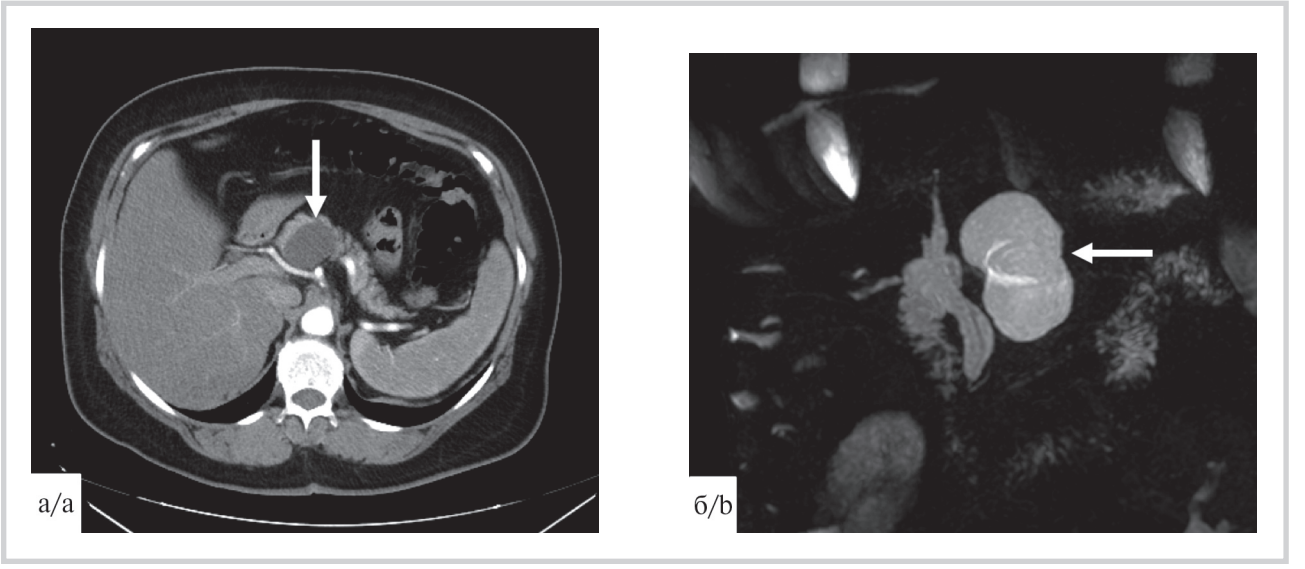

Fig. 5. A. multispiral computed tomography, arterial phase, axial section. Cystic tumor of the pancreas head. Б. Same patient, Magnetic resonance cholangiopancreatography — standard form of the intraductal papillary mucinous tumor type 2.

tis in 1 case, gastrointestinal stromal tumor in 1 case and neuroendocrine tumour in 1 case (**Fig. 6**).

Magnetic resonance tomography with magnetic resonance cholangiopancreatography, which was chosen for 26 patients, allowed determining a diagnosis in 21 cases. Tumors were presented in forms of solitary or multiply cyst cavities, round-shaped with homogenous content. Magnetic resonance cholangiopancreatography allowed to evaluate the widening of the Wirsung canal and its branches, their outlines along the entire length (**Fig. 7**). In 5 examinations, the final diagnosis was not determined and needed further diagnostic research.

Esophagogastroduodenoscopy as an additional examination method for 11 patients. In 3 cases malignant invasion into the duodendum wall was discovered; during biopsy investigation the sites of the invasive growth of adenocarcinoma were found. 1 patient had a sinus opening located on the back wall of the duodenal bulb that oozed out mucoid fluid with the trace of pus.

According to the data provided by the comprehensive radio examination of operated and non-operated patients, tumor site was mostly seen on the head of pancreas — 27 patients (60%). In 4 cases the tumor was located not only on the head but also on the body of pancreas (9%); on body and tail of pancreas in 4 cases (9%); only on the body of pancreas in 6 cases (13%); on tail of pancreas in 4 cases (9%).

As a result of the comprehensive radio examination the intraductal papillary mucinous tumor type 1 was diagnosed in 5 cases (11%), type 2 was diagnosed in 20 cas-

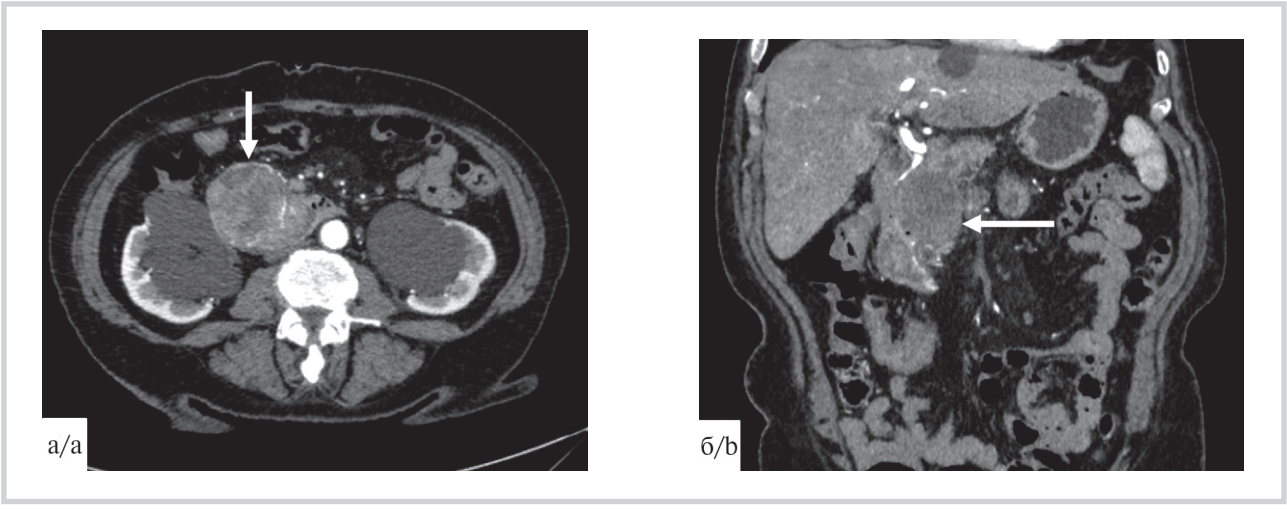

Fig. 6. Multispiral computed tomography, arterial phase, axial section (А) and coronal slice (Б). Tumor (arrow) was described as the gastrointestinal tumor of the duodenum. Postoperative diagnosis: intraductal papillary mucinous tumor type 1.

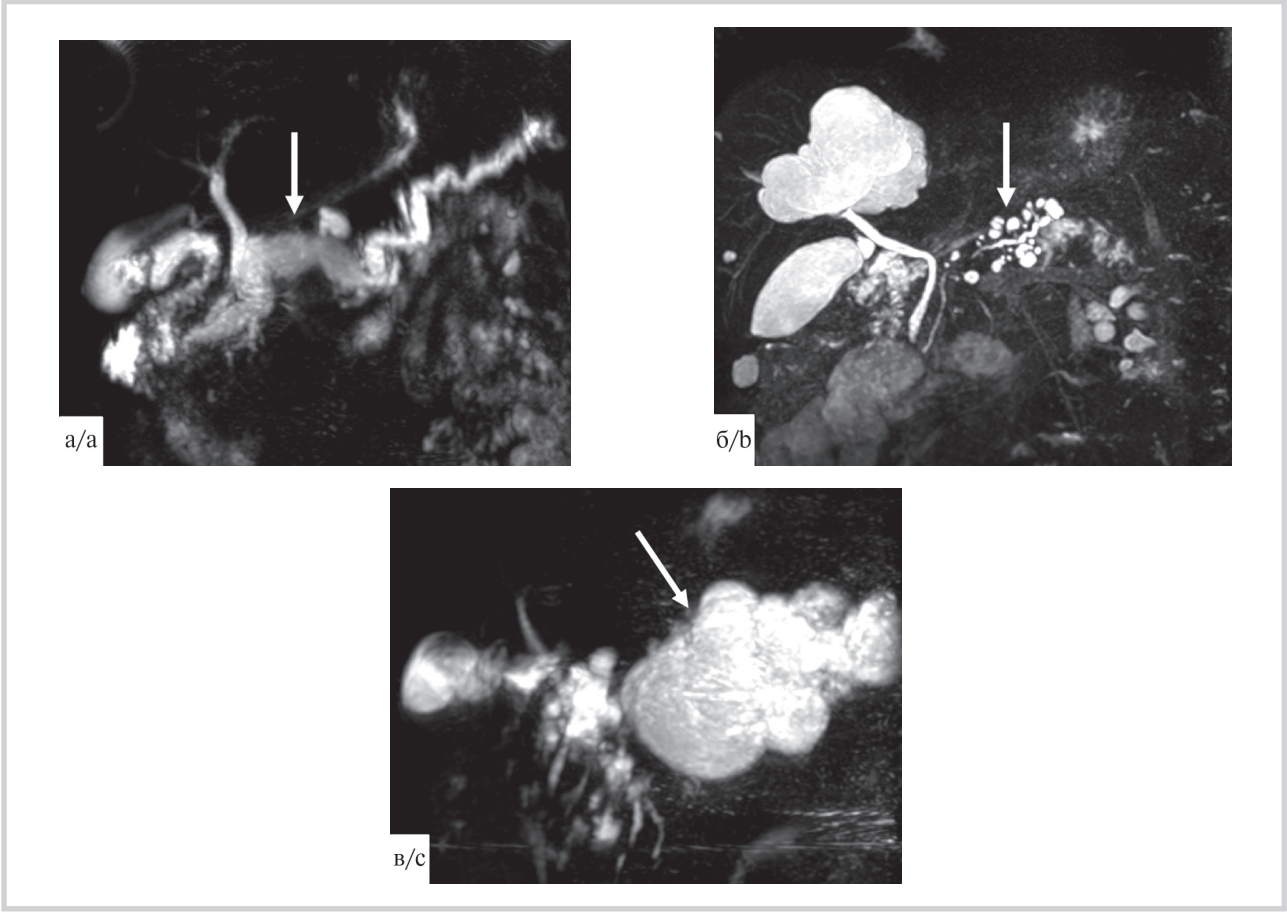

Fig. 7. Magnetic resonance cholangiopancreatography: А. intraductal papillary mucinous tumor type 1 of the pancreas head; Б. intraductal papillary mucinous tumor type 2 of the body and tail of the pancreas; Cystoadenoma S2, 4 of liver. В. Intraductal papillary mucinous tumor type 3.

es (44,5%), type 3 was diagnosed in 20 cases (44,5%). Mean tumor size for operated patients was 47,4 mm (from 13 mm to 140 mm). The widening of the Wirsung canal reached 17 mm (mean value — 6,5 mm).

Surgical treatment was given to 30 patients **(Table)**. When the tumor site was in the head of pancreas and there were traces of malignant changes according to the radiological methods of examination and intraoperative assess-

Demographics and types of surgical interventions

Types of the intraductal papillary mucinous tumor	Gender		Mean age	Surgical interventions					
	M	F		Pancreaticoduodenal resection	Distal resection of pancreas	Resection of the pancreas head	Total duodenopancreatectomy with splenectomy	Explorative laparatomy	Carcinoma
Type 1	2	3	62,6	2	2	—	1	—	4
Type 2	2	5	63,3	2	2	3	—	1	2
Type 3	6	12	65,3	16	—	—	1	—	10
Total	10	20	63,7	20	4	3	2	1	16

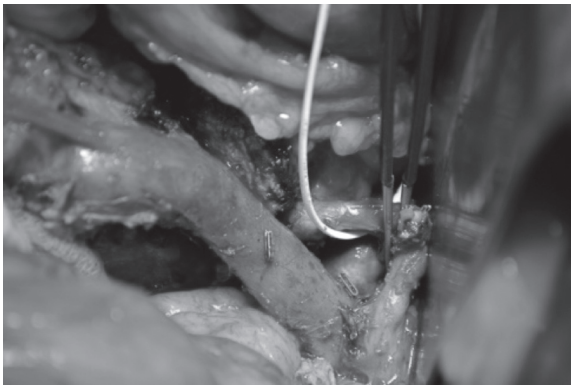

Fig. 8. Stump of the gastroduodenal artery with applied clips; clipped phleboid small flows of portal and superior mesenteric veins.

ment, the operation of choice was a pancreaticoduodenal resection used in 20 cases (pylorosparing type of operation — 18, gastropancreaticoduodenal resection — 2). When the tumor site was in the body and tail of pancreas, corporocaudal resection of pancreas through open (1) or robot-assisted (3) accesses.

Pancreatic head resection in case of intraductal papillary mucinous tumor type 2 with more than 4 sm diameter and presence of clinical symptomatology was done in 3 cases in open or laparoscopic manner. At this point, we stepped away from this type of surgical treatment.

Duodenumpancreatectomy with splenectomy was needed in 2 cases of intraductal papillary mucinous tumor associated with carcinoma that affected the whole pancreas. The use of hemostatic clips for vascular treatment allowed reliable hemostasis as well as inside the wound cavity and preventing the detachment of the minor branches of portal and superior mesenteric veins.

Clipping of the branches of the hepatic and superior mesenteric arteries provided not only good hemostasis but also an ideal navigation during postoperative dynamic radiological assessments (**Fig. 8**).

Explorative laparotomy was chosen in 1 case of the intraductal papillary mucinous tumor type 2 where miliary metastasis in liver were revealed intraoperatively (urgent histological test of metastasis revealed the presence of mucoid adenocarcinoma).

Early postoperative complications were present in 5 cases (16,6%): biliary fistula — 2, postoperative wound infection — 2, arrosive hemorrhage type B based on ISGPS scale was present in 1 case (was suppressed in X-ray endovascular manner).

Late complications were founded in 2 cases (6,7%). Stricture at the site of hepaticojejunostomy was founded in 1 case (eliminated due to external-internal drain).

Corrosive stricture at the site of pancreaticojejunostomy 5 years after the pancreaticoduodenal resection was formed in 1 case (resection of pancreas stump with the reanastomosis was chosen as a treatment).

Based on the results of the histologic examination the intraductal papillary mucinous tumor type 1 with low degree of epithelial displasy was diagnosed in 16 cases, wherein 4 cases the tumor was associated with ductal adenocarcinoma. In 13 cases the intraductal papillary mucinous tumor with high degree of epithelial displasy, in 7 cases it was associated with ductal adenocarcinoma and in 4 with mucilaginous carcinoma. Histologic examination of the hepatic lesion during explorative laparotomy revealed the presence of metastasis of mucilaginous carcinoma.

Long-term results were possible to trace in 18 out of 30 operated patients, where intraductal papillary mucinous tumor associated with ductal adenocarcinoma were discovered in 7. Follow-up period ranged from 3 to 70 months. By the time of the check-up examination, 17 patients were alive. Patients regularly underwent a computed tomography (no data suggestive of tumor recurrence). Complaints were presented in 6 cases. Altered defecation patterns were present in 4 cases; 1 patient after duodenopancreatectomy complained of the need of the forced enzyme substitution and insulin therapy (glucose levels ranged from 9 to 12 mmol/L. Abdominal pains after pancreas head resection for the intraductal papillary mucinous tumor type 2 were present in 1 case. Conservative treatment had no effect; therefore, spleen-sparing extirpation of the pancreas stump was performed, resulting in the pain suppression.

Among 7 patients with carcinoma, 5 received a multiagent chemotherapy; number of chemotherapy courses rated from 1 to 6 (median — 4).

One patient with intraductal papillary mucinous tumor type 3 assosiated with the ductal adenocarcinoma died 5 months after pancreaticoduodenal resection and 1 course of multiagent chemotherapy.

Case follow-up is done for 12 non-operated cases of the intraductal papillary mucinous tumor type 2 and had no clinical signs of the decease. The tumor size ranged from 5 to 53 mm, median size was 13,7 mm. Two of these patients in other medical settings were offered a surgical treatment as much as pancreatoduodenectomy. During the follow-up period (from 6 to 74 months) there were no clinical signs of the tumor; during control multispiral computed tomography examination/ magnetic resonance tomography there were no traces of the tumor growth and no papillary projections or solid components were detected. The situation follow-up will be continued. Forced follow-up for three patients with intraductal papillary mucinous tumor type 3 over the course of 8, 10 and 48 months showed no evidences of the disease progression.

Discussion

In the past decade the number of patients with the intraductal papillary mucinous tumor has significantly grown by the aid of the onrush of technology in the radiological methods of diagnostics and their wide use in the outpatient setting [6]. During the magnetic resonance examination of the abdominal cavity organs as a routine procedure, in 15% of patients the cyst formations of pancreas were founded. These cyst formations at the 82% probability were the intraductal papillary mucinous tumors [7].

Risk of the tumor malignant change differs. The probability of the malignant change is higher in case of tumor type 1 and 3 and amounts to 48% and 42% respectively [8]. In the presence of several intraductal papillary mucinous tumors type 1 the risk for carcinoma development goes as high as 90% [9]. In case of intraductal papillary mucinous tumors type 2 the malignant change risk amounts to 11% [8].

According to the classification of gastro-intestinal cancer of World Health Organization of fifth revision (2019), we can distinguish intraductal papillary mucinous tumors with epithelium dysplasia of low and high-grade and also intraductal papillary mucinous tumors associated with invasive carcinoma. Invasive carcinoma can be presented as ductal (tubular) adenocarcinoma and as mucoid adenocarcinoma. Previously separated oncocytic type of the intraductal papillary mucinous tumors, according to the new classification of World Health Organozation, was inserted into a separate histologic type of tumor known as «pancreatic intraductal oncocytic papillary tumor» [1].

Major challenge during histologic examination of the extirpated gross specimen involves the searching of the possible sites of the invasive carcinoma. Frequently the tumor of the pancreas head can be presented in the form of multiply interlocked dilated ducts that form a tumor node of large size. Among other things, the invasive component can be presented in the form of small-size lesion. Grossly invasive component can be presented as a dense tissue site positioned closely to cystic-dilated ducts. Only careful histologic examination with the drawing of a bulk of tissue fragments suspicious of invasion allows an adequate assessment of the presence of the invasive carcinoma.

If there is no trace of the invasive component and high degree of the epithelial displasy only, the tumor will be described as Tis. In case of the presence of the associated carcinoma, the tumors are described on the base of the size of the invasive component. Based on the classification TNM 8th Edition (AJCC/UICC, 2018), for the invasive component with size 2 sm or less (pT1) there are substages pT1a ($\leqslant$ 0,5 sm), pT1b ($>$ 0,5 sm and less 1 sm) and pT1c ($>$ 1-2 sm) [1].

One person can have an intraductal papillary mucinous tumor and a ductal adenocarcinoma of pancreas at the same time. If an invasive carcinoma is present close to the intraductal papillary mucinous tumor, then it will be interpreted as an intraductal papillary mucinous tumor associated with the invasive carcinoma. If the invasive carcinoma site is seen further from the intraductal papillary mucinous tumor, then it will interpreted as two separate diseases [1].

In our practice 11 patients were diagnosed with intraductal papillary mucinous tumor associated the ductal adenocarcinoma. In 2 cases it was intraductal papillary mucinous tumor type 1, in 9 cases it was type 3. Mucilaginous carcinoma was founded in 5 patients: type 1 — 2, type 2 — 2, type 3 — 1. Thus, in our study, the highest incidence of malignant change was founded in case of intraductal papillary mucinous tumor type 3 — out of 18 patients, 10 had a carcinoma (55, 5%).

Timely diagnostics and balanced surgical approach are critical to the successful treatment of patients with the intraductal papillary mucinous tumor.

The crucial role in tumor detection play the radiological methods of examination. It must be admitted that it is not uncommon that diagnostics of the intraductal papillary mucinous tumors present significant difficulties. We came to conclusion that there are objective factors that can complicate the assessment of the right diagnosis. For example, the presence of mucin lowered the informative value of both contrast enhancement and diffusion-weighted MR images. Necrotic changes of solid part of tumor formed cyst cavities, fistulas that complicated the diagnostics as such picture can be seen during other pancreas diseases.

Detection of the invasive types of tumor is the key part of the radiodiagnostics. In our research during multispiral computed tomography for invasive carcinoma prevailed the presence of the extracorporal component. Invasive carcinomas type 3 of pancreas head were prone to invasion into duodenum. In this case, one must bear in mind the fact that similar X-ray pattern can be observed in patients with chronic pancreatitis complicated by cystic-inflammatory conversion of duodenum. Invasive intraductal papillary mucinous tumor type 2 can be similar to subacute «bulbous» pancreatitis wherein gangliac cavities are also present. The presence of massive mural masses that

actively accumulated contrast agents during dynamic scanning (both computer tomography and magnetic resonance tomography), facilitates the diagnostics of the invasive carcinoma. Magnetic resonance tomography with Magnetic resonance cholangiopancreatography clearly demonstrates the connection of cysts with the pancreas ductal system. Calcification can be presented in 20% cases in any type of intraductal papillary mucinous tumor, wherein the risk of malignant changes in large mineralization site is the highest [12]. Sometimes intraductal papillary mucinous tumor can be presented as a solid formation due to massive proliferation of tumor tissue [12].

We are convinced that the diagnosis of intraductal papillary mucinous tumor cannot be established on the basis of one diagnostic technique only. Only the use of minimum two radiological methods of diagnostics allows to be sure of disease nature and plan a treatment strategy. The verification of diagnosis is feasible because of needle biopsy performed under endoultrasound guidance, aspiration of Wirsung canal content with the examination of its celluar composition [13].

Modern strategy of surgical treatment of intraductal papillary mucinous tumor was given in the guidelines of International Pancreatic Association of 2017 and European Position Paper of 2018 [13, 14]. Couched in these files invariable and relative indications for surgery were similar.

Invariable indications are: the presence of atypical cells discovered during cytologic screening of aspirate from tumor content or from biopsy material taken during endoultrasound of solid component; obstructive jaundice caused by tumor; presence in the cyst range of the solid component equal to or greater than 5 mm that accumulates contrast agent; the widening of the Wirsung canal to 10 mm and more.

Relative indications are: the increase in tumor diameter of more than 5 mm per year, the rise of level of serumal CA 19-9 to more than 37 U/ml; diameter of Wirsung canal 5 — 9,9 mm; the diameter of cyst component equal to or greater than 40 mm; new onset of diabetes mellitus or acute pancreatitis caused by the tumor; intramural growths less than 5 mm that accumulate contrast agent.

Del Chiaro et al in 2018 published their retrospective analysis of 901 cases of surgical treatment of intraductal papillary mucinous tumors [15]. According to the obtained data, the widening of the Wirsung canal was the greatest risk factor for development of high-degree dysplasia or invasive carcinoma. Masaki et al (2019) explored the risk factors for malignant changes for 29 patients with intraductal papillary mucinous tumor type 1 and came to conclusion that the widening of the Wirsung canal to more than 5 mm and non-gastric histologic types are statistically significant factors of tumor malignant change [16]. Our data support this claim. Out of 17 patients, who underwent a surgery, with the widening of the Wirsung canal to more than 5 mm, 11 had a high-degree dysplasia and/or carcinoma.

Perez-Cuadrado-Robles et al (2019) conducted a retrospective analysis of 60 patients, who underwent a surgery in the presence of relative indications [17]. In presence of 1 indication for surgery, the high-degree dysplasia or invasive carcinoma were detected in 37, 1% of cases, while in presence of 2 and more relative indications these indicators were 44%.

In presence of invariable indications for surgery, the strategy of surgical treatment of the intraductal papillary mucinous tumor is not divisive. The treatment of patients with relative indications is not so unambiguous. In accordance with the latest European guidelines, in these patients the decision of surgical treatment should be made considering the comorbidities [13]. Patients without severe comorbidities and with 1 or more relative indications should be offered a surgical treatment. In presence of severe comorbidities the possibility for surgical treatment should be considered only in presence of 2 or more relative indications.

The volume of surgical intervention is determined by the site of tumor lesion of pancreas ductal system and results of urgent histological test. Regardless of operation type, it is necessary to aim for resection R0 that requires an urgent histological test of the section of the extracted preparation. Absence of ducts with the high-degree of epithelial dysplasia at the edges of the excision enables to go with the organ preservation surgery while the presence of these changes require the expansion of the volume of surgical intervention up to the pancreatectomy. Thus, two of our patients underwent a duodenopancreatectomy with splenectomy in presence of overall pancreas affection.

Patients, who according to histological examination have been diagnosed with intraductal papillary mucinous tumor with high-degree dysplasia or associated carcinoma, are subjected to oncologist observation with decision in the matter of chemotherapy arranging and regular dynamic control with magnetic resonance examination and/or multispiral computed tomography. In the presence of intraductal papillary mucinous tumor with low-degree dysplasia, patients are subjected to take regular examination every 6 months during first year after surgery, afterwards annually [13]. Studies showed that recurrence of intraductal papillary mucinous tumor is possible 5-10 years after exsection [18]. Intraductal papillary mucinous tumor with low-degree dysplasia has a 5, 4-10% risk of recurrence, while Intraductal papillary mucinous tumor with high-degree of dysplasia or with invasive carcinoma has a 50% risk of recurrence [18].

Apart from the fact that the intraductal papillary mucinous tumor is a contributory cause of pancreas cancer development, this type of tumor increases the risk of development of malignant tumors of other localization. Thus, in the study of Huang et al (2019) was presented a retrospective analysis of 2850 patients with intraductal papillary mucinous tumor from 2000 until 2015 [19]. Among them 104 (3, 65%) during the follow-up period had primary tumors in other organs (most likely that the tumor will be localized in jejunum, oropharynx, eye socket, urinary bladder).

Authors insist that risk of tumor growth in the setting of the intraductal papillary mucinous tumor is higher than in the population. In our study in 1 patient two years after pancreaticoduodenal resection concerning the intraductal papillary mucinous tumor type 3 of pancreas head, a peripheral cancer of the superior lobe of left lung was diagnosed (video-assisted segmentectomy was performed S4+5).

Conclusion

Despite of the increased availability of the radiological methods of examination, the diagnostics of the intraductal papillary mucinous tumor is still complicated. Due to the high risk of the tumor malignant change in type 1 and type 3, the timely establishing of the right diagnosis and estimation of the further disease management play an essential role here. The treatment should be done in the medical centers that specialize in the treatment of the pancreas diseases, where the possibility of the whole examination of patients, clear and reliable assessment of the diagnostic information can be given and further execution of the desirable type of surgical intervention which provides afterwards state R0. The volume of surgical intervention in patients with intraductal papillary mucinous tumor should be reasonable. If it is possible to perform an organ preservation surgery without violation of the oncologic demands, the preference shall be given to this method, wherein the surgical access (open, laparoscopic or robot-assisted) is immaterial.

ЛИТЕРАТУРА/REFERENCES

1. Nagtegaal ID, Odze RD, Klimstra D, et al. The 2019 WHO classification of tumours of the digestive system. *Histopathology.* 2019 Aug 21. https://doi.org/10.1111/his.13975
2. Buscarini E, Pezzilli R, Cannizzaro R, et al. Italian consensus guidelines for the diagnostic work-up and follow- up of cystic pancreatic neoplasms. *Dig Liver Dis.* 2014 Jun;46(6):479-493. https://doi.org/ 10.1016/j.dld.2013.12.019
3. Mori Y, Ohtsuka T, Kono H, et al. Management strategy for multifocal branch duct intraductal papillary mucinous neoplasms of the pancreas. *Pancreas.* 2012 Oct;41(7):1008-1012. https://doi.org/10.1097/MPA.0b013e31824b22c6
4. *Диагностика и хирургическое лечение кистозных опухолей поджелудочной железы*. Методическое руководство. Под ред. Кригера А.Г., Кармазановского Г.Г. М. 2019. *Diagnostika i hirurgicheskoe lechenie kistoznyh opuholej podzheludochnoj zhelezy*. Metodicheskoe rukovodstvo. Pod red. Krigera AG, Karmazanovskogo GG. M. 2019. (In Russ.).
5. College of American Pathologists. Protocol for the Examination of Specimens From Patients With Carcinoma of the Pancreas. Version: PancreasExocrine 4.0.0.1 CAP; 2017.
6. Moris M, Bridges MD, Pooley RA, et al. Association between advances in high-resolution cross-section imaging technologies and increase in prevalence of pancreatic cysts from 2005 to 2014. *Clin Gastroenterol Hepatol.* 2016;14:585-593.e3. https://doi.org/10.1016/j.cgh.2015.08.038
7. Cortegoso Valdivia P, Chialà C, Venezia L, et al. Diagnosis and management of intraductal papillary mucinous neoplasms of the pancreas. *Acta Biomed*. 2018 Dec 17;89(9-S):147-152. https://doi.org/10.23750/abm.v89i9-S.7958
8. Crippa S, Fernández-Del Castillo C, Salvia R, et al. Mucin-producing neoplasms of the pancreas: an analysis of distinguishing clinical and epidemiologic characteristics. *Clin Gastroenterol Hepatol*. 2010 Feb;8(2):213-219. https://doi.org/10.1016/j.cgh.2009.10.001
9. Aronsson L, Andersson R, Ansari D. Intraductal papillary mucinous neoplasm of the pancreas — epidemiology, risk factors, diagnosis, and management. *Scand J Gastroenterol.* 2017 Aug;52(8):803-815. https://doi.org/10.1080/00365521.2017.1318948
10. Mino-Kenudson M, Fernández-del Castillo C, Baba Y, et al. Prognosis of invasive intraductal papillary mucinous neoplasm depends on histological and precursor epithelial subtypes. *Gut.* 2011 Dec;60(12):1712-1720. https://doi.org/10.1136/gut.2010.232272
11. Basturk O, Hong SM, Wood LD, et al. A Revised Classification System and Recommendations From the Baltimore Consensus Meeting for Neoplastic Precursor Lesions in the Pancreas. *Am J Surg Pathol.* 2015 Dec;39(12):1730-1741. https://doi.org/10.1097/PAS.0000000000000533
12. Machado NO, Al Qadhi H, Al Wahibi K. Intraductal Papillary Mucinous Neoplasm of Pancreas. *N Am J Med Sci*. 2015 May;7(5):160-175. https://doi.org/10.4103/1947-2714.157477
13. Del Chiaro M, Besselink MG, Scholten L, et al. European evidence-based guidelines on pancreatic cystic neoplasms. *Gut.* 2018 May;67(5):789-804. https://doi.org/10.1136/gutjnl-2018-316027
14. Tanaka M, Fernández-Del Castillo C, Kamisawa T, et al. Revisions of international consensus Fukuoka guidelines for the management of IPMN of the pancreas. *Pancreatology*. 2017 Sep-Oct;17(5):738-753. https://doi.org/10.1016/j.pan.2017.07.007
15. Del Chiaro M, Beckman R, Ateeb Z, et al. Main Duct Dilatation Is the Best Predictor of High-grade Dysplasia or Invasion in Intraductal Papillary Mucinous Neoplasms of the Pancreas. *Ann Surg.* 2019 Jan 18. https://doi.org/10.1097/SLA.0000000000003174
16. Masaki Y, Koshita S, Noda Y, et al. Should we regard all main duct type intraductal papillary mucinous neoplasms of the pancreas (MD-IPMN) as an indication of surgery? A retrospective study in 29 patients with MD-IPMN showing mural nodules. *Pancreatology*. 2019 Mar;19(2):352-359. https://doi.org/10.1016/j.pan.2019.01.005
17. Pérez-Cuadrado-Robles E, Uribarri-González L, Borbath I, et al. Risk of advanced lesions in patients with branch-duct IPMN and relative indications for surgery according to European evidence-based guidelines. *Dig Liver Dis.* 2019 Jun;51(6):882-886. https://doi.org/10.1016/j.dld.2018.11.028
18. Kang MJ, Jang JY, Lee KB, et al. Long-term prospective cohort study of patients undergoing pancreatectomy for intraductal papillary mucinous neoplasm of the pancreas: implications for postoperative surveillance. *Ann Surg.* 2014;260:356-363. https://doi.org/ 10.1097/SLA.0000000000000470
19. Huang X, Zhang B, Zhao J, et al. Increased Risk of Second Primary Cancers Following Diagnosis of Malignant Intraductal Papillary Mucinous Neoplasms of the Pancreas: A Population-Based Study. *Front Oncol*. 2019 Jul 9;9:610. https://10.3389/fonc.2019.00610

Поступила 10.10.19
Received 10.10.19
Принята в печать 15.11.19
Accepted 15.11.19